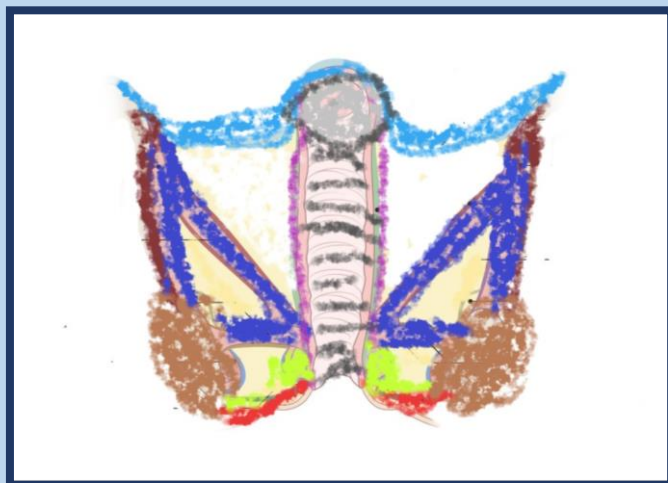




UNIVERSITATEA  
DE MEDICINĂ ȘI FARMACIE  
VICTOR BABEȘ | TIMIȘOARA

**ALINA MARIA ȘIȘU**

# **Human Anatomy - The Perineum -Textbook-**



MANUALE

**Editura „Victor Babeș”  
TIMIȘOARA, 2021**

**Alina Maria Şişu**

Associate Professor, MD,PhD,

Department of Anatomy and Embryology,

English Section, First Year

Victor Babeş University of Medicine and Pharmacy, Timisoara

**Editura „Victor Babeș”**

Piața Eftimie Murgu nr. 2, cam. 316, 300041 Timișoara

Tel./ Fax 0256 495 210

e-mail: [evb@umft.ro](mailto:evb@umft.ro)

[www.umft.ro/editura](http://www.umft.ro/editura)

**Director: Prof. univ. emerit dr. Dan V. Poenaru**

**Referent științific: Conf. univ. dr. med. Liana Dehelean**

**Colecția: MANUALE**

**Indicativ CNCIS: 324**

© 2021 Toate drepturile asupra acestei ediții sunt rezervate.

Reproducerea parțială sau integrală a textului, pe orice suport, fără acordul scris al autorilor este interzisă și se va sancționa conform legilor în vigoare.

**ISBN 978-606-786-235-5**

# Contents

<b>I. THE PELVIC FLOOR .....</b>	<b>5</b>
The Pelvic <i>Fasciae</i> .....	6
The Perineal Muscles.....	10
The Muscles of the Urogenital Region in the Male.....	13
The Muscles of the Urogenital Region in the Female .....	18
<b>II. THE MALE GENITALIA.....</b>	<b>22</b>
The Scrotum .....	22
The <i>Vas Deferens (Ductus deferens)</i> .....	24
The <i>Vesiculæ Seminales</i> .....	24
The Penis ( <i>Penis</i> ) .....	25
<b>III. THE FEMALE GENITALIA .....</b>	<b>35</b>
The External Genital Organs ( <i>Partes Genitales Externæ Muliebres</i> ) <i>Mons pubis (Commissura labiorum anterior; Mons Veneris)</i> .....	35
The External Genital Organs .....	39
The Internal Genital Organs.....	40
<b>IV. THE PERINEUM TOPOGRAPHY .....</b>	<b>42</b>
Ischiorectal Fossa ( <i>Fossa ischiorectalis</i> ) .....	43
<b>V. REFERENCES .....</b>	<b>50</b>

# I. THE PELVIC FLOOR

It is attached to the walls of the lesser pelvis.

It divides the pelvic cavity and the perineum.

The orifices in the pelvic floor are:

- Urogenital hiatus – an orifice situated anteriorly.
- Rectal hiatus – a slit situated in the middle.

In between the urogenital orifice and the anal canal there is a fibrous structure, the perineal body.

The pelvic floor muscles are important in sustaining the abdominal and pelvic organs.

They support the abdominopelvic viscera: urinary bladder, intestines, and uterus.

The muscle fibers act as sphincters in the rectum and urethra.

They are used in urination and defecation.

## **The muscles and *fasciæ* of the pelvis**

The muscles in the pelvis are disposed into two groups:

- The *Obturator internus* and the *Piriformis*.
- The *Levator ani* and the *Coccygeus*.

## **The Pelvic Fasciae**

The pelvic *fasciae* are:

- the *fasciae* of the *Obturator internus*, *Piriformis* muscles, and pelvic diaphragm.
- the fascia of the pelvic organs.

### **The fascia of the *Obturator internus* muscle**

It covers the muscle on its pelvic aspect.

It is anchored to the border of the muscle origin.

Superiorly it is attached to the posterior part of the *linea arcuata*.

It comes in contact with the iliac fascia.

Anteriorly it is attached to the *Obturator internus* muscle.

Posteriorly comes in contact with the obturator vessels and obturator nerve.

The obturator fascia is attached on the sacrotuberous ligament.

Also, comes in contact to the pubic arch.

The internal pudendal vessels and pudendal nerve cross the pelvic surface of the *Obturator internus*.

### **The fascia of the *Piriformis* muscle**

It is attached to anterior part of the sacrum and the sides of the greater sciatic foramen.

The muscle into the gluteal region are also covered by it.

At its sacral attachment it is into relation with the nerves exiting the sacral *foramina*.

The sacral nerves are situated posterior to it.

Here comes in relation with the muscles from the gluteal region.

### **The diaphragmatic part**

It covers the *Levatores ani muscles*.

Its inferior layer is the anal fascia.

It is situated close to the origin of the *Levator ani muscle*.

Inferiorly it continues with the urogenital diaphragm, and the *Sphincter ani internus* muscle fascia.

### **The *Obturator internus* muscle fascia**

It is situated above the *Levator ani* muscle.

It covers the superior surface of the pelvic diaphragm.

The internal part of the pelvic fascia continues above superior the pelvic organs.

In the female, the vagina passes through it.

It travels posterior to the lateral parts of the rectum.

## **The *Levator ani* muscle**

It is a muscle situated on each part of the pelvic cavity.

It is attached to the internal surface of the lateral parts of the lesser pelvis.

It meets the fellow opposite to form the majority of the floor of the pelvic cavity.

It originates from the pubis and from the ischial spine.

It also originates from the obturator fascia.

The *Levator ani* consists of two parts: *Iliococcygeal* and *Pubococcygeal* muscles.

The *Iliococcygeus* muscle originates from the ischial spine and the tendinous arch.

It is inserted to:

- the coccyx,
- anococcygeal *raphé*.

The *Pubococcygeus* muscle originated from the pubis and the obturator fascia.

Coccyx and sacrum serve as attachments.

The fibers circular disposed around the rectum are forming the *Puborectalis* or *Sphincter recti* muscles.

They have origin onto the symphysis pubis and the urogenital diaphragm.

The *Levator ani* muscle is innervated by a filet from the fourth sacral nerv.



## **The Coccygeus muscle**

It is situated posterior to the *Levator ani* muscle.

It has origin from the ischial spine and sacrospinous ligament.

It is inserted in:

- the coccyx ,
- the sacrum, its lower part.

It is accessory of the *Levator ani* and *Piriformis* muscles in closing the pelvis.

The *Levatores ani* muscle is a constrictor of the inferior part of the rectum and vagina.

They act in expulsion of the feces and in parturition.

They assist the forced expiration.

## **The Anal canal (*Pars analis recti*)**

It is the terminal part of the large intestine.

It starts at the level of the tip of the prostate and finishes at the anus.

It forms an angle with the lower part of the rectum.

It has no peritoneal covering.

It is surrounded by the *Sphincter ani internus*.

It is supported by the *Levatores ani*.

It is surrounded at its termination by the *Sphincter ani externus* muscle.

Posterior to it there is a mass of muscular and fibrous fibres, named the **ano coccygeal body**.

In the male, posterior to it there is the membranous structure and bulb of the urethra, and the fascia of the urogenital diaphragm.

In the female it is separated from the vagina by a muscular and fibrous structure, named the **perineal body**.

## ***The Perineal Muscles***

The perineal muscles are limited:

- anteriorly by the pubic arch and the arcuate ligament of the pubis.
- posteriorly by the apex of the coccyx.
- laterally by the inferior *rami* of the pubis and the sacrotuberous ligament.

A line anterior of the ischial tuberosities divides the space into two areas.

The posterior part is known as the **anal region**.

It lodges the termination of the anal canal.

The anterior is the **urogenital region**.

It lodges the external urogenital viscera.

The muscles of the perineum are divided into:

The muscles of the anal region.

The muscles of the urogenital region:

In the male

In the female.

The muscles of the anal region are:

*Corrugator cutis ani*

*Sphincter ani externus*

*Sphincter ani internus*

The superficial fascia

The superficial fascia is thick, areolar, and extremely fatty.

The ischiorectal fossa is a space between the *Levator ani* and *Obturator internus* muscles.

The deep fascia

The deep fascia forms the borders of the ischiorectal fossa.

It encloses the anal fascia and the obturator fascia under the *Levator ani* muscle.

### **The *Corrugator cutis ani* muscle**

The anus is circled by a layer of involuntary radiating muscular fibers.

Medially the fibers enter the submucous tissue.

Muscular contractions raise the skin into ridges around the anus.

### **The *Sphincter ani externus* muscle**

It is a flat muscle, elliptical in shape.

It has a superficial and a deep parts.

The superficial arises from:

- the anococcygeal *raphé*,
- the apex of the coccyx
- the posterior part of the anus.

It inserts into the central tendinous part of perineum.

Here, are also inserted:

- the *Transversus perinæi superficialis*,
- the *Levator ani*,
- the *Bulbocavernosus* muscles.

The profound part is arranged as a sphincter of the anal canal.

Its fibers are intimate related to the *Sphincter ani internus* muscle.

Innervation: from the fourth sacral nerve.

The muscle keeps the anal canal and orifice closed.

### **The *Sphincter ani internus* muscle**

It is a muscle which encircles the first 2 cm of the anal canal.

Its inferior border is related to the *Sphincter ani externus* muscle.

It is formed by the involuntary circular fibers of the intestine.

It finishes at 3-5 mm from the anal orifice.

Its action is only involuntary.

It is accessory in closing the anal aperture.

It is also accessory in the expulsion of the feces.

## **The Muscles of the Urogenital Region in the Male**

*Transversus perinæi superficialis*

*Transversus perinæi profundus*

*Bulbocavernosus*

*Ischiocavernosus*

*Sphincter urethræ membranaceæ.*

### **Superficial fascia**

The superficial fascia of this region consists of two layers, superficial and deep.

The superficial layer is thick and contains adipose tissue.

Anterior it is continuous with the *dartos* tunic of the scrotum.

Posterior it is continuous with the fat tissue surrounding the anus.

The deep layer of superficial fascia is thin, aponeurotic,

It comes in contact anteriorly with:

- the *dartos* tunic
- the deep fascia of the penis
- the fascia of the spermatic cord
- the Scarpa's fascia superior
- the anterior wall of the abdomen.

Laterally is attached:

- to the borders of the *rami* of the pubis

- to *ischium*
- to the *crus penis*
- to the tuberosity of the *ischium*.

Posterior it is in contact with:

- the *Transversi perinæi superficiales* muscle
- the urogenital diaphragm.

In the medial part is in contact:

- with the superficial fascia
- with the median septum of the *Bulbocavernosus* muscle.

### **The central tendinous part of the perineum**

It is situated in between the urethra and anus.

Here the following muscles are attached:

- the *Sphincter ani externus*
- the *Bulbocavernosus*
- the *Transversi perinæi superficiales*
- the anterior fibers of the *Levatores ani*.

### **The *Transversus perinæi superficialis* muscles**

The muscle travels the perineal space anterior of the anus.

It has origin from tendinous fibers of the tuberosity of the *ischium*.

It is inserted into the central tendinous part of the perineum.

The simultaneous contraction of the two muscles is for stabilization of the central tendinous part of the perineum.

### **The Bulbocavernosus (*Ejaculator urinæ; Accelerator urinæ*) muscle**

It is located in the midline of the perineum, anterior of the anus.

It consists of two parts united on the median line by a tendinous raphé.

It originates from the central tendinous point of the perineum and from the median *raphé*.

It has got three types of fibers:

- the posterior fibers form a layer finished in the inferior fascia of the urogenital diaphragm.
- the middle fibers go around the bulb of the *corpus cavernosum urethræ*.
- the anterior fibers end in a fascia which covers the dorsal vessels of the penis.

The muscle empties the canal of the urethra.

The middle fibers compress the erectile tissue of the *corpus cavernosum urethræ*.

The anterior fibers produce the erection of the penis when the deep dorsal vein of the penis is compressed.

### **The Ischiocavernosus (*Erector penis*) muscle**

It covers the *crus penis*.

It is a muscle situated on the lateral border of the perineum.

It originates by fibers from:

- the tuberosity of the *ischium*
- the posterior part to the *crus penis*
- the *rami* of the pubis
- the *ischium* on either side of the *crus*.

The *Ischiocavernosus* muscle compresses the *crus penis*.

It retards the return of the blood through the veins.

It maintains the organ erect.

Its posterior limit on the *Transversus perinæi superficialis* muscle.

### **The deep fascia of the urogenital region**

The deep fascia of the urogenital region forms a protection sleeve around the *Transversus perinæi profundus* and the *Sphincter urethræ membranaceæ* muscles.

It forms a transverse septum, **the urogenital diaphragm**.

It consists of two membranous layers.

They are linked at the posterior parts.

They are separated anteriorly by structures.

The inferior fascia of the urogenital diaphragm is superficial.

It is triangular in shape.

Its apex is directed anteriorly.

Its lateral rims are attached to the pubis and *ischium*.



Its base is close to the rectum.

It is connected to the central tendinous part of the perineum.

It is perforated:

- by the symphysis pubis
- by the urethra
- by the arteries to the bulb
- by the arteries to the ducts of the bulbourethral glands
- by the deep arteries of the penis
- by the dorsal arteries of the penis
- by the nerves of the penis.

The perineal vessels and nerves pass by the base.

### **The superior fascia of the urogenital diaphragm**

It is continuous with the obturator fascia.

It can be seen attached by the anterior fibers of the pubic arch.

Posteriorly, it is continuous with the inferior fascia.

Anteriorly, is continuous with the fascial sheath of the prostate.

### **The *Transversus perinæi profundus* muscle**

It originates from the inferior *rami* of the *ischium*.

On the median line meets with the opposite one.

It is located close to the *Sphincter urethræ membranaceæ*.

Together they are named the *Constrictor urethræ* muscle.

### **The *Sphincter urethræ membranaceæ* muscle**

It surrounds the membranous portion of the urethra.

It is wrapped in the *fasciæ* of the urogenital diaphragm.

Its external fibers originate from pubis and *ischium*.

The most internal fibers form a ring around the membranous urethra.

The innervation comes from the perineal branch of the pudendal nerve.

Both muscles act together as a sphincter.

## ***The Muscles of the Urogenital Region in the Female***

They are:

*Transversus perinæi superficialis.*

*Transversus perinæi profundus*

*Bulbocavernosus.*

*Ischiocavernosus.*

*Sphincter urethræ membranaceæ*

### **The *Transversus perinæi superficialis* muscle**

In the female it is a muscular slip.

It has origin by a tendon from ischial tuberosity.

It is inserted into the central tendinous part of the perineum.

### **The Bulbocavernosus (*Sphincter vaginae*) muscle**

It stays around the vaginal orifice.

It covers the sides of the vestibular bulbs.

It is attached to the central tendinous part of the perineum.

Its fibers are attached the *corpora cavernosa clitoridis*.

The *Bulbocavernosus* diminishes the vaginal orifice.

The anterior fibers produce clitoridian erection.

### **The Ischiocavernosus (*Erector clitoridis*) muscle**

It covers the free area of the *crus clitoridis*.

It is situated on the lateral limit of the perineum.

It has origin by fibers from:

- the tuberosity of the *ischium*
- the *crus*
- the vicinity area of the *ischial ramus*.

The structure is inserted into the lateral parts and inferior surface of the *crus clitoridis*.

The *Ischiocavernosus* muscle compresses the *crus clitoridis*.

Its role is keeping the organ erection.

### **The fascia of the urogenital diaphragm**

It is attached to the public arch.

It is divided in the midline by the opening of the vagina.

Anteriorly, the urethra passes through it.

Its posterior border comes in contact with the superficial fascia of the *Transversus perinæi superficialis* muscles.

It consists of two layers.

In between of these are found:

- the deep dorsal vein of the clitoris.
- a portion of the urethra
- the *Constrictor urethra* muscle
- the internal pudendal vessels
- the dorsal nerves of the clitoris.
- the arteries and nerves of the *bulbi vestibuli*.
- a plexus of veins.

### **The *Transversus perinæi profundus* muscle**

It originates from the *rami* of the *ischium*.

It travels around the sides of the vagina.

### **The *Sphincter urethræ membranaceæ* (*Constrictor urethræ*) muscle**

It consists of external and internal fibers.

The external fibers originate from the *ramus* of the pubis.

They pass between the urethra and vagina.

The innermost fibers form a ring around the inferior part of the urethra.

The muscles of this group are supplied by the perineal nerve.

This is branch of the pudendal nerve.

## II. THE MALE GENITALIA

### ***The Scrotum***

The scrotum is a fibromuscular bag.

It is situated in between the penis and anus.

It contains two chambers.

The scrotum contains the following structures:

Testis – sperm production site.

Epididymis – to the head of each testicle.

It is a storage reservoir for sperm.

Spermatic cord – go to and from the testes.

The *Dartos* muscle is a smooth muscle, located under the skin.

It regulates the temperature of the scrotum, by folding the skin.

The scrotum is provided with blood from the anterior (from the external pudendal artery) and posterior scrotal (from the internal pudendal artery) arteries.

The scrotal veins follow the major arteries, draining into the external pudendal veins.

Cutaneous innervation to the scrotum is supplied *via* several nerves:

- genital branch of genitofemoral nerve
- anterior scrotal nerves
- posterior scrotal nerves
- perineal branches of posterior femoral cutaneous nerve.

The lymph is draining to the superficial inguinal nodes.

## **Fascial layers**

They are derived from anterior abdominal wall:

External spermatic fascia – aponeurosis of the external oblique muscle.

*Cremaster* muscle and fascia – the internal oblique muscle.

Internal spermatic fascia – from the *transversalis fascia*.

**The spermatic cord** contains the following structures:

- Testicular artery – branch of the abdominal aorta,
- Cremasteric artery and vein,
- Artery to the *vas deferens* – a branch of the inferior vesicle artery,
- Pampiniform plexus of testicular veins,
- Genital branch of the genitofemoral nerve,
- *Vas deferens*,
- Lymph vessels,
- *Processus vaginalis*.

## **Pampiniform plexus**

The pampiniform plexus is a venous network, assuring the venous drainage of the testes.

It stays around the testicular artery.

The pampiniform plexus cools the arterial blood before reaching the testes.

The inferior vena cava receives as tributary the right testicular vein.

The left renal vein receives as tributary the left testicular vein.

## **The Vas Deferens (Ductus deferens)**

The *vas deferens* is a straight, muscular tube.

It conveys sperm from the epididymis to the ejaculatory duct.

The ejaculatory duct is formed by uniting of the *vas deferens* and seminal vesicle duct.

Sperm passes through to the urethra from it.

The wall of the *vas deferens* contains a muscular coat.

This has three muscle layers:

- internal layer of longitudinal muscle,
- intermediate layer of circular muscle,
- external layer of longitudinal muscle.

The tail of the epididymis continues the *vas deferens*.

It travels the inguinal canal.

It is situated in between the urinary bladder and the ureter.

## **The Vesiculæ Seminales**

The *vesiculæ seminales* are two membranous sacs.

They are located in between the *fundus* of the urinary bladder and the rectum.

They serve as reservoirs for the semen.

They secrete a fluid in addition to the secretion of the testes.

Their anterior area has relation with the *fundus* of the urinary bladder.



It extends from the termination of the ureter to the base of the prostate.

Their posterior area has relation with the rectum.

It is separated from it the rectovesical fascia.

Their superior extremities are in relation with the *ductus deferens* and the terminations of the ureters.

They are covered by peritoneum.

Their inferior extremities go to the base of the prostate.

It ends posteriorly in a recess.

The *vesiculæ seminales* consist of three layer:

- external, areolar layer,
- middle, muscular layer, with two strata, external longitudinal and internal circular,
- internal, mucous coat.

The arteries supplying the *vesiculæ seminales* are given off from the middle and inferior vesical and middle haemorrhoidal arteries.

The veins and lymphatics accompany the arteries.

The nerves are given off from the pelvic plexuses.

## ***The Penis (Penis)***

The penis is an external organ of the male reproductive system.

It has two functions:

Sexual intercourse

When the penis undergoes erection, is filled with blood.

After ejaculation, the semen exit the urethra, via external urethral orifice.

The penis has a role in elimination of urine.

It lodges the urethra.

It conveys urine from the urinary bladder to the external urethral orifice.

From here, it is expelled outside.

### **Structure of the penis**

The penis is formed of:

#### **Root**

It is the initial, immobile part of the penis.

It is located in the superficial perineal recess of the pelvic floor.

The root contains the erectile tissues (bulb of the penis).

It also contains two muscles (*Ischiocavernosus* and *Bulbospongiosus*).

#### **Body**

It is the mobile part of the penis.

It is situated in between the root and glans.

It is attached to the pubic symphysis.

It is composed of three erectile structures – two *corpus cavernosa*, and the *corpus spongiosum*.

## **Glands**

It is the distal part of the penis.

It is formed by the distal prolongation of the *corpus spongiosum*.

It lodges the opening of the urethra, the external urethral orifice.

In the root, the erectile tissues are the left and right *crura*.

The bulb is situated in the midline of the penile root.

It lodges the urethra.

The *crura* are located laterally.

The two *crura* form two *corpora cavernosa*.

They are separated by the septum of the penis.

The bulb forms the *corpus spongiosum*, anteriorly.

The male urethra goes through the *corpus spongiosum*.

The *corpus spongiosum* enlarges to form the *glans penis*.

## **Muscles**

In the root of the penis there are the following muscles:

### *Bulbospongiosus* muscle

It is in relation with the bulb of the penis.

When contracts, eliminates the semen and urine.

Some fibres help in maintaining erection.

### *Ischiocavernosus* muscle

It encircles the two *crura* of the penis.

When contracts, help the blood from the cavernous spaces to pass into the *corpus cavernosa*.

Being an erectile structure, has two covers.

The superficial layer is the deep fascia of the penis.

It continues the deep perineal fascia.

The next fascia is the *tunica albuginea*.

It covers each cavernous body.

The root of the penis is sustained by two ligaments.

The suspensory ligament comes from deep fascia.

It connects the erectile structures of the penis to the pubic symphysis.

The fundiform ligament comes from abdominal fat tissue.

The skin is pigmented.

The prepuce is contains skin and fascia.

It is situated at the constricted part of the *glans*.

The prepuce is linked to the skin of the *glans* by the *frenulum*.

The area from the *glans* and prepuce is named the preputial sac.

The penis is supplied with blood *via*:

- dorsal arteries of the penis
- deep arteries of the penis
- bulbourethral artery.

The arteries are branches of the internal pudendal artery.

The cavernous spaces are drained into the deep dorsal vein of the penis.

The superficial dorsal veins collect blood from the superficial structures of the penis, the skin and fat tissues.

The penis is supplied by sacral spinal cord and spinal ganglia.

The dorsal nerve of the penis innervates sensorial and sympathetic the penian skin and *glans penis*.

Parasympathetic innervation: from the cavernous nerves from the prostatic nerve plexus.

### **Internal structure**

The penis is a pendulous organ.

It is suspended from the anterior and lateral parts of the pubic arch.

It contains the most part of the urethra.

It is formed of three cylindrical masses of cavernous tissue.

These are bound together by fibrous tissue.

They are also lined with skin.

Two of the masses are laterally, the *corpora cavernosa penis*.

One is median, the *corpus cavernosum urethræ*.

### **The *Corpora cavernosa penis***

They form the greater part of the penis tissue.

They diverge posteriorly in two processes, the *crura*,

These are connected to the pubic arch.

Each *crus* starts by a process anterior.

It presents the bulb of the *corpus cavernosum penis*.

Each *corpus cavernosum penis* finishes in an extremity, at distance from the penis.

The *corpora cavernosa penis* are situated in a fibrous tunic.

They have superficial and deep fibers.

The superficial fibers are longitudinal.

The deep fibers are circular.

These form in the median plane the septum of the penis.

### **The *Corpus cavernosum urethræ* (*Corpus spongiosum*)**

It lodges the urethra.

It forms in the posterior part the urethral bulb.

From the inferior fascia of the urogenital diaphragm gets a fibrous coat.

The urethra enters the bulb *via* its superior surface.

The glans and the anterior aspect of the *corpus cavernosum urethræ* leave the *corpora cavernosa penis*.

The part of the *corpus cavernosum urethræ* situated anterior of the bulb goes in a sulcus on the inferior surface of the *corpora cavernosa penis*.

Its anterior border is forms an expansion, the *glans penis*.

At the apex of the *glans* is the external urethral orifice.

### **The root (*Radix penis*)**

It is formed of the different crura, one on either side.

The root of the penis is situated in the perineum.

It is bordered anteriorly of the symphysis pubis by the fundiform and suspensory ligaments.

It divides into two parts, surrounding the root of the penis.

### **The body (*Corpus penis*)**

It extends from the root to the final part of the *corpora cavernosa penis*.

Here, they are intimately linked each other.

In between their junction, on the superior surface there is a *sulcus* for the deep dorsal vein of the penis.

On the inferior surface there is another *sulcus*, for the *corpus cavernosum urethræ*.

The body is wrapped by fascia.

This is continuous superiorly with the fascia of Scarpa.

Inferiorly it prolonges with the *dartos* tunic of the scrotum and the fascia of Colles.

The body's extremity is formed by the *glans penis*.

It is ended anteriorly with the *corpus cavernosum urethræ*.

It is separated from the body by the neck, over by the *corona glandis*.

The tegument covering the penis is thin, dark, and lack of fat tissue.

The root of the penis is continuous over the pubes, scrotum, and perineum.

At the neck level becomes folded and forms the prepuce.

The internal layer of the prepuce is continuous with the skin covering the *glans*.

Posterior to the external urethral orifice it forms the *frenulum* of the prepuce.

The skin covers the *glans* and is continuous with the urethral membrane.

It is devoid of hair.

There are glands in the *corona*, neck, *glans* and prepuce.

They secrete a sebaceous fluid, which contains casein.

When mixed with epithelial cells it is named *smegma*.

The prepuce covers a large part of the *glans*.

It is separated from it by a sac, the preputial sac.

This presents two *fossæ*, on each side of the *frenulum*.

From the internal surface of the fibrous envelope of the *corpora cavernosa penis* are given off some fascicles.

They go internally of these *corpora cavernosa*, subdividing them into compartments.

The structure has got a spongy appearance.

These fascicles are called *trabeculæ*.

They are formed of:

- white fibrous tissue,
- elastic fibers,
- muscular fibers,
- arteries,
- nerves.

The interspaces (or the cavernous spaces) are large in the center.



They have a long transversal diameter.

They contain blood.

They contain cells lining them, resembling with the ones of the veins.

The fibrous layer covering the *corpus cavernosum urethræ* is more elastic than the one in the *corpora cavernosa penis*.

The *trabeculæ* are thin, uniform in size.

The external layer of the *corpus cavernosum urethræ* is formed of:

- unstriped muscular fibers,
- a layer of cells similarly with the ones that are around the canal of the urethra.

The arteries of the cavernous spaces are the deep arteries of the penis and the dorsal arteries of the penis.

They penetrate the fibrous capsule superiorly, at the anterior part of the penis.

In the cavernous part the arteries divide into branches.

Some of these arteries finish in a capillary network.

There are arteries which form convoluted, dilated vessels, the helicine arteries.

They also give off small capillary branches for the trabecular structure.

They are abundant in the posterior part of the *corpora cavernosa*.

The blood from the cavernous spaces is returned by veins.

From the base of the *glans penis* they converge on the dorsal surface of the penis to form the deep dorsal vein.

On the superior surface of the *corpora cavernosa* there are veins that join and drain into the same vein.

From the inferior surface of the *corpora cavernosa penis* there are veins starting.

They receive tributaries from the *corpus cavernosum urethræ*.

These are draining into the deep dorsal vein.

From the root of the penis there are veins that finish into the prostatic plexus.

The nerves are branches of the pudendal nerve.

### **The ejaculatory ducts (*Ductus ejaculatorii*)**

There are two, one on either side of the midline.

They are formed by the unit of the *vesicula seminalis* duct with the *ductus deferens*.

They start at the base of the prostate.

They go anterior and inferior between its middle and lateral lobes.

The ducts diminish in size toward their end.

The layers are:

- an external, fibrous layer,
- a muscular layer, having an external circular, and an internal, longitudinal layer,
- a mucous membrane.

### III. THE FEMALE GENITALIA

They are:

- the *mons pubis*,
- the *labia majora et minora pudendi*,
- the *clitoris*,
- the *bulbus vestibule*
- the greater vestibular glands.

***The External Genital Organs (Partes Genitales Externæ Muliebres) Mons pubis (Commissura labiorum anterior; Mons Veneris)***

The external organs are situated inferior to the urogenital diaphragm.

The pubic arch stays inferior and anterior to them.

The pubic symphysis is located anterior to them.

***The Labia majora (Labia majora pudendi)***

They are longitudinal cutaneous folds.

They are situated inferior and posterior from the *mons pubis*.

They have the lateral limit as a fissure or cleft, the pudendal cleft or *rima*

Into the pudendal cleft open the vagina and urethra.

Each *labium* consists of two surfaces, internal and external ones.

In between there is a large fat tissue, like the *dartos tunic* of the scrotum.

The *labia* are thicker anteriorly, forming together the anterior labial commissure.

Also, they form the posterior labial commissure, which is the posterior limit of the *pudendum*.

The area between the posterior commissure and the anus is actually the perineum.

The *labia majora* is the correspondent of *scrotum* in the male.

### **The *Labia minora* (*Labia minora pudendi*, *Nymphæ*)**

They are two cutaneous folds, located between the *labia majora*.

They last from the *clitoris* and finish on the lateral parts of the vaginal orifice.

In the virgin their posterior part *labia minora* are united by a skin, the *frenulum* of the labia (fourchette).

The *labium minus* divides anteriorly into two parts.

The superior part goes superior the *clitoris*.

Meeting its fellow opposite, forms the *preputium clitoridis*, a fold which suspends the *glans clitoridis*.

The inferior part goes inferior the *clitoris*.

Uniting with the one from the other side, forms the *frenulum* of the *clitoris*.

## **The Clitoris**

It is an erectile structure.

It is homologous with the penis in male.

It is situated inferior the anterior labial commissure.

It consists of two *corpora cavernosa*.

It is formed by an erectile tissue.

Each *corpus* attaches to the *rami* of the *pubis* and *ischium* by *crus*.

Its free extremity, *glans clitoridis* is a small eminence.

The *clitoris* has got a suspensory ligament and two muscles, the *Ischiocavernosi*.

They are attached into the *crura* of the *clitoris*.

## **The Vestibule (*Vestibulum vaginæ*)**

The vestibule of the vagina is a space in between the *labia minora* and the *glans clitoridis*.

Here, there are:

- the urethral orifice,
- the vaginal orifice,
- the openings of the greater vestibular glands ducts.

## **The external urethral orifice (*Orificium urethræ externum*)**

It is located at 2 cm posterior the *glans clitoridis* .

It is situated anterior of the vagina.

### **The vaginal orifice**

It is a median opening, situated inferior and posterior to the opening of the urethra.

### **The hymen**

It is a fold of mucous tissue, located at the orifice of the vagina.

It could be absent.

It also could form a complete septum to the lower end of the vagina (imperforate hymen).

After first copulation, remain small elevations, the *carunculæ hymenales*.

### **The Bulb of the vestibule (*Bulbus vestibuli*)**

It is the homologue of the *corpus cavernosum urethræ* of the male.

They are formed of two structures of erectile tissue, situated on the side of the vaginal orifice.

They are related to the greater vestibular glands.

They are in relation with the urogenital diaphragm.

The *Bulbocavernosus* muscle covers them.

### **The Greater vestibular glands (*Glandulæ vestibularis major Bartholini*)**

They are the homologues of the bulbourethral glands in the male.

They consist of two small elevations, situated one on either side of the vaginal orifice.

Each gland opens through a duct, in the *sulcus* between it and the *labium minus*.

## ***The External Genital Organs***

They are known as the vulva or the *puendum*.

Its functions are:

- To act during sexual intercourse.
- To assist in micturition.
- To defend the internal reproductive tract from infection.

### **The Vulva**

It consists of different anatomical structures:

- *Mons pubis*: a fat pad, covered in hair,
- *Labia majora*,
- *Labia minora*.

Blood supply to the external genitalia is provided by the pudendal arteries.

The veins of the vulva are the pudendal veins.

Lymph is tributary to the superficial inguinal lymph nodes.

Its anterior aspect is supplied by the ilioinguinal nerve, and the genital branch of the genitofemoral nerve.

The posterior part of the vulva is innervated by the pudendal nerve.

## ***The Internal Genital Organs***

### **The Vagina**

It lasts from the vestibule to the uterus.

It is situated posterior to the urinary bladder and anterior to the rectum.

Its axis forms with that of the uterus an angle of more than 90°.

The shape of its inferior part is an H.

The lateral limbs are convex to the midline.

Its middle part has looks like a transverse slit.

It is constricted at its initial part.

It is dilated in its midpart.

It is narrow at the uterine end.

It encircles the vaginal part of the *cervix uteri*.

Its attachment is on the posterior and the anterior walls of the uterus.

The recess posterior to the *cervix* is named the posterior *fofnix*.

The anterior recesses and the side's recesses are called the anterior and lateral *fofnices*.

Its anterior aspect comes in contact with the *fundus* of the urinary bladder and the urethra.

Its posterior aspect is separated from the rectum by the rectouterine pouch.

The rectovesical recess separates it by the urinary bladder.



Its inferior part is separated from the anal canal by the perineal body.

Its sides are situated in between the *Levatores ani* muscles.

The relations are:

- with the terminal parts of the ureters,
- with the *fundus* of the urinary bladder.

The vagina consists of an internal mucous layer and a muscular coat separated by erectile tissue.

The mucous membrane (*tunica mucosa*) is continuous superior with that lining the uterus.

The submucous layer contains large veins which form a plexus.

It is considered as erectile structure.

The muscular layer consists of two layers: an external longitudinal, and an internal circular.

Its inferior part is surrounded by the *Bulbocavernosus* muscle.

## IV. THE PERINEUM TOPOGRAPHY

In clinical, the term “perineum” describes the part between the external *genitalia* and the anus.

The perineum has a diamond shape.

The perineum is subdivided by a line between the ischial tuberosities.

This forms the anterior urogenital triangle and the posterior anal triangle.

Here, there are different structures of the perineum.

The margins of the perineum are:

Anterior – pubic symphysis.

Posterior – apex of the coccyx.

Laterally – inferior pubic *rami*

- inferior ischial *rami*
- the sacrotuberous ligament.

Roof – pelvic floor.

Base – skin

- fascia.

When the lower limbs are abducted we have different limits.

So, the limits are:

Anterior – *mons pubis* in females/ base of the penis in males.

Laterally – medial surfaces of the thighs.

Posterior – superior end of the intergluteal cleft.

## Posterior perineum

Layers

Skin

Subcutaneous cellular tissue

Muscular

## ***Ischiorectal Fossa (Fossa ischiorectalis)***

Contains the adipose center of perineum.

The fossa is prismatic in shape.

It has the base directed to the surface of the perineum.

It has the apex where the *Obturator internus* muscle meets the anal *fasciæ*.

Medially is close to the *Sphincter ani externus* muscle and *Levator ani* muscle.

It is covered by the deep perineal fascia and the middle perineal fascia.

*Levator ani* muscle separates ischiorectal fossa (Richet inferior pelvirectal space) by the pelvisubperitoneal space (Richet superior pelvirectal space).

Laterally comes in contact with:

- the tuberosity of the *ischium*
- the *Obturator internus* muscle
- the obturator fascia

Inferiorly forms Alcock`s pudendal canal.

Inferiorly comes in contact with:

- the skin
- the subcutaneous tissue.

## **The prolongations of the ischiorectal fossa**

### **The anterior prolongation**

It is a horizontal triangular prism.

It has a base toward posterior, communicating with the ischiorectal fossa.

Its apex is toward anterior, to the pubic symphysis.

It enters the anterior perineum, passing over the urogenital diaphragm.

### **The posterior prolongation**

It passes under the *Gluteus maximus* muscle.

It unites with the fellow opposite.

The two ischiorectal *fossae* and their prolongations form a horseshoe with concavity toward anterior, surrounding the pelvic organs.

In the space are the inferior haemorrhoidal vessels and nerves.

Posteriorly, is situated the perineal and perforating cutaneous branches of the pudendal plexus.

Anteriorly, there are the posterior scrotal/labial vessels and nerves.

The internal pudendal vessels and pudendal nerve go in the Alcock's canal.

### **Male anterior perineum**

Presents the male external genitalia: the penis and the two testicles, in the scrotum.

Its layers are:

Skin

Subcutaneous cellular tissue

Superficial perineal fascia

Penile fossa

Urogenital diaphragm

Anterior prolongation of the ischiorectal fossa

### **Penile fossa**

Limits:

Laterally, ischiopubic rami.

Inferior, superficial perineal fascia, subcutaneous cellular tissue, and skin.

Superiorly, urogenital diaphragm.

Contents:

*Corpora cavernosa*

*Ischiocavernosae* muscles

*Bulbus corpus spongiosus*

*Corpus spongiosus*

Urethra

Cowper bulbourethral glands

### **Female anterior perineum**

Presents the external female genitalia, represented by the vulva.

Limits are identically with the male`s.

Layers:

Skin

Subcutaneous cellular tissue

Superficial perineal fascia

Clitoridian fossa

Urogenital diaphragm

Anterior prolongation of the ischioanal fossa

### **Clitoridian fossa**

It has identical limits with the penile fossa:

Lateral are:

- the root of the clitoris,
- Constrictor muscle of vulva,
- Bartholin greater vestibular glands,
- Vestibular *bulbi*,
- *Bulbocavernous bulbi*.

At this level there is the ischiobulbar triangle.

### **Anterior prolongation of the ischiorectal fossa**

Is prismatic triangular in shape.

On frontal section is a triangle.

Medial wall is formed of the *Levator ani* muscle.

Superior is the deep parietal fascia.

Inferior is the middle parietal fascia.

The medial wall separates the anterior prolongation of the ischiorectal fossa by the pelvisubperitoneal space.

The lateral wall is formed by:

- the *Obturator internus* muscle
- the obturator fascia
- the pubis
- the obturator membrane
- the *Obturator externus* muscle.

At the meeting point between the medial and lateral walls there is the tendinous arch of Rouget *Levator ani* muscle.

Inferior wall formed by the urogenital diaphragm.

It separates the anterior prolongation of the ischioanal fossa by the penile/clitoridian fossa.

At the meeting point between the inferior and lateral walls there is the Acock`s pudendal canal.

### **The anal triangle**

It is the posterior part of the perineum.

It is limited by:

- the coccyx,
- the sacrotuberous ligaments,
- an imaginary line between the ischial tuberosities.

The main contents of the anal triangle are:

- Anal aperture
- External anal sphincter muscle
- Ischioanal *fossae*
- is the pudendal nerve.

### **The urogenital triangle**

It is the anterior part of the perineum.



Is limited by:

- the pubic symphysis
- ischiopubic *rami*
- a line between the two ischial tuberosities.

The triangle lodges the external *genitalia* and urethra.

The urogenital triangle has a layer of strong deep fascia: the perineal membrane.

This has two depressions.

Deep perineal depression is a potential space between the deep fascia of the pelvic floor (superiorly) and the perineal membrane (inferiorly).

It lodges:

- the urethra
- the external urethral sphincter
- the vagina.

The bulbourethral glands and the deep transverse perineal muscles are situated here in the male.

## V. REFERENCES

1. [www.teachmeanatomy.com](http://www.teachmeanatomy.com)
2. [www.teachmeSeries.com](http://www.teachmeSeries.com)
3. Gray, H., Gray`s Anatomy 1918, 15<sup>th</sup> Edition, 2010.
4. [www.wesnorman.com](http://www.wesnorman.com)
5. A.M. Şişu, S.L. Bolintineanu, *The Perineum*, Ed Eurostampa, Timisoara, 2019.