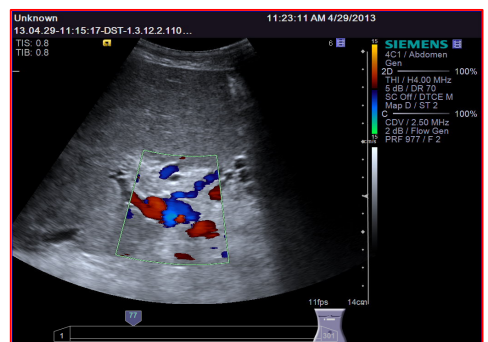
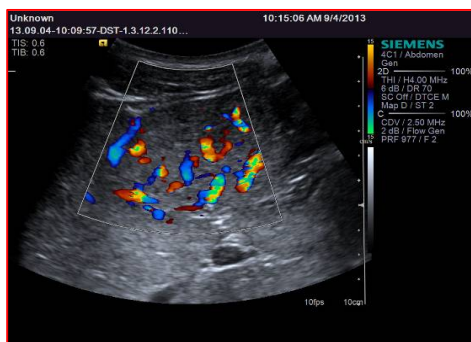
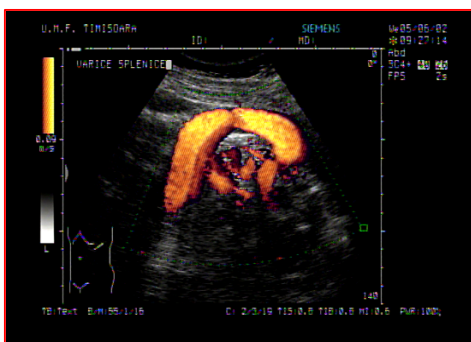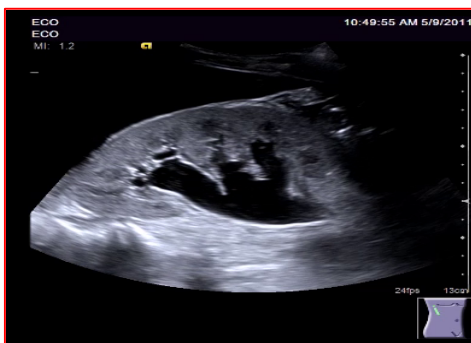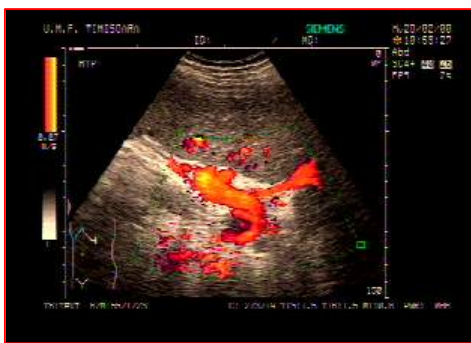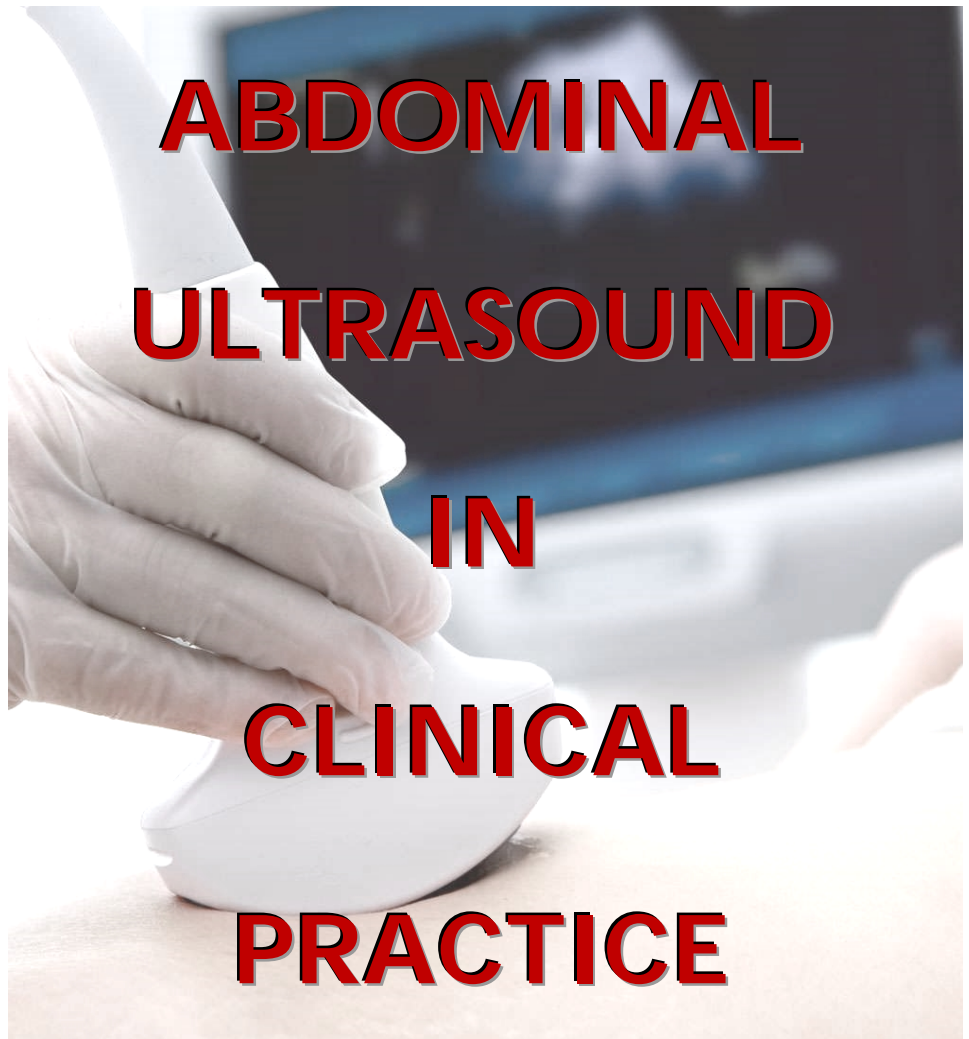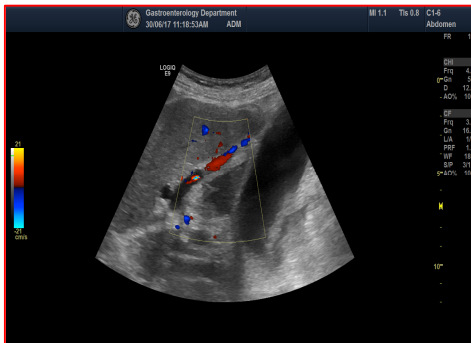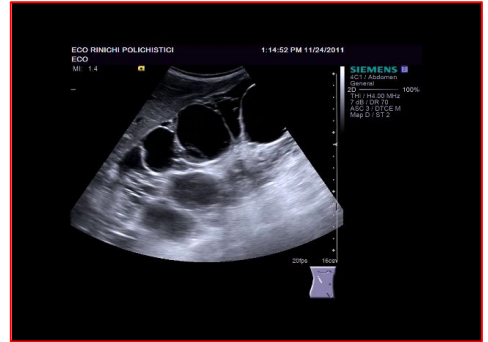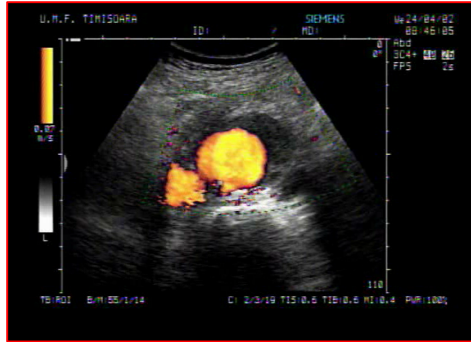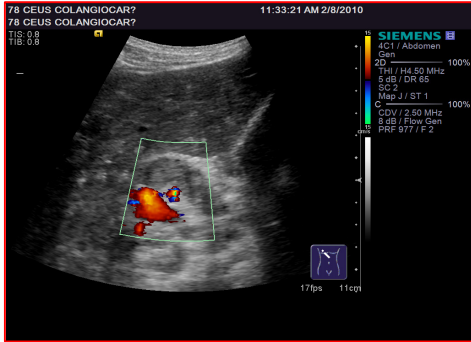"VICTOR BABEȘ" UNIVERSITY OF MEDICINE AND PHARMACY TIMIȘOARA

IOAN SPOREA

CRISTINA CIJEVSCHI PRELIPCEAN

**ABDOMINAL ULTRASOUND
IN
CLINICAL PRACTICE**

„Victor Babeș” Publishing

Timișoara, 2017





TEXTBOOK collection

VICTOR BABEȘ PUBLISHING

2 Eftimie Murgu Sq., Room. 316, 300041 Timișoara

Tel./ Fax 0256 495 210

e-mail: evb@umft.ro

www.evb.umft.ro

General director: Prof. univ. dr. Dan V. Poenaru

Director: Prof. univ. dr. Andrei Motoc

Scientific referent: Prof. univ. dr. Lucian Petrescu

CNCSIS code: 324

© 2017

All rights reserved. Partial or in whole reproduction of this book, on any media, is strictly forbidden without the written approval of the authors and will be sanctioned in accordance to current copyright laws

ISBN 978-606-786-051-1

Professor IOAN SPOREA, MD PhD

Consultant in Gastroenterology and Internal Medicine

HEAD OF THE DEPARTMENT OF GASTROENTEROLOGY AND HEPATOLOGY

"VICTOR BABEȘ" UNIVERSITY OF MEDICINE AND PHARMACY TIMIȘOARA

Professor CRISTINA CIJEVSCHI PRELIPCEAN, MD PhD

Consultant in Gastroenterology and Internal Medicine

INSTITUTE OF GASTROENTEROLOGY IAȘI

"GR. T. POPA" UNIVERSITY OF MEDICINE AND PHARMACY IAȘI

In collaboration with:

Professor Lucas Greiner, MD, PhD

Director of ISCUS

Wuppertal, Germany

Associate Professor Roxana Șirli, MD, PhD

Consultant in Gastroenterology and Internal Medicine

DEPARTMENT OF GASTROENTEROLOGY AND HEPATOLOGY

"VICTOR BABEȘ" UNIVERSITY OF MEDICINE AND PHARMACY TIMIȘOARA

Lecturer Mirela Dănilă, MD, PhD

Consultant in Gastroenterology

DEPARTMENT OF GASTROENTEROLOGY AND HEPATOLOGY

"VICTOR BABEȘ" UNIVERSITY OF MEDICINE AND PHARMACY TIMIȘOARA

Associate Professor Alina Popescu, MD, PhD

Consultant in Gastroenterology and Internal Medicine

DEPARTMENT OF GASTROENTEROLOGY AND HEPATOLOGY

"VICTOR BABEȘ" UNIVERSITY OF MEDICINE AND PHARMACY TIMIȘOARA

CONTENTS:

Foreword	6
1. THE LIVER	8
2. THE GALLBLADDER	70
3. THE PANCREAS.....	92
4. THE SPLEEN.....	118
5. THE DIGESTIVE TRACT	126
6. THE KIDNEYS	143
7. THE RETROPERITONEUM (LYMPH NODES, INFERIOR VENA CAVA, AORTA).....	158

Foreword

What is the aim of this book? Starting from the concept of clinical ultrasound we promote, our aim is to integrate imaging data in a clinical context, considering the patient as a whole. Based on medical history, clinical examination, biologic and paraclinic investigations, we will obtain a diagnosis as accurate as possible, followed by a treatment adequate for the disease and its stage.

Usually imaging books focus on images, and do not include clinical data that lead to a specific imaging appearance. This approach can be found in imaging treatises, but for the young clinician (fellow in training or young specialist), as well as for an experienced doctor, the stream of thought and the approach should go from symptoms and syndromes, to investigations and diagnosis. At the same time, the high rate of new information regarding etiopathogenesis, assessment techniques and treatment in some diseases frequently makes the doctor lag behind the information flow. This happens more rarely in the main field of activity and more frequently regarding related specialties (e.g. for a gastroenterologist, information in the field of hematology, nephrology, etc.).

To whom is this book addressed? To all clinicians regardless of their specialty, as well as to imaging specialists, who need to have clinical information on a disease not only to treat the disease, but also to understand the strategy of diagnosis and staging of the disease.

This book is intended for internists (and specialties derived from internal medicine such as gastroenterology, nephrology, hematology, metabolic and nutritional diseases), surgeons, emergency doctors or family physicians. This last category has perhaps one of the most difficult tasks, of being an interface between the patient and the specialist. The position of the family physician, having to decide whether to refer a patient to a specialist, or to continue the investigation of an illness himself/herself, is often extremely difficult. Both approaches involve certain risks: the frequent referral of a patient to a specialist will lead to the patient's refusal to see "one more specialist", while the delay in asking for specialized advice might postpone diagnosis and consequently, the initiation of adequate treatment. Hence, the responsibility of the family doctor to stay as accurately informed as possible in many areas, for an adequate judgment of the clinical case, in order to seek the specialist's advice at the right time.

A particular category of doctors that we had in mind while writing this book is that of fellows in training. The beginning of residency is a time of success (at the residency examination), but also of responsibility and stress in front of the complexity of mostly new material. This is why we aim at providing fellows in training with useful material for their training in the field of ultrasound.

Last, but not least this book is intended for radiologists. The process of their training is mainly devoted to learning how to work with images (in ultrasound, computed tomography or magnetic resonance imaging). However, the relationship with the clinical information, with novelties in clinical specialties is most frequently absent. This is why the results formulated by radiologists are often descriptive and rarely have a clinical conclusion. Training the imaging

specialist in clinical ultrasound will help him/her to integrate the result of the examination with the clinical judgment of the case.

We hope that the combined ultrasound and clinical information, along with images that we considered the most conclusive, will allow newcomers to this field to understand ultrasound accurately, and experienced practitioners to verify and consolidate their knowledge. The book presents the point of view of the authors, based on a long ultrasound experience and teaching practice.

The authors

CHAPTER 1

THE LIVER

The ultrasound (US) of the liver is an area in which the optimum use of this technique along with the experience of the examining doctor can establish a difficult diagnosis and can frequently prevent other, possibly more expensive examinations.

The US of the liver must be carried out based on a previously made clinical diagnosis (the patient referred for US should be accompanied by a form indicating the clinical diagnosis, or better, the ultrasonographer will examine a patient he already knows from the clinic). For ambulatory patients, the US examination will start with a short medical history and with the clinical examination, in which the inspection and palpation of the abdomen and liver can be extremely useful. The easiest and perhaps the most accurate diagnosis of hepatomegaly is made by palpation (which is more accurate than any imaging method). The consistency of the liver can also be very precisely evaluated by palpation. The daily practice of liver palpation of an experienced clinician will certainly lead to better results compared to the limited experience of a young doctor.

Clinical thinking will be different if the liver is soft as compared to a hard liver. Thus, if the liver is enlarged and hard on palpation, signs of liver cirrhosis or tumoral liver (either primary tumor or metastases) will be sought by ultrasound. Although liver cirrhosis most frequently has obvious imaging signs, approximately 20-30% of cirrhotic patients will have a normal hepatic US appearance. However, knowing the clinical characteristics of the liver, even if the US appearance is normal, additional examinations will be performed (elastography techniques: transient elastography - FibroScan, VTQ by ARFI - Siemens elastography; upper digestive endoscopy for possible esophageal varices; biologic tests; liver biopsy or laparoscopy for histological staging).

Many times, the ultrasonographer, who often knows the clinical diagnosis of liver cirrhosis, cannot resist the impulse to correlate his/her knowledge on the disease with the imaging appearance. Thus, although in a number of cirrhosis cases the liver structure is homogeneous (without major architectural alterations), knowing the clinical diagnosis the doctor describes it as heterogeneous or even with micronodular structure. The objectivity of the imaging description should prevail even in a known clinical context.

Liver US can be divided into:

- A) Diagnosis of diffuse liver diseases;
- B) Diagnosis of focal liver lesions
 - cystic
 - solid: a) benign
 - b) malignant

A) DIAGNOSIS OF DIFFUSE LIVER DISEASES

1. ACUTE HEPATITIS

Definition: acute hepatitis is a humoral and biochemical syndrome characterized by increased aminotransferases. It is classically considered that a more than 10 fold increase in aminotransferases level (particularly ALT) is a typical sign for acute hepatitis. In Romania, acute hepatitis is most frequently caused by viral infections and rarely by other causes (drugs, acute alcoholic hepatitis, acute autoimmune hepatitis, etc.).

Acute viral hepatitis can be caused by hepatotropic viruses (hepatitis A, B, C and E) or by other viruses such as Herpes virus, Epstein-Barr or Cytomegalovirus.

Acute viral hepatitis can evolve with or without jaundice. It should be mentioned that a high percentage of acute viral hepatitis (regardless of the causative virus, but particularly those caused by B or C virus) are anicteric. This is why in an adult population, particularly in endemic areas for hepatitis such as Romania, signs of previous infection, such as anti-HAV or anti-HBs antibodies are frequently positive (although many patients do not remember having a jaundice episode).

The health care policy to vaccinate newborns against hepatitis B virus aims at diminishing the incidence of acute and chronic hepatitis. In the endemic area of Romania, it is also recommended to vaccinate children against hepatitis A virus. The solution of the bivalent A+B vaccination is a correct alternative (Twinrix).

The *clinical signs* of acute hepatitis are fatigue, dyspeptic syndrome, fever and jaundice that often occur at the onset hence the frequent clinical situation in which abdominal ultrasound is performed for the assessment of an icteric syndrome.

The **liver ultrasound** findings in acute hepatitis are *nonspecific*, frequently completely normal, although sometimes, suggestive ultrasonographic signs can be present.

Gallbladder wall thickening is found in up to 80% of cases of acute hepatitis, particularly in viral hepatitis (Fig. 1.1). It is caused by hypoalbuminemia that generates gallbladder wall edema. Finding a thickened gallbladder wall in a young or middle aged person with dyspeptic syndrome and particularly with jaundice can be a useful diagnostic element for acute hepatitis.

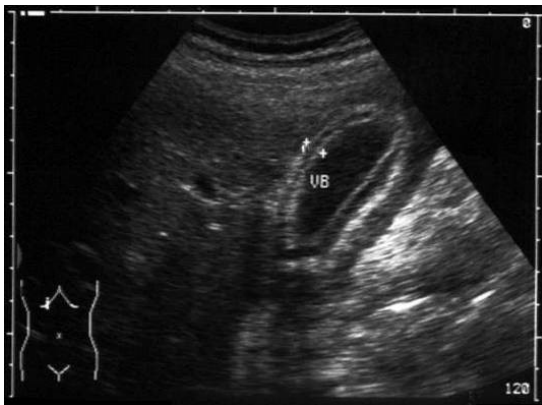

Fig. 1.1 Gallbladder wall thickening in acute hepatitis

Other less specific ultrasonographic signs are *diffuse hepatic hypoechogenicity* (difficult to demonstrate in the absence of a landmark structure) due to liver edema and possibly *mild splenomegaly* (slightly enlarged spleen – considering a spleen < 12 cm long as normal). Most frequently, splenomegaly is a sign of background chronic liver disease, on which an acute episode can occur. A particular situation is a background chronic liver disease, on which acute viral hepatitis with a different virus develops (for example, chronic hepatitis B, complicated with acute viral hepatitis D or A, or more rarely C). If an acute cytolysis syndrome (aminotransferases more than 10 times higher than the normal range) occurs in a patient with chronic viral hepatitis, an acute viral hepatitis with a different virus should be suspected.

In acute alcoholic hepatitis, the background can be that of liver steatosis (ultrasound aspect of *hyperechoic*, “*bright*”, *liver with posterior attenuation*). Also, in acute alcoholic hepatitis, a small amount of transient ascites can sometimes be found.

Therefore, *in the diagnosis of acute hepatitis, ultrasound has a limited value*, the thickening of the gallbladder wall (doubled appearance) being the most frequent sign. Ultrasound is much more useful in the differential diagnosis of the etiology of an icteric syndrome, in which case it can differentiate parenchymal jaundice (non-dilated bile ducts) from obstructive jaundice (dilated bile ducts).

Medical history can play an important role in establishing the etiology of an acute hepatitis (recent consumption of a large amount of alcohol, hepatotoxic drugs or contact with hepatotoxic agents). Viral markers can be useful (Ag HBs), but irrelevant in the initial phases of hepatitis C (in which case PCR RNA HCV should be performed).

2. CHRONIC HEPATITIS

Definition: chronic liver inflammatory disease of various etiologies, with an evolution of at least 6 months, without a tendency to healing, with necrotic and fibrotic lesions as a histopathological substrate. Thus, after accidental detection of moderate cytolysis, its chronic character should be declared only after at least 6 months, since moderately increased aminotransferases levels can be a sign of a previously undiagnosed acute hepatitis, which will heal spontaneously in several weeks.

Chronic hepatitis is most frequently caused by hepatitis B, C or D viruses. Hepatitis A does not evolve to chronic hepatitis. Approximately 5-10% of the cases of acute hepatitis B will become chronic, while in acute hepatitis C, chronicity rate reaches up to 80% of cases (hepatitis C is most frequently anicteric in the acute phase). Other causes of chronic hepatitis are autoimmune hepatitis, drug induced liver disease, cholestatic hepatitis or abnormal metals storage in the liver – hemochromatosis (iron) and Wilson disease (copper). In patients with chronic hepatitis, etiology (for therapy) and histological staging (for prognosis and therapy) must be established.

The *clinical signs* of chronic hepatitis can be absent, discrete or more rarely noticeable. Chronic hepatitis (both B and C) are to a large extent completely asymptomatic and detected accidentally (most frequently by high aminotransferases levels found during a routine examination). This is why we consider that any patient with increased aminotransferases levels (minimally or slightly increased; even in the event that they return to normal values on a subsequent examination) should be investigated. In Romania, the most frequent cause of increased aminotransferases levels in asymptomatic patients seems to be the infection with the hepatitis C virus (approx. 3.5% of the Romanian population is anti-HCV positive). Other frequent causes are chronic hepatitis B and liver steatosis (alcoholic or non-alcoholic steatohepatitis - NASH).

A frequent sign of chronic hepatitis is fatigue, often intense. The lack of correlation between the intensity of the physical and intellectual activity and fatigue severity can be a sign suggesting chronic liver disease. Other symptoms in chronic hepatitis are dyspeptic syndrome, exercise or rest hepatalgia, mild jaundice, bleeding gums, purpura, etc.

Which tests should be performed when chronic hepatitis is suspected? A minimum of biological tests: aminotransferases (GOT/AST, GPT/ALT), gamma-glutamyl transpeptidase, alkaline phosphatase, HBs Ag, and anti-HCV antibodies should be determined.

Aminotransferases, the expression of hepatocyte lesion, may increase in all liver disease (however, 1/3 of chronic hepatopathies can evolve with normal aminotransferases). Gamma-glutamyl transpeptidase (GGT) is a reliable marker of cholestasis (if alkaline phosphatase is also increased) or of chronic alcohol consumption (if only GGT is increased). The markers of viral hepatitis are HBs Ag for chronic hepatitis B and anti-HCV antibodies for chronic hepatitis C. Chronic hepatitis D is not possible in the absence of hepatitis B.

Ultrasound examination in chronic hepatitis does not reveal typical signs. Most frequently (in approx. 50% of cases), *splenomegaly* is detected. Most authors consider a spleen smaller than 12 cm long as normal. The width or thickness of the spleen is not equally important, but a globulous

spleen can be a sign of activation of the reticuloendothelial system. Usually, in chronic hepatitis, the spleen is slightly enlarged (13-14 cm) (Fig. 1.2). Larger splenomegaly (more than 15 cm) suggests, in a clinical context, liver cirrhosis. It should be emphasized that a normal spleen does not exclude a chronic hepatitis.

In a personal study, we aimed to correlate the size of the spleen with the histological activity of chronic hepatitis, but we found only a weak direct correlation (the correlation between the spleen size and Knodell histological score was 0.47).

Ultrasound evidence of hilar adenopathies (lymph nodes of the hepatoduodenal ligament) is relatively common. They can occur in chronic hepatitis B or autoimmune hepatitis, but are extremely frequent in chronic hepatitis C (Fig. 1.3). Italian studies have reported the presence of adenopathies in the hepatoduodenal ligament in approximately 70% of chronic hepatitis C cases and have monitored the evolution of lymph node size for the evaluation of therapeutic response to interferon.

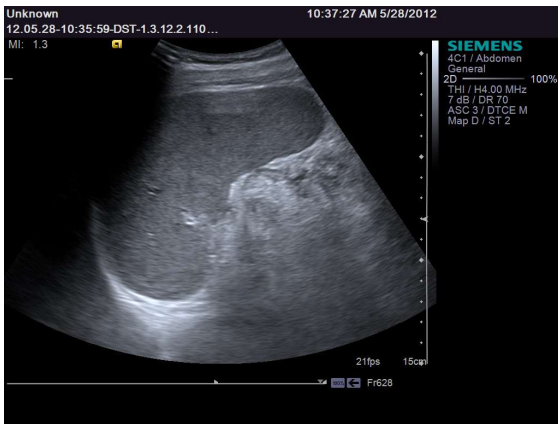


Fig. 1.2 Splenomegaly

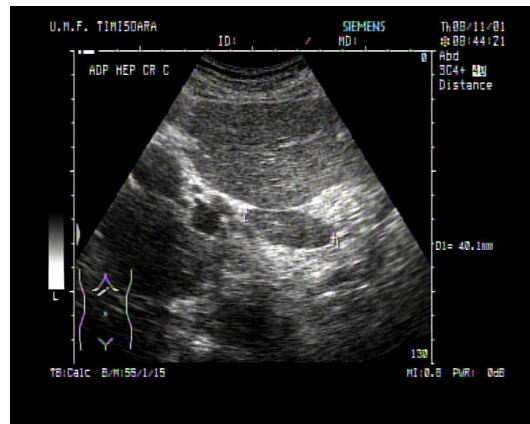


Fig. 1.3 Hilar oval adenopathy in chronic hepatitis C

In the current ultrasound practice, when hilar adenopathy is identified, one should further investigate for the presence of hepatitis C virus (anti-HCV antibodies) and hepatitis B virus (HBs Ag), or for chronic autoimmune or cholestatic hepatitis.

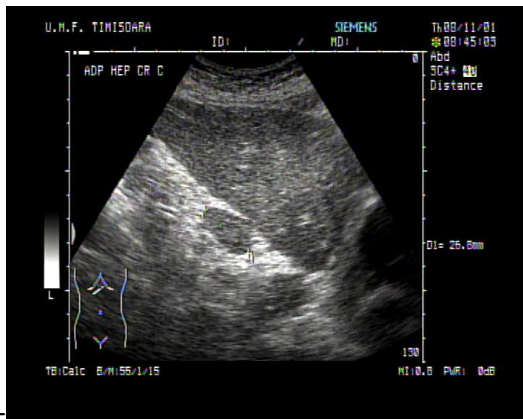


Fig 1.4. Hilar oval adenopathy in chronic hepatitis C

The lymph nodes of the hepatoduodenal ligament are usually oval, 5-10/10-20 mm in size (Fig. 1.4). They are best visualized along the hepatic artery or along the portal vein.

Other ultrasonographic signs for chronic hepatitis are *non-specific* and *inconsistent*. A discrete hepatic heterogeneity (inhomogeneity) rather suggests liver cirrhosis than chronic hepatitis. The signs of hepatomegaly (particularly the “rounding” of the caudo-ventral liver margin) are non-specific. Liver steatosis can be identified in chronic alcoholic hepatitis or in NASH (increased hepatic echogenicity with or without acoustic shadowing [posterior attenuation]). The thickening or irregular trajectory of the bile ducts are both suggestive signs for cholestatic liver disease (sclerosing cholangitis).

The clinical examination is particularly useful in chronic liver disease. Palpation of the liver by an experienced doctor can bring relevant data on the liver size (hepatomegaly) and its consistence. The diagnosis of splenomegaly is made by ultrasound (much more objective than assessment by palpation).

The temporal diagnosis (evolution longer than 6 months), and the clinical and biological diagnosis of chronic hepatitis are followed by staging, mandatory both for prognosis and therapy. The staging can be performed using non-invasive methods or by *liver biopsy*.

The non-invasive methods for liver fibrosis assessment are:

- biological tests (such as FibroTest-ActiTest);
- ultrasound-based elastographic tests: Transient Elastography (FibroScan), point shear-waves Elastography (Siemens: VTQ - ARFI) and 2D-SWE (Aixplorer system), strain elastography (Hitachi);
- MRI elastography.

Ultrasound guided or ultrasound assisted liver biopsy (LB) is still widely used in the clinical setting. We prefer to perform LB under sedation with Midazolam (Dormicum), 2.5-5 mg/i.v., which induces conscious sedation, with retrograde amnesia. The biopsy site is localized using ultrasound (avoiding large vascular structures, cysts or hemangiomas), and is usually at the level of the middle axillary line, in the hepatic parenchyma. Subsequently, the biopsy will be performed without ultrasound guidance (ultrasound assisted LB). Some authors use the ultrasound guided technique, in which the needle attached to a “pistol” is guided into the liver in real time.

Ultrasound can be useful for assessing potential complications that can occur during biopsy: hemoperitoneum - anechoic or slightly hypoechoic image in the perihepatic space or in the Douglas pouch; subcapsular or intraparenchymal hematoma (anechoic/hypoechoic image under the liver capsule or within the parenchyma). The risk of complications after LB is relatively low and consists of a vagal response to puncture, hemoperitoneum, intrahepatic or subcapsular hematoma, transient subscapular pain.

In conclusion, ultrasound examination in chronic hepatitis has a *limited value*, only splenomegaly and hepatoduodenal ligament adenopathies being relatively constant elements (good sensitivity, but lower specificity). The other ultrasound signs are inconsistent.

The new methods used for the non-invasive evaluation of fibrosis (elastography or biologic tests) will probably be widely used in daily practice (as it currently happens in countries such as France).

3. LIVER STEATOSIS

Definition: fat buildup in the liver, which affects more than 10% of the organ. The main causes of liver steatosis are chronic alcohol abuse (alcoholic steato-hepatitis – ASH syndrome) and steatosis occurring in obese, diabetic patients and in dyslipidemic syndromes (non-alcoholic steato-hepatitis – NASH syndrome). Another etiology is chronic hepatitis C (up to half of the cases have mild steatosis).

From a *clinical* point of view, steatosis most frequently has no subjective symptoms. Exercise hepatalgia, rest hepatalgia, and moderate fatigue rarely occur.

Clinical examination reveals hepatomegaly, most frequently moderate, of increased consistency. The firm consistency of the liver on palpation suggests the possibility of steato-fibrosis (or even steato-cirrhosis). Evaluation using FibroScan or ARFI can be useful in these cases.

From an imaging point of view, steatosis can be divided into *diffuse liver steatosis* and *focal liver steatosis*.

Ultrasound examination is very reliable in the diagnosis of *diffuse liver steatosis*, in which a fatty loading of the liver higher than 10% will translate into an *increased hepatic echogenicity* - "bright liver" (Fig.1.5), frequently accompanied by *acoustic shadowing* (posterior beam attenuation), due to the partial absorption of ultrasounds by the fatty tissue. There is a direct correlation between the severity of fatty loading of the liver and the degree of acoustic shadowing. Thus, depending on the intensity of posterior beam attenuation, steatosis is subjectively categorized as mild (discrete attenuation), moderate (obvious attenuation), and severe steatosis (difficult or impossible to visualize the diaphragm).

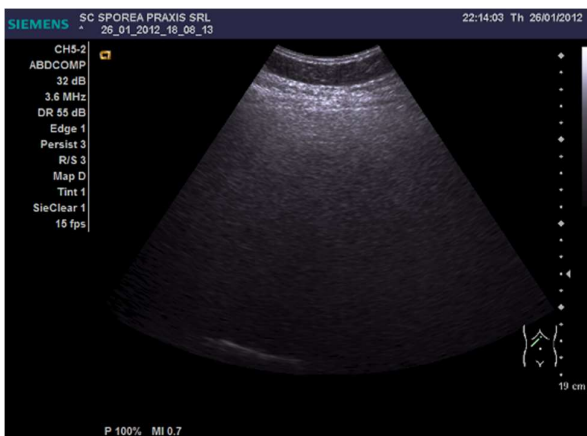

Fig. 1.5 Diffuse liver steatosis

The sensitivity of ultrasound in the diagnosis of liver steatosis is approximately 70-80%. Another imaging technique that can accurately assess steatosis is computed tomography (CT). This technique will allow the detection of increased liver density (the fat content of the liver can be evaluated). CT is a costly technique and also irradiant and thus not used for the sole assessment of liver steatosis.

Other ultrasound signs that can be observed in liver steatosis are hepatomegaly ("rounded" hepatic contours), increased liver diameters, reduced filling of the hepatic veins (due to compression by fatty liver tissue).

In *daily practice*, the examination will begin with liver palpation. After assessing the size (hepatomegaly) and consistency of the liver, an abdominal ultrasound will be performed, which allows assessment of both hepatomegaly and liver steatosis severity (based on ultrasound brightness and the intensity of posterior attenuation). After evaluating the body mass index (BMI) in order to assess the presence of obesity, other causes of steatosis should be investigated, using the data collected through anamnesis: alcohol consumption, association of diabetes mellitus or known dyslipidemia. Other relevant information can be obtained from biological data: gamma-glutamyl transpeptidase, blood glucose level (possibly glucose tolerance test) and lipids profile (particularly triglyceride values).

Liver steatosis can be simple (asymptomatic) or it can be accompanied by secondary hepatic injury (cytolysis). This is why, in case of steatosis, the clinician will investigate a possible increase in aminotransferases levels (possibly with an increased De Rittis ratio - GOT/GPT - if the etiology is alcohol abuse) and also the presence of anti-HCV antibodies (steatosis that can occur in chronic hepatitis C).

After assessing the severity of steatosis by ultrasound and after establishing its etiology, the patient should be informed regarding the available therapeutic measures (alcohol withdrawal, balancing diabetes, treatment of dyslipidemia, weight loss to achieve a normal BMI, moderate physical activity). A *quarterly reevaluation* of the ultrasound appearance of the liver should be performed, until the liver aspect returns to normal.

Focal hepatic steatosis is a particular case of fatty loading of the liver, characterized by lipid accumulation within the hepatocytes restricted to a certain area. Another possible explanation for focal steatosis is the fact that in a certain hepatic area, intrahepatocytic fat droplets have different sizes compared to lipid accumulations in other parts of the liver (resulting in a different ultrasound appearance). However, the explanation of excess lipid accumulation restricted to certain areas is currently not very clear.

The ultrasound appearance of *focal hepatic steatosis* is somewhat typical; it translates into a hyperechoic area of variable size in the liver. The background is also defined by steatosis, but in some cases, the rest of liver may present as normal on ultrasound examination. The area affected by focal steatosis generally is not clearly delimited (unlike delimitation in the case of hemangiomas).

Focal steatosis may occur without any objective cause, or it can be the consequence of long-term corticosteroid therapy. A particular case of focal liver steatosis is the focal fat accumulation in the hepatic hilum. It involves excess fat storage in a typical hepatic area, situated at the portal bifurcation. It is an oval shaped area, usually 3-4/2-3 cm in size, situated at the bifurcation of the portal vein, between its right and left branches. It has a hyperechoic appearance and is relatively well circumscribed. For an experienced ultrasonographer, the diagnosis is relatively easy, but differential diagnosis should be performed in order to exclude a hemangioma or a hepatic tumor of the hilum.

A particular version of steatosis is the presence of *fatty free areas* in a liver with steatosis. The US appearance is of a bright liver with posterior attenuation, which includes one or more hypoechoic areas (Figs. 1.6, 1.7) that actually are areas with normal echogenicity on the background of global steatosis. The etiology of fatty free areas is so far unknown.

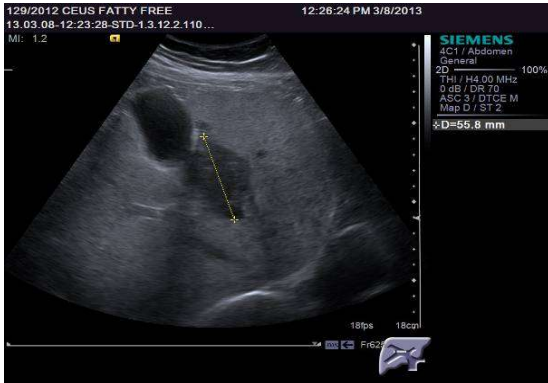


Fig. 1.6 Hypoechoic area – fatty free area

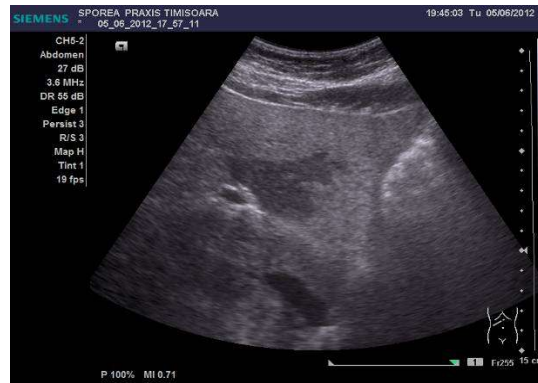

Fig. 1.7 Fatty free area

Fatty free areas may have various shapes and sizes, and in some cases they can affect an entire lobe. The hypoechoic hepatic area is sometimes less clearly delimited, while in other cases there is a clear delimitation between these areas and the normal hepatic parenchyma, through one of the hepatic veins.

The *ultrasound differential diagnosis* of fatty free areas is often difficult, because one must suspect a hypoechoic primary or secondary hepatic tumor occurring in a liver affected by hepatic steatosis. The ultrasound characteristics that can differentiate between the two diagnoses are not always clear and they usually require second line contrast imaging methods, such as contrast-enhanced ultrasound (CEUS). This technique will reveal the same enhancement pattern following contrast bolus in the focal steatosis, fatty free areas and in the adjacent hepatic parenchyma in all vascular phases (arterial, portal and late phase).

In cases of difficult differential diagnosis of focal steatosis or fatty free areas, when contrast-enhanced ultrasound has not answered the question (extremely rare cases), computed tomography can be used, which will easily differentiate areas with or without fatty loading.

Sometimes, focal steatosis areas (less commonly fatty free areas) can be spread into the liver parenchyma, causing hepatic inhomogeneity. Differential diagnosis in these situations is made with hepatocarcinoma and the multicentric form of metastatic liver. In these cases, the ultrasonographer's experience is the most important factor in diagnosis, possibly complemented by CEUS.

In conclusion, we can state that ultrasound is a good, non-invasive technique for assessing liver steatosis, as well as for the quantitative evaluation of steatosis (relatively well correlated with the histological fat loading of the liver). In cases with focal liver steatosis or fatty free areas, positive ultrasound diagnosis is easy, while differential diagnosis will require an experienced ultrasonographer, and sometimes, evaluation by CEUS.

4. LIVER CIRRHOSIS

Definition: liver cirrhosis is the final stage of most chronic liver diseases, in which fibrous changes occur in the liver alongside with necrosis and regenerative phenomena. Liver cirrhosis is considered to be an irreversible state of nodular transformation of the liver parenchyma.

The etiology of liver cirrhosis is varied, but alcohol abuse and hepatitis viruses B and C are the most frequently incriminated. Thus, in a study carried out for 3 years in the Department of Gastroenterology Timișoara regarding the etiology of liver cirrhosis, hepatitis C virus was the most frequent (33.4%), followed by alcohol abuse (30%) and hepatitis B virus (25.5%). It goes without saying that in some situations the etiology is multifactorial, the combination of a viral infection with alcohol abuse being extremely common. Liver cirrhosis is frequently found in alcoholics, and subsequently, the search for hepatitis viruses markers (HBs Ag, anti-HCV Ab and anti-HDV Ab) will sometimes lead to the identification of chronic hepatitis virus infection.

In addition to the major etiologies of liver cirrhosis (alcohol or hepatitis viruses), 5-10% of cases have rare causes, being secondary to: autoimmune cirrhosis, Wilson cirrhosis (ceruloplasmin deficiency), hemochromatosis, alpha-1-antitrypsin deficiency cirrhosis, primary biliary cirrhosis, drug-induced cirrhosis, and cryptogenic cirrhosis (a rare condition). Thus, in a group of 1200 liver transplants performed in Dallas, almost 10% were performed for cryptogenic cirrhosis. In our group (in an endemic hepatitis virus area), the frequency of cryptogenic cirrhosis is much lower, but this might be due to the fact that cirrhosis is too easily labeled as alcoholic when no other etiological factor can be determined (without taking into account the need for alcohol consumption in a toxic dose for a long enough time).

The diagnosis of liver cirrhosis starts with *the clinical examination*.

The inspection of the abdomen and chest can reveal collateral abdominal circulation (not a very specific sign) or the presence of spider angiomas (spider naevi) on the chest. "Spider naevi" are frequent in liver cirrhosis, so if they are correctly diagnosed (recognized), they represent a solid argument for the diagnosis. One should always inspect the chest for this sign in any chronic liver disease. Applying pressure makes them disappear, while if the pressure stops they will subsequently reappear, this being a criterion for differentiation of various vascular angiectasis.

Liver palpation provides significant clinical information. The patient in dorsal decubitus, with the knees slightly bent for the relaxation of the abdominal muscles, will be asked to perform deep inspiration-expiration movements, which will allow for an accurate liver palpation in order to assess the consistency of the liver. During deep inspiration, the liver will descend (pushed by the diaphragm) and will be easily accessible. Palpation will continue during expiration, when the clinician's hand will follow the margin of the withdrawing liver. After several inspiration/expiration movements, based on palpation, a doctor with good clinical experience will be able to assess if hepatomegaly is present or not, as well as the liver consistency (clinical elastography). We insist on the adequate and correct palpation of the liver, for this method is superior to certain imaging methods used in order to evaluate liver size.

Ultrasound examination in *liver cirrhosis* may reveal multiple changes, but in some cases it can be normal (in up to 20% of cases).

The typical elements that can be found in liver cirrhosis, but which are not necessarily present, are:

- caudate lobe hypertrophy;
- heterogeneous liver echotexture;
- splenomegaly;
- ascites;
- signs of portal hypertension;
- changes in the gallbladder wall.

Caudate lobe hypertrophy

The caudate lobe or the first hepatic segment suffers from hypertrophy in the evolution of liver cirrhosis; therefore it will be frequently enlarged in patients suffering from this condition. Several ways of evaluating the caudate lobe have been described; for example, the calculation of its volume or its relation with the size of the right hepatic lobe. Both methods are laborious and provide no additional diagnostic elements.

In current practice, the easiest method is to measure the anteroposterior diameter of the caudate lobe by means of ultrasound. In order to differentiate the anteroposterior diameter of the caudate lobe in healthy and cirrhotic subjects, we performed a prospective study which included 200 healthy subjects (126 women and 74 men). We aimed at correlating the size of the caudate lobe with the patients' gender, height, age and body mass index (BMI). The mean anteroposterior diameter in this group was 21.4 mm and we found that it was not influenced by patients' gender, age, height or weight.

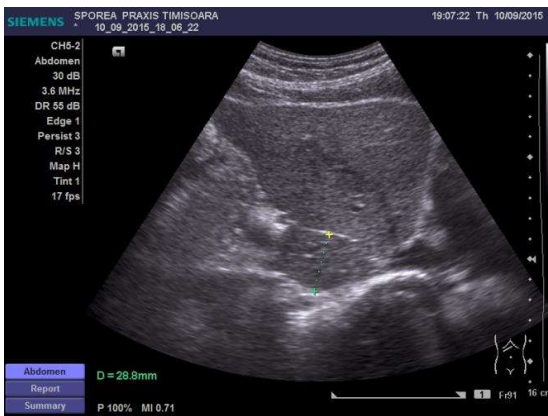

Fig.1.8. Normal caudate lobe

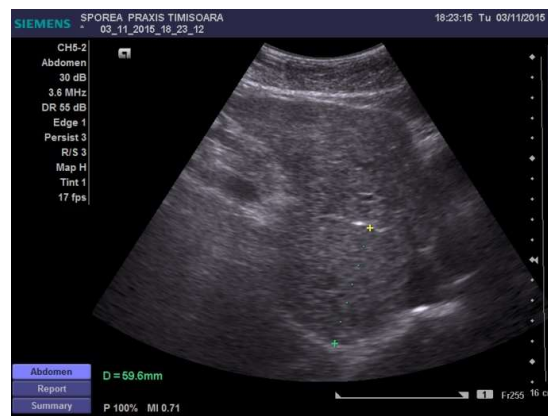

Fig. 1.9. Enlarged caudate lobe

By comparing these results with a group of 24 cases of known liver cirrhosis, we found that the mean diameter of the caudate lobe in cirrhosis was 47 mm ($p < 0.01$). These data led us to use the

caudate lobe hypertrophy as a sign of liver cirrhosis (Fig. 1.9). But which is the normal range? Based on a long ultrasound experience and personal studies, we consider the upper normal limit for the anteroposterior diameter of the caudate lobe to be 35 mm. However, there is an overlapping of normal and cirrhosis cases, so that we generally consider *a size of the caudate lobe greater than 40 mm as relevant* for cirrhosis (Figs.1.10, 1.11).

In current ultrasound practice, approximately 2/3 of cirrhosis cases have a hypertrophic caudate lobe; sometimes with a typical ultrasound appearance (a large, globulous appearance being particularly useful for diagnosis). The caudate lobe size will be used for the diagnosis of liver cirrhosis only in a well known clinical context.

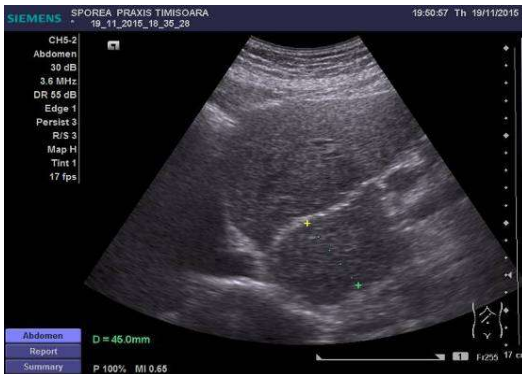

Fig. 1.10 Caudate lobe larger than 35 mm

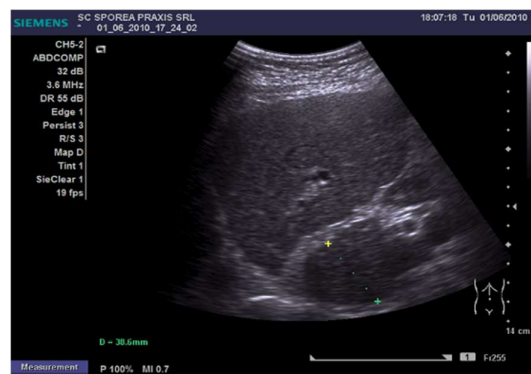


Fig. 1.11 Caudate lobe larger than 35 mm

The anteroposterior diameter of the caudate lobe should be measured in a sagittal section at epigastric level. The inferior vena cava (IVC) should be identified and the ovoid structure situated anteriorly is the caudate lobe. Subsequently, the maximum anteroposterior diameter of the caudate lobe should be measured. Measurement of the caudate lobe can be difficult in cases of marked steatosis (ultrasounds are strongly absorbed by fatty tissue) or, more rarely, in the case of ascites.

Heterogeneous liver echotexture

Liver echotexture changes, particularly hepatic heterogeneity occur in approximately half of cirrhotic cases (Fig. 1.12). Hepatic heterogeneity is the consequence of fibrous changes that lead to the formation of regenerative nodules. However, there are liver cirrhosis cases without imaging changes of the hepatic echotexture.

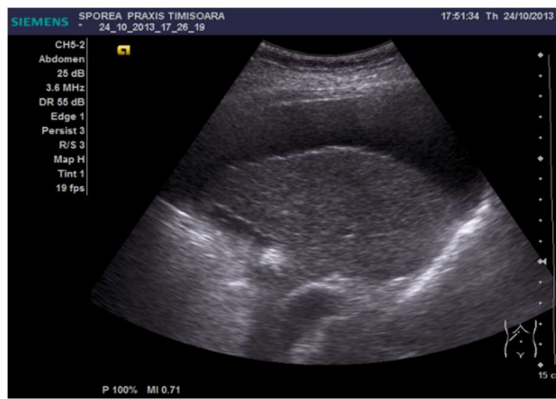


Fig. 1.12 Hepatic heterogeneity and irregular liver surface in ascites

We wish to insist on the use of “liver micronodulation” term in ultrasound description. Liver micronodulation is a histological reality in cirrhosis, but ultrasound cannot evidence these small nodules. The way to accurately diagnose hepatic nodules by ultrasound is to *evaluate the liver surface* in cases with ascites (Figs. 1.12, 1.13, 1.14). The anterior and, to a smaller extent, the posterior liver surface are easy to examine if ascites is present. Thus, nodules with a size of less than 5 mm in micronodular cirrhosis and more than 5 mm in macronodular cirrhosis can be seen. The examination of the liver surface in ascites is easier by using high frequency transducers (5-9 MHz) (Fig. 1.19). In ascites-free cirrhosis, it is almost impossible to notice liver surface changes.

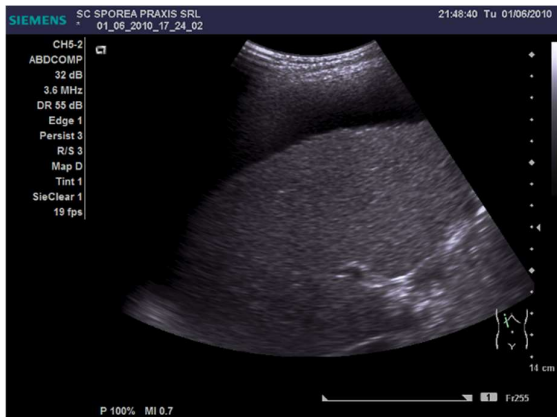

Fig. 1.13. Liver surface in ascites

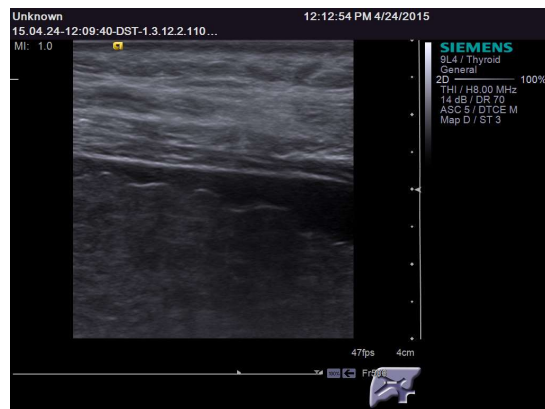


Fig. 1.14. Liver surface in ascites using high frequency transducers (5-9 MHz)

A particular situation in the ultrasonographic practice is that of routine ultrasound performed in a patient without a history of liver disease and without a particular clinical illness. If a change in the liver architecture (heterogeneity) is found, a possible cirrhotogenic liver disease should be suspected. Clinical, biological, and endoscopic examination, as well as elastography (FibroScan) can diagnose cirrhosis that was completely unknown before the ultrasound examination.

In cases with marked liver heterogeneity (which occurs particularly in advanced viral cirrhosis), differential diagnosis with diffuse hepatocellular carcinoma (HCC) is required. In these

cases, alpha-fetoprotein should be determined; values higher than 400 ng/ml are diagnostic for HCC.

Assessment of liver structure by ultrasound will carefully investigate the presence of hepatic areas with a rosette or hypochoic appearance, suggestive of HCC (Fig. 1.15). The possible development of HCC on a background of cirrhosis will be dealt with later in this book.

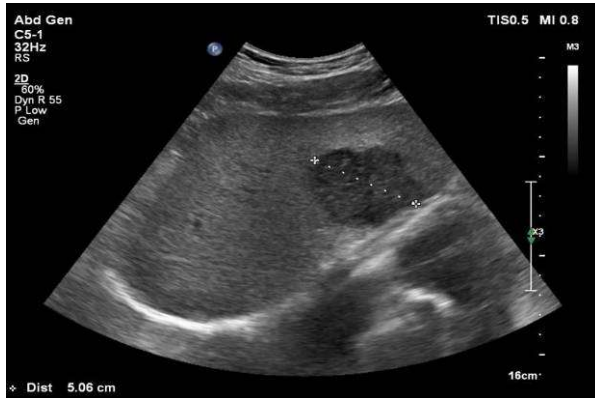

Fig. 1.15 Hypochoic area in a case of liver cirrhosis - HCC

The role of ultrasound in the evaluation of significant liver fibrosis should be emphasized. Transient elastography (FibroScan) and subsequently, other elastography techniques (2D-SWE, VTQ-ARFI or Hi RT-E) are methods that non-invasively assess liver fibrosis. Studies have shown that these methods are sensitive and specific for diagnosing chronic hepatitis with significant fibrosis ($F \geq 2$) or cirrhosis.

Splenomegaly

An enlargement of the spleen (over 12 cm long) is frequent in cases of liver cirrhosis (Figs. 1.16, 1.17). The spleen of a cirrhotic patient is larger than in chronic hepatitis, so that approximately 80% of cirrhosis cases are accompanied by splenomegaly, which frequently exceeds 15 cm. Sometimes, splenomegaly larger than 18 or even 20 cm can be found, which is often accompanied by hematological hypersplenism (thrombocytopenia $< 100,000/\text{mm}^3$ and/or leukopenia $< 3000/\text{mm}^3$ and/or anemia). In other situations, the increase in the long axis of the spleen is not necessarily very important, but the spleen has a globulous appearance, through the increase of its width and thickness. We must emphasize the importance of a correct measurement of the spleen along the long axis, especially for beginners in ultrasound.

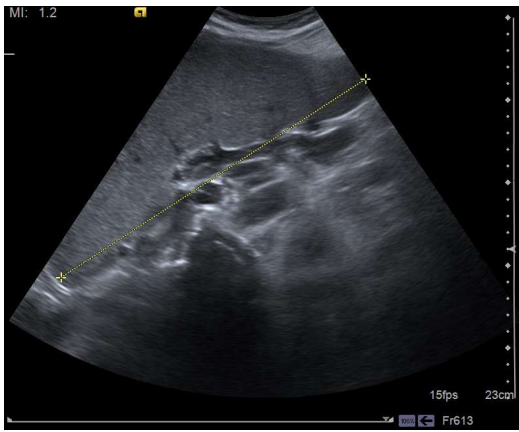


Fig. 1.16 Splenomegaly

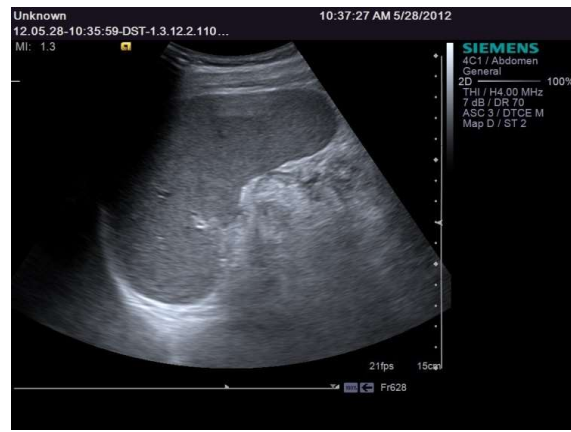


Fig. 1.17 Splenomegaly

We will present the clinico-biological correlations that we suggest using when splenomegaly is accidentally detected by routine ultrasound. Thus, splenomegaly is diagnosed if the long axis of the spleen is larger than 12 cm. Considering the statistical frequency of diseases with splenomegaly, the following clinico-biological approach to hepatic pathology should be initiated. One should search for a history of liver disease followed by clinical examination where liver palpation is essential (it will possibly demonstrate hepatomegaly and will assess liver consistency). Then, the patient will be evaluated using FibroScan, a method with a sensitivity of more than 90% for the diagnosis of cirrhosis. Biologic tests will include relevant targeted tests for the clinical suspicion. These are blood count and platelet count (for a possible hematological disease), aminotransferases (GOT and GPT as a specific sign of liver disease), and the markers of a chronic viral liver disease (HBs Ag and anti-HCV antibodies). If clinical hepatomegaly is absent, the aminotransferases are normal, the viral markers are normal, and the FibroScan values are less than 7 kPa, the hepatic etiology of splenomegaly can almost be excluded. In this case, hemolytic anemia, lymphoma, chronic myeloid leukemia and other hematologic causes of splenomegaly should be suspected and investigated.

Ascites

The presence of ascites is frequent in decompensated cirrhosis. Ultrasound is the ideal method for diagnosing ascites and evaluating its volume.

Considering that in Romania ultrasound is an inexpensive and repetitive method available to the clinician, it should always be used for assessing the presence and volume of ascites. The palpation and percussion of the abdomen for the evaluation of ascites is already of historical value, because we probably all had cases in which ascites was suspected following the clinical exam, but abdominal ultrasound showed no ascites (severe obesity, tumors or abdominal cysts).

Ascites should be investigated using ultrasound in the pouch of Douglas, in Morrison's pouch (inter-hepato-renal space), in the perihepatic (Figs. 1.18, 1.19) and perisplenic spaces. Ascites can be detected practically in any recess. It appears as an anechoic image that changes in form with the change of the patient's position.

Ascites may have two different ultrasound appearances: completely anechoic (Fig. 1.20, 1.21), and "dense" ascites. The latter can signify old ascites, protein-rich ascites, superinfected ascites, chylous or hemorrhagic ascites. "Dense" ascites does not have a completely anechoic appearance, but it is slightly hypoechoic and usually contains small echogenic particles (Fig. 1.22), subject to Brownian motion.

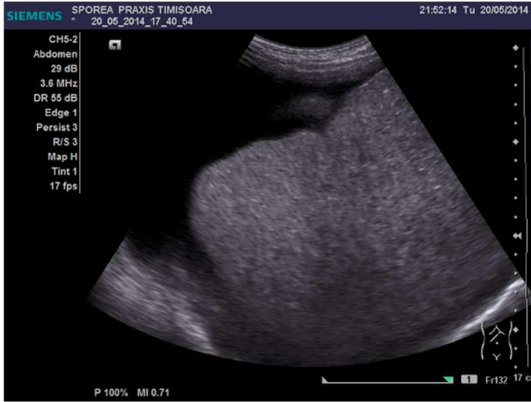

Fig. 1.18. Perihepatic ascites

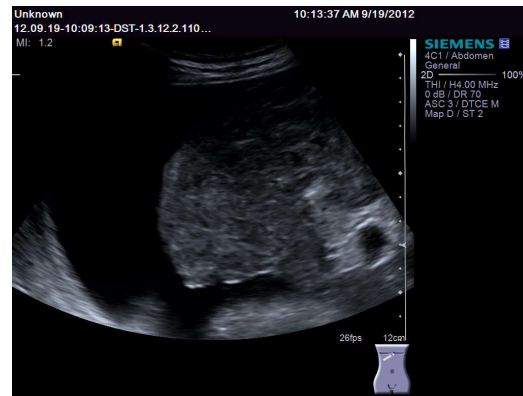

Fig. 1.19. Perihepatic ascites

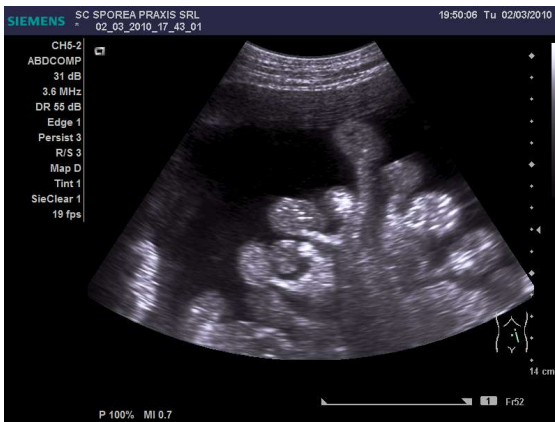

Fig. 1.20. Ascites

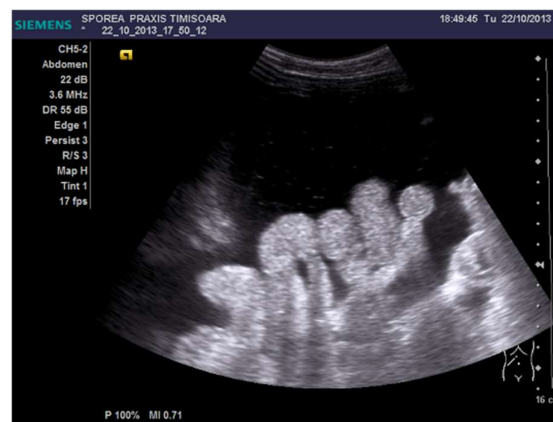

Fig. 1.21. Ascites

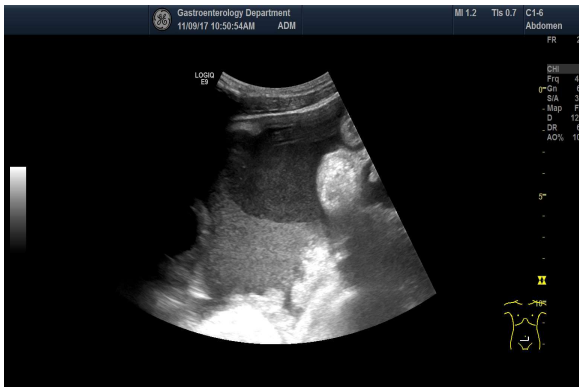


Fig. 1.22. "Dense" ascites

When "dense" ascites is identified, exploratory paracentesis is compulsory. It can assess the macroscopic aspect of the fluid (hemorrhagic or chylous), also allowing the evaluation of proteins concentration, and particularly of the number of leukocytes and polymorphonuclear cells/ml. It is considered that more than 500 leukocytes/ml or more than 250 polymorphonuclear cells/ml in the ascites fluid are signs of infected ascites (spontaneous bacterial peritonitis), even if the culture of the ascites fluid is sterile.

Exploratory paracentesis should be performed on the first evaluation of a patient with vascular decompensated cirrhosis or if the patient's general condition worsens. It can be performed in the classical manner, without ultrasound control, or, in the case of small ascites, with a thick abdominal wall, under ultrasound guidance. Protein content (exudate or transudate) and other pathological biological elements should be analyzed from the fluid extracted. In unexplained worsening of the clinical status of a patient with vascular decompensated cirrhosis, paracentesis is mandatory to diagnose a possible spontaneous bacterial peritonitis.

Ascites can be a sign of cirrhosis, but it is not always necessarily present.

In cases of cirrhosis with ascites, the subjective ultrasound evaluation of the ascites volume (minimal, small, moderate and large) is performed based on the amount of fluid in the Douglas pouch and in the perihepatic area. This evaluation, even if subjective, is useful from a therapeutic point of view, in order to establish the diuretic treatment doses and the general therapeutic approach. We consider that in minimal ascites, the amount of peritoneal fluid is approximately 1-2 l, in small ascites 3-4 l, in moderate ascites 7-8 l, and in large ascites more than 10-15 l.

Signs of portal hypertension (PHT)

One of the consequences of fibrosis in liver cirrhosis is the increased resistance to portal blood flow. The consequences of portal hypertension include collateral abdominal circulation, the opening of vascular shunts and the formation of varices most frequently located in the esophagus.

Portal hypertension (PHT) is the rule in liver cirrhosis, but it does not appear from the beginning and is not always easy to prove. If liver cirrhosis is suspected based on clinical signs, the abdomen should be inspected for collateral circulation (special attention should be paid to the possible confusion between collateral circulation and abdominal blood vessels that might be visible through the transparency of the skin). The next step is ultrasound assessment for portal hypertension signs. It starts with the assessment of the portal vein, by measuring its size in the hilum, considered to be normal up to a diameter of 13 mm. A *diameter of the portal vein greater than 13 mm* is a sign of portal hypertension.

However, based on a long ultrasound experience and personal studies, we demonstrated that there is always a correlation between the diameter of the portal vein and the severity of portal hypertension. Thus, in a group of liver cirrhosis cases without esophageal varices (the easiest way to assess portal hypertension), the mean diameter of the portal vein was 12.29 ± 2.12 mm. In patients with grade I esophageal varices, the mean diameter of the portal vein in the hilum was 13.63 ± 3.20 mm, in patients with grade II varices it was 14.42 ± 2.05 mm, while in patients with grade III varices, the mean diameter of the portal vein decreased to 12.80 ± 1.81 mm. This study showed that in the initial phases of portal hypertension, there is a linear correlation between the diameter of portal vein

and the endoscopic size of esophageal varices, but later, as portal hypertension worsens and the collateral esophageal veins (esophageal varices) open, the diameter of the portal vein decreases. Hence the practical finding that an increased diameter of the portal vein is a sign of portal hypertension, but the evaluation and quantification of PHT by upper digestive endoscopy is compulsory in any case of cirrhosis.

There is a small number of patients, particularly taller and heavier men, who may have normal anatomical portal vein variants with a diameter of up to 15 or even 16 mm. In these cases, the signs of chronic liver disease and PHT should be excluded.

An important sign of PHT is the *absence of inspiration/expiration variability of portal vein diameter* (Bolondi sign).

Another sign of PHT in liver cirrhosis is the *dilation of the intrahepatic portal system*. Its assessment is somewhat subjective, as there are no normal limits for its size.

Measurement of the preaortic *diameter of the splenic vein* and in the splenic hilum can provide additional elements for the diagnosis of PHT. Thus, splenic vein preaortic diameter greater than 10 mm and a hilum diameter greater than 8 mm are both signs of portal hypertension.

Other signs of PHT are *dilation of visceral veins* and the development of *venous shunts*. The detection of collateral epigastric circulation (dilatation of the gastric coronary vein) (Fig. 1.30), of spontaneous spleno-renal shunts or of splenic varices are typical signs of portal hypertension. An experienced ultrasonographer will find many signs of PHT in patients with liver cirrhosis that will contribute to the accurate diagnosis and staging of the disease.

Repermeabilization of the umbilical vein (Figs. 1.23, 1.24) is a severe sign of PHT and can be found in 10-20% of advanced cirrhosis cases.

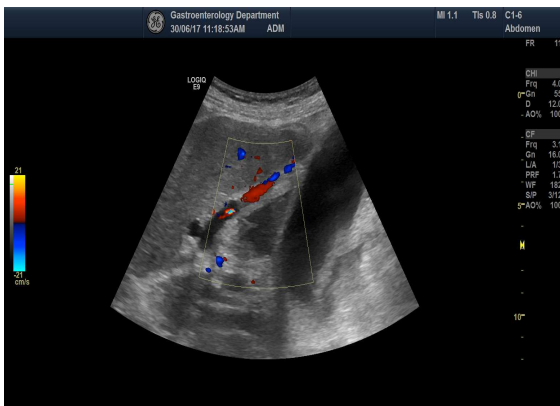


Fig. 1.23 Repermeabilisation of the umbilical vein

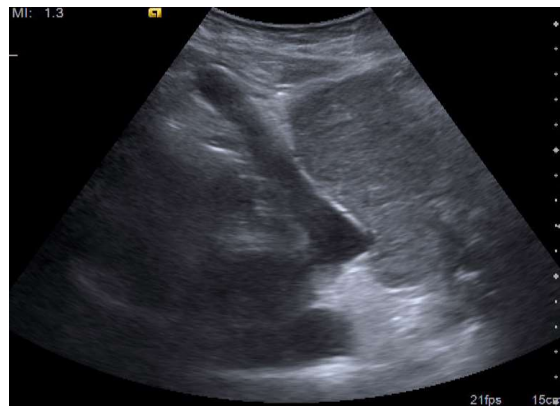


Fig. 1.24 Repermeabilisation of the umbilical vein

The repermeabilisation of the umbilical vein should be searched for starting from the left branch of the portal vein, where a vascular (venous) cord starts, continuing to the lower margin of the liver and then on the posterior face of the abdomen towards the umbilicus. The umbilical vein

with a diameter greater than 5 mm has a diagnostic value for PHT. Sometimes, the re-permeabilized venous cord has a 10-12 mm diameter. It is an internal correspondent of collateral abdominal circulation. In case of a doubtful diagnosis of permeabilized umbilical vein, a 5-9 MHz (surface) transducer and power Doppler can be used, which will facilitate the visualization of the venous flow.

Regarding PHT, we must mention the role of Doppler ultrasound for the assessment of cirrhosis. Thus, the evaluation of the flow direction in the splenic and portal veins proved to be useful for prognosis. Using pulsed Doppler, Bolondi demonstrated that in approximately 8% of cirrhosis cases, a reversed flow occurs in the portal and splenic veins due to opening of spontaneous venous shunts. At the same time, Bolondi has proven that flow reversals have a protective role, decreasing the risk of variceal bleeding.

Regarding the value of pulsed Doppler in the evaluation of portal pressures and flows, the results were disappointing (due to non-reproducibility of results). After years of studies in search of the best parameters to evaluate, current clinical practice no longer uses Doppler parameters for the evaluation of portal hypertension or of the risk of variceal bleeding.

Color Doppler or power Doppler are also useful for demonstrating the vascular character of some anechoic structures (e.g. extremely tortuous splenic varices) (Figs. 1.25, 1.26, 1.27) or for evidencing portal hypertension in patients with ascites. Combining power Doppler with pulsed Doppler will allow differentiating between a dilated tortuous hepatic artery (as is frequently the case in liver cirrhosis) and the portal vein or the common bile duct.

Power Doppler is also useful for the evaluation of the portal system in order to detect potential portal thrombosis (Fig. 1.28), which is less common in uncomplicated cirrhosis, but rather frequent in cases of hepatocellular carcinoma which complicates cirrhosis.

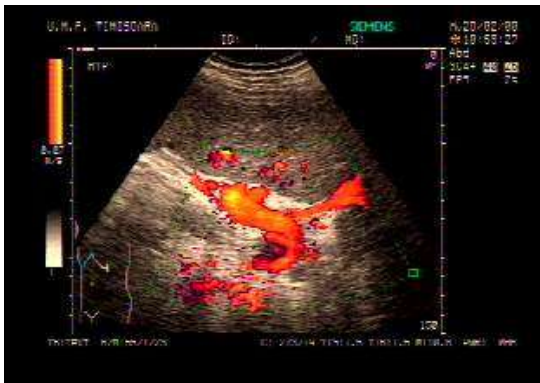

Fig. 1.25 Splenic varices using Power Doppler

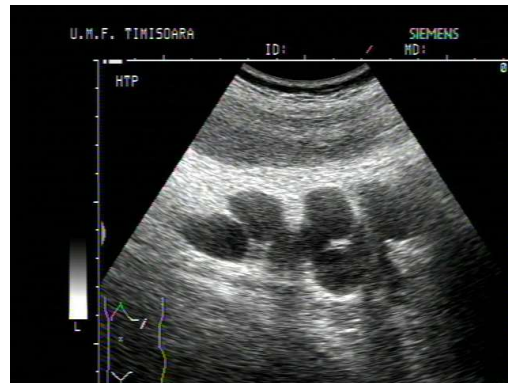

Fig. 1.26 Tortuous splenic varices

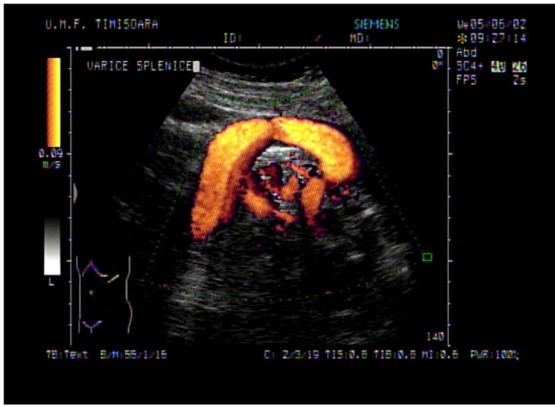


Fig. 1.27 Evidencing portal hypertension

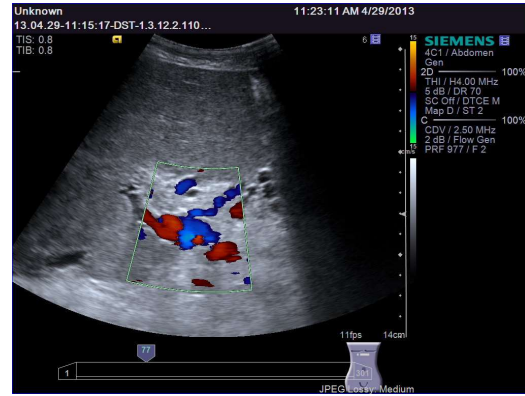


Fig. 1.28 Portal thrombosis using Power Doppler

It should also be mentioned that some studies have proven a relationship between the values of hepatic elasticity measured by FibroScan and the occurrence of complications in liver cirrhosis. Thus, liver stiffness values lower than 20 kPa are rarely associated with esophageal varices, while values higher than 40 kPa suggest an increased risk of variceal rupture. The annual monitoring of patients with cirrhosis using FibroScan allows the assessment of the relative risk of complications (PHT, ascites).

Changes in the gallbladder wall

Assessment of the gallbladder wall by ultrasound is part of the diagnosis in cases suspected to have liver cirrhosis. The normal size of the gallbladder wall is less than or equal to 4 mm, measured at the level of the anterior wall. There are two major situations in which the *thickening* and most frequently also *doubling of the gallbladder wall* occur: acute cholecystitis and liver cirrhosis. Acute cholecystitis is most frequently calculous and is accompanied by *sonographic Murphy's sign* (intense pain caused by pressing the ultrasound probe over the visualized gallbladder). In liver cirrhosis, the gallbladder wall can be thickened, reaching 6-8 or even 10 mm (Figs. 1.29, 1.30), most frequently doubled (with a "sandwich" appearance). Doubled gallbladder wall in cirrhosis is caused mainly by hypoalbuminemia (which is why it can also occur in nephrotic syndrome), and also by portal hypertension and lymphatic stasis.

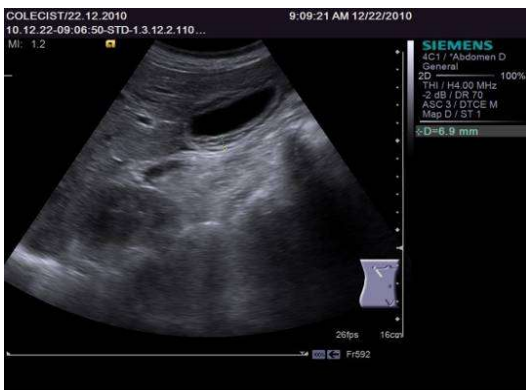

Fig. 1.29 Thickened gallbladder wall in a case of liver cirrhosis

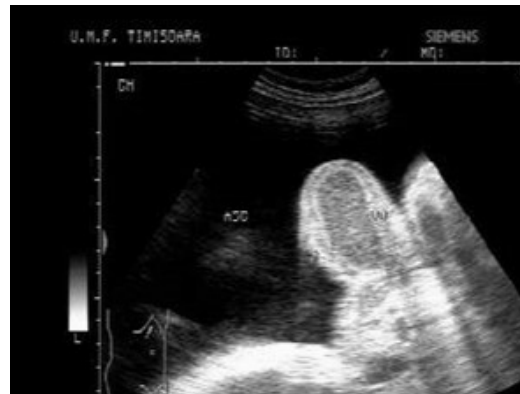

Fig. 1.30 Thickened gallbladder wall and biliary sludge in a case of liver cirrhosis

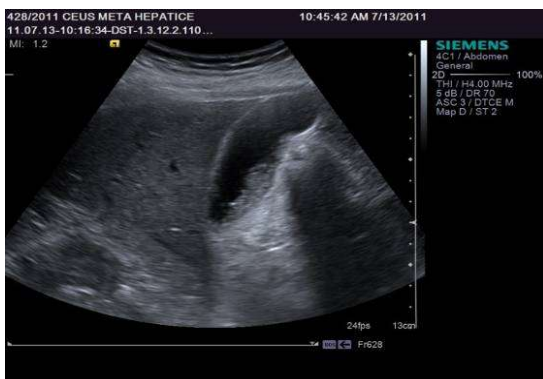In ascites of unknown etiology, the measurement of the gallbladder wall can differentiate between malignant or bacterial ascites, with normal gallbladder walls, from ascites due to liver cirrhosis, with a thickened, doubled gallbladder wall.

In one of our studies that included 62 patients with known liver cirrhosis who were compared to 12 patients with peritoneal carcinomatosis, we found that 52/62 (83.9%) patients with cirrhosis had a thickened gallbladder wall (5 - 15 mm, mean 6.45 ± 2.57 mm). Only 10 of the 62 cirrhosis cases (16.1%) had a normal gallbladder wall. In the 12 cases with peritoneal carcinomatosis (diagnosed by laparoscopy and morphology), the mean diameter of the gallbladder wall was 3.83 ± 1.27 mm (within normal limits). Based on this study and on published data, we may consider that the aspect and thickness of the gallbladder wall are the first ultrasonographic signs suggestive of etiology in ascites of unknown etiology.

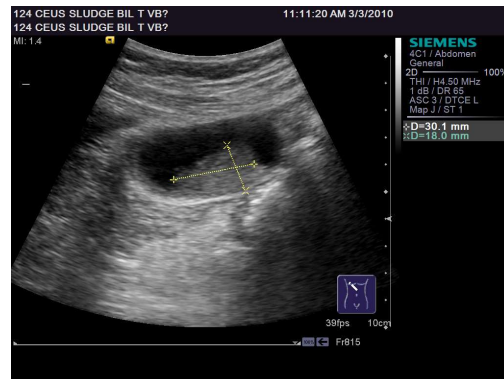
Another practical aspect that should be known is the association of liver cirrhosis with gallstones in approximately 1/3 of cases. They have a complex etiology, but their main cause is the impairment of conjugation of indirect bilirubin, which precipitates excessively. Detection of gallstones in cirrhosis is frequent, but most times they are asymptomatic, without requiring surgery.

The clinical decision is complicated in cases of gallstones in patients with cirrhosis and thickened gallbladder wall. Is it due to cirrhosis or is it an acute calculous cholecystitis? The answer is given by the clinical signs with intense colicky pain and possibly fever, and particularly by the positive ultrasound Murphy's sign (the pressure of the ultrasound probe on the gallbladder will cause intense pain), which all support the diagnosis of acute cholecystitis.

Another practical aspect related to the gallbladder and liver cirrhosis is the possibility to detect biliary sludge by ultrasound (Figs. 1.31, 1.32). Biliary sludge appears as a solid structure in the gallbladder, changing its position and shape with the patient's position. The cause of biliary sludge is most frequently biliary stasis. The causes, the ultrasound appearance, the evolution of biliary sludge will be discussed in the chapter on the "Ultrasound of the gallbladder" of this book.



Figs. 1.31 Biliary sludge



Figs. 1.32 Biliary sludge

We have reviewed the ultrasound changes that may occur in liver cirrhosis. In advanced cirrhosis all the described signs may be present, while in other cases only one them or none at all can be found, and in those cases the diagnostic value of ultrasound is extremely low.

What should we do if the clinical suspicion of cirrhosis is not confirmed by ultrasound? FibroScan (values higher than 14 kPa) or other types of elastography can be useful.

Considering the past difficulties in the diagnosis of liver cirrhosis in certain situations, we wish to discuss the results of a retrospective necropsy study performed in Timișoara County Hospital. Thus, over a 22 year period (1974-1995), of 6153 necropsy cases, 632 (10.3%) had macroscopic cirrhosis. 1/3 of cirrhosis cases were women and 2/3 were men. Of the 632 cirrhosis cases, 283 (44.8%) had the diagnosis of liver cirrhosis mentioned on the observation sheet before death, but 349 cases (55.2%) had unknown liver cirrhosis. These findings confirm the difficulties for encountered to accurately diagnose cirrhosis (before introduction of elastography techniques). In the group of patients who died of cirrhosis, the complications found on necropsy were the following: esophageal varices in 48.2% cases; upper digestive hemorrhage in 24.5% cases; ascites in 36.4% cases; jaundice in 10.9% cases.

Currently, FibroScan and other elastography techniques (VTQ-ARFI and 2D-SWE) as well as biological tests such as FibroTest are used for an accurate diagnosis. In unclear cases, liver biopsy or diagnostic laparoscopy should be used for a precise diagnosis.

We conclude the chapter on ultrasound examination of liver cirrhosis by stating that ultrasound is a good method for evaluating liver cirrhosis, both for confirming the diagnosis (with a sensitivity close to 80%) and for the assessment of complications (ascites, PHT or hepatocellular carcinoma).

5. HEPATIC VASCULAR DISEASES

In this chapter, two clinical entities will be discussed:

- cardiac liver (cardiac cirrhosis, congestive hepatopathy – part of congestive heart failure);
- Budd-Chiari syndrome.

Cardiac liver

Definition: liver changes due to vascular alterations and venous stasis in right-sided heart failure.

The clinical signs in this condition are somewhat typical: signs of right or global cardiac failure (hepatalgia, ascites, edema in right cardiac failure, and also dyspnea in global cardiac failure). The most frequent clinical situation will be that of a patient with firm, cyanotic peripheral edema, painful on palpation, and often with ascites. Usually, this is a patient with a known long history of cardiac or bronchopulmonary disease (chronic pulmonary heart disease).

Ultrasound examination in case of congestive hepatopathy reveals the following signs:

- *dilation of the hepatic veins* (Fig. 1.33) is typical in right or global heart failure. The hepatic veins become visible up to the periphery, and their branches are also visible on ultrasound (Fig. 1.34). This dilation can be quantified, a diameter of the hepatic veins larger than 10 mm, 2 cm from the junction with the inferior vena cava (IVC), being considered as pathological. The (normal) respiratory variability of the hepatic veins' diameter also disappears;

- *dilation of the inferior vena cava*, usually more than 20 mm in diameter (Fig. 1.35), but especially the absence of the normal inspiration/expiration variability.

- detection of *peritoneal effusion* is common, particularly in the Douglas space or in the perihepatic area;

- presence of *pleural effusion* is relatively frequent. It occurs as an anechoic crescent situated above the diaphragm (Fig. 1.36), which allows the differentiation from peritoneal effusion (fluid bellow the diaphragm). The volume of pleural effusion (small or large) can also be correctly assessed by an experienced ultrasonographer. The diagnosis of pleural effusion is easier to make on the right side (where the ultrasound window of the liver is used) (Fig. 1.36), than on the left side. At the same time, ultrasound can be successfully used for evaluating basal chest percussion dullness, allowing for differential diagnosis between pleural effusion (anechoic extra-diaphragmatic image) and pneumonia block. The value of ultrasound in the assessment of pleural effusion should not be overlooked, and this method should be used promptly in case of suspected pleural effusion.

- *pericardial effusion* appears as a anechoic area surrounding the heart (Fig. 1.37) and is variable in volume. We recommend in all cases of suspected pericardial effusion an echocardiographic examination, by which the cardiologist will confirm the diagnosis (there is a possibility of confusion between pericardial effusion and highly hypoechoic pericardial fat). Unlike pericardial fat, pericardial effusion changes with the patient's movements.

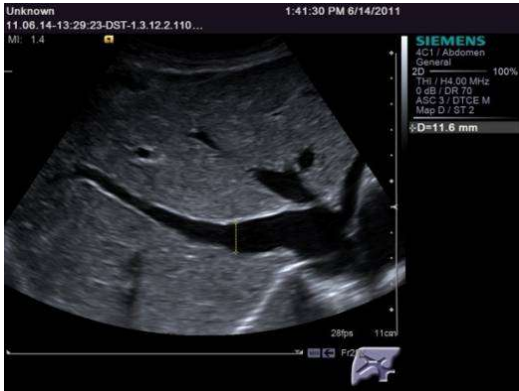

Fig. 1.33 Dilation of hepatic veins

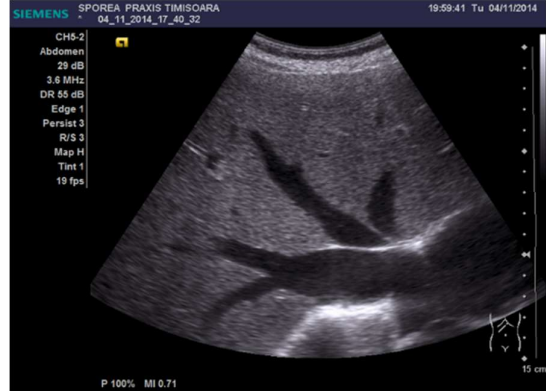

Fig. 1.34 Dilation of hepatic veins

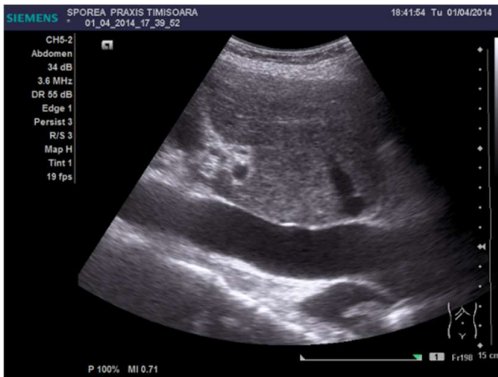

Fig. 1.35 Dilation of the inferior vena cava

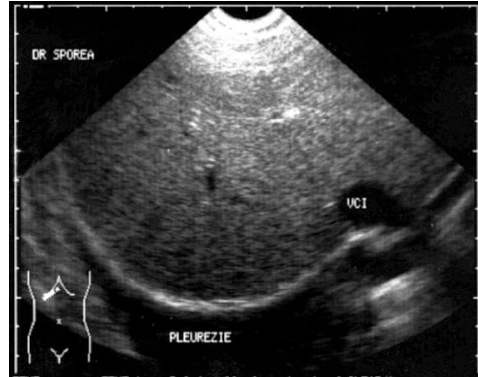


Fig. 1.36 Pleural effusion

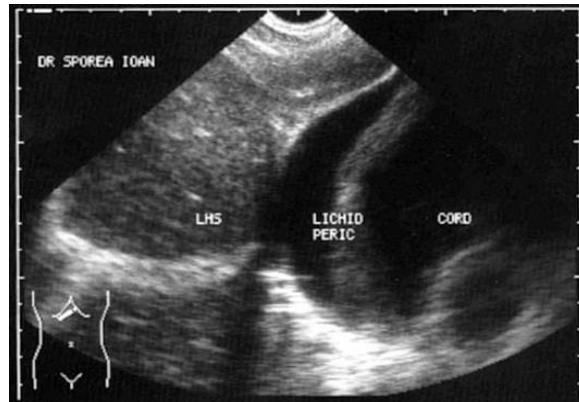


Fig. 1.37 Pericardial effusion

Pulsed Doppler examination may reveal relatively typical changes in patients with cardiac liver (high positive retrograde waves in the hepatic veins). Also, the examination of the portal vein using this technique will show a portal vein with pronounced undulations.

In current ultrasound practice, the cardiac disease is most frequently known and ultrasound only confirms the signs of cardiac liver. More rarely, ultrasonographic signs of cardiac liver are detected in a patient without known cardiac disease, who will be referred to the cardiologist for evaluation.

Budd-Chiari syndrome

Definition: a clinical condition characterized by thrombosis of hepatic veins (Fig. 1.38). It can be idiopathic, but it may occur in other situations as well: coagulopathies, myeloproliferative diseases, neoplastic conditions. Clinical diagnosis can be suspected in the presence of edematous syndrome and hepatalgia with sudden onset (sometimes in a young person).

Ultrasound diagnosis is made by absence of partial or total visualization of the hepatic veins. Thus, visualization of the hepatic veins excludes the diagnosis of Budd-Chiari syndrome. In case of doubt regarding hepatic veins, Power Doppler or color Doppler should be used, which will show or not the venous flow. In uncertain cases, a contrast agent (SonoVue) can be injected to better visualize vascular structures and reveal the presence or absence of flow in hepatic veins.

More rarely, ultrasound will detect partial thrombosis of a hepatic vein. This translates into a solid like structure in the vascular lumen. Also, the presence of thrombosis of the inferior vena cava can be detected by accident or in a clinical context (most frequently in renal or hepatic cancers).

Another rare condition is *hepatic veno-occlusive disease*, which is the consequence of the occlusion of the small hepatic veins with secondary hypoxic liver injury. It may occur after chemotherapy with high doses of cytostatics, after radiation therapy, after liver or bone marrow transplantation. *Ultrasound* does not show typical changes, only signs of portal hypertension, portal thrombosis (possibly with the subsequent appearance of portal cavernoma), thickening and doubling of the gallbladder wall may be found.

If venous thrombosis (hepatic veins, inferior vena cava) is suspected, CEUS is useful for diagnosis.

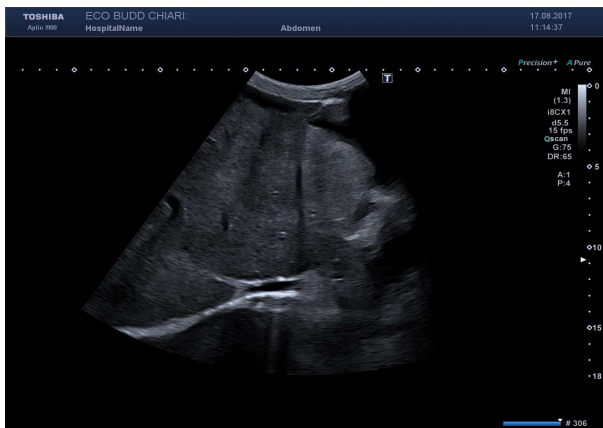

Fig. 1.38 Budd-Chiari syndrome

B) DIAGNOSIS OF FOCAL LIVER LESIONS

1. CYSTIC (LIQUID) LESIONS

This chapter will deal with the following: simple liver cysts, biloma, polycystic liver and hydatid cyst.

Simple liver cysts (or biliary cysts)

Definition: simple liver cysts are non-parasitic, benign entities, relatively common in clinical practice (1-3% of the ultrasounds performed). They are most frequently incidental ultrasound findings (incidentalomas). Their cause is the lack of communication of the bile ducts with the biliary tree.

The *clinical signs* in simple liver cyst are generally completely absent. Detection is usually incidental. Very rarely, large cysts with intracystic hemorrhage can generate symptoms, such as discomfort or pain in the right hypochondrium. However, once diagnosed, liver cysts may cause symptoms, particularly in patients with cenestopathic neurosis, who, knowing the diagnosis of liver cyst, will hold it responsible for some dyspeptic symptoms or functional pain in the right hypochondrium or flank (irritable colon-like). In this case, the patient must be assured of the benign character of the liver cyst, of the lack of danger and complications, which will usually lead to symptoms relief.

Liver palpation generally reveals a normal liver, but hepatomegaly may be found in some cases. Rarely, large cysts, close to the liver surface, can be palpated.

The ultrasound appearance of simple liver cysts is relatively typical, as *anechoic structures* with a very thin wall (Figs. 1.39, 1.40, 1.41). The cysts have a round or oval shape, generally 1-5 cm in size. Their size can exceed 5 cm (Figs 1.43, 1.44), reaching up to 15 cm. The outline of the cyst may be clear-cut or irregular (generating a "geographical" aspect of the outline) (Fig. 1.42). In general, the cyst is completely anechoic and displays "*posterior enhancement*"(Figs. 1.45, 1.46). This posterior enhancement is typical of all liquid structures and is due to the acceleration of ultrasound speed when passing from a solid environment (the liver) to the liquid environment of the cyst. It appears as a discretely echogenic band behind the cyst.

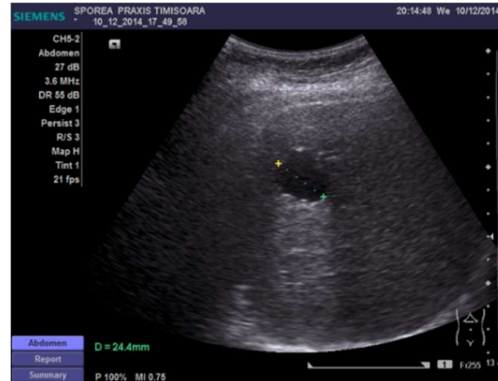
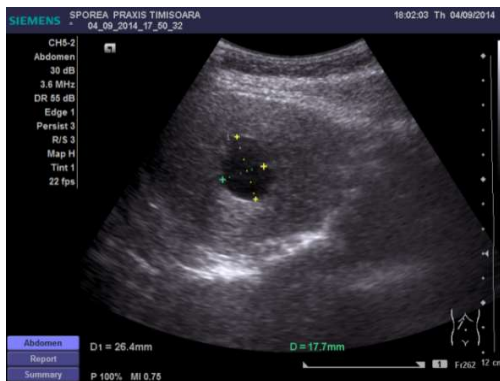
Fig. 1.39; Fig. 1.40 Anechoic structure with thin wall and posterior enhancement – simple liver cyst

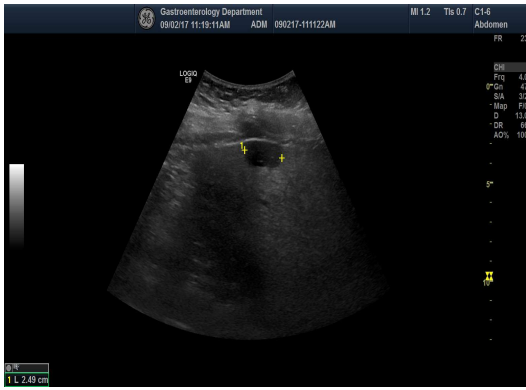


Fig. 1.41 Anechoic structure with thin wall, simple liver cyst

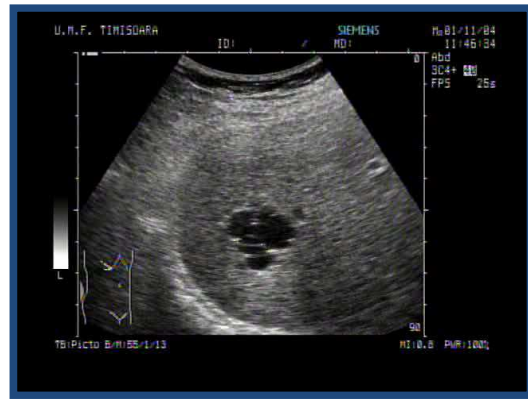


Fig. 1.42 Anechoic mass with thin wall and "geographical" aspect of the outline, simple liver cyst

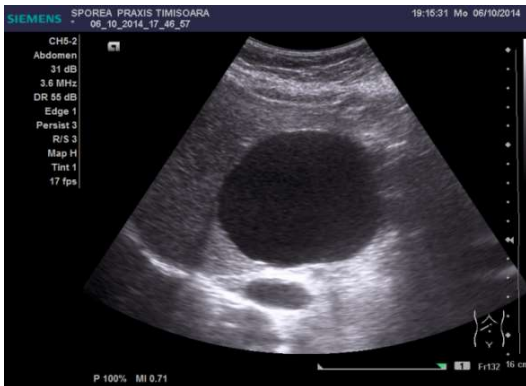

Fig. 1.43 Anechoic structure with thin wall, simple liver cyst larger than 5cm

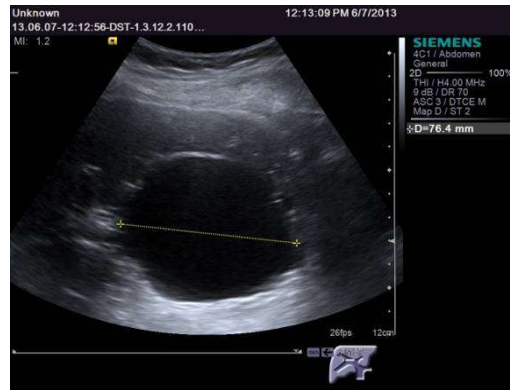


Fig. 1.44 Anechoic structure with thin wall and posterior enhancement, - simple liver cyst 76 mm in diameter

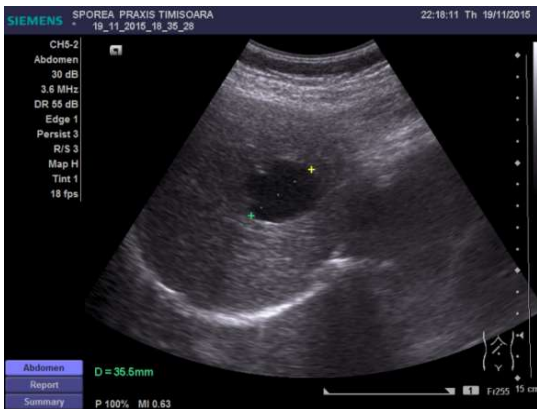

Fig. 1.45 Posterior enhancement - liver cyst

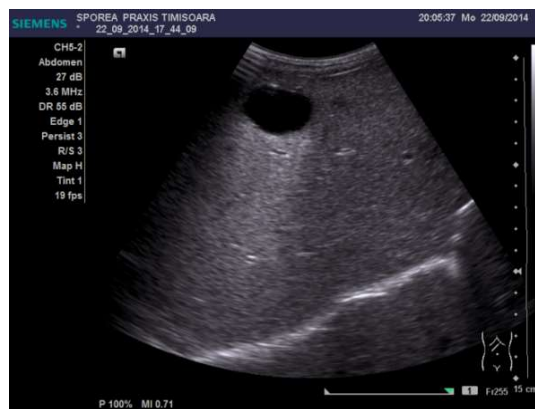

Fig. 1.46 Posterior enhancement - liver cyst

More rarely, simple liver cysts can have fine septa inside. When inner septa are present, particularly if the cyst has a thick wall, differential diagnosis with a hydatid cyst should be made.

The ultrasound differential diagnosis of a liver cyst should be made firstly with a hepatic hydatid cyst - a relatively frequent condition in Romania, which is an endemic area for this disease. Other differential diagnoses that should be taken into consideration are: biloma - usually posttraumatic or post-surgery; polycystic liver - the oligocystic pattern; hepatic hematoma - posttraumatic or after liver biopsy; dilated intrahepatic bile ducts, or main biliary duct cyst - often an extremely difficult differential diagnosis, made by MRCP.

We must advise the ultrasound beginners to avoid a possible trap: the first anechoic (cystic) lesion seen by ultrasound is generally the gallbladder. After detecting and examining the gallbladder in a non-cholecystectomized patient, if another anechoic image is detected, this will be considered a cyst. Otherwise, a gallbladder seen in a transverse section will generate an image similar to the one of a liver cyst.

However, in current practice, the most difficult differential diagnosis of simple liver cysts is with hydatid cysts. In these cases, searching for anti-Echinococcus granulosus antibodies will allow the differentiation. It is important to determine these antibodies in a high performance laboratory (where 2 or even 3 techniques are used, ELISA, RIA or RFC) in order to be sure that a correct result is obtained. The Cassoni intradermal reaction is completely outdated and is no longer used in the medical practice.

In rare situations, liver cysts can be complicated by intracystic hemorrhage, possibly posttraumatic or spontaneous (the cyst may change from anechoic to hypoechoic). Another possible complication that is exceptionally rare is the cyst's superinfection, which clinically manifests through fever, chills and pain in the right hypochondrium. On ultrasound, the anechoic image inside the cyst will show debris and can become hypoechoic or inhomogeneous.

Since simple liver cysts are asymptomatic and with no risks for complications, they are "leave me alone lesions". They should be periodically monitored by ultrasound for possible growth (first biannually, then annually or even more rarely). The patient will be assured that the lesion is benign and that there is no risk of complications.

In the rare case of a symptomatic cyst, ultrasound guided therapy may be used. Ultrasound guided puncture with thin 0.6-0.7 mm needles, followed by evacuation is performed under conscious sedation with Midazolam. The tip of the needle appears as a hyperechoic point inside the lesion, back and forth movements will facilitate its recognition. The fluid extracted is usually clear or more rarely slightly brownish (in case of old hemorrhage). If the liquid is bilious, biloma or communication with the bile ducts should be suspected (in order to elucidate the bilious content, bile pigments can be evidenced in the fluid – revealing communication with the bile ducts). After the needle has penetrated the cyst, its content is aspirated under ultrasound guidance with a 100 ml syringe until the disappearance of the anechoic content. For differential diagnosis with hydatid cyst, scolexes should be searched for in the fluid by microscopic examination.

Usually, hepatic cysts that have been merely aspirated will recur. To prevent it, cyst sclerosis with absolute alcohol can be performed, but only if no communication with the bile ducts is present, otherwise, bile duct sclerosis will occur. Communication with the bile is checked for by searching for bile pigments in the extracted fluid - a clear, transparent fluid suggests absence of communication with the bile ducts. The injected alcohol will be left in the cyst for approximately 10

minutes, after which it will be completely aspirated out of the cystic lesion (the amount of the extracted fluid amount should be measured as well as ultrasound control - absence of anechoic area should be performed). In most cases, after sclerosis the cyst will not recur. As a general rule, percutaneous therapy of simple liver cysts is required in only in exceptional cases, in persistently symptomatic cases.

Biloma

Definition: it is an intra- or perihepatic bile accumulation. It occurs posttraumatic, postoperatively or post-ERCP (endoscopic retrograde cholangio-pancreatography).

Clinical symptoms can be absent or mild: discomfort in the right hypochondrium, sub-fever. It is frequently an incidental imaging finding.

The ultrasound appearance is that of an anechoic collection, lacking a wall (Fig. 1.47) (it resembles a simple liver cyst). Usually there are no echoes inside the anechoic image, except in the case of hemobilia. When a biloma is suspected, a therapeutic decision must be made. Ultrasound guided aspiration of the fluid with a fine needle is preferred. The fluid aspirated has a bilious appearance (greenish) and contains bile pigments. Most frequently, the therapeutic aspiration of the bile from the cavity is sufficient. Sometimes, there is a recurrence of the fluid collection, which requires reaspiration or ultrasound guided percutaneous drainage, or even surgery to resolve the cause of biloma (bile"leakage").

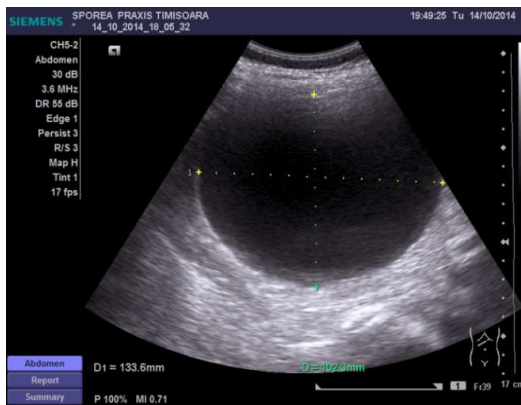


Fig. 1.47 Anechoic collection after cholecystectomy - biloma

Polycystic liver

Definition: a congenital disease characterized by the presence of multiple simple cysts in the liver.

Polycystic liver (Figs. 1.48, 1.49) is frequently associated to polycystic kidneys (Fig. 1.50). In order to see the frequency of association of the two disorders, we carried out a retrospective study in the Department of Ultrasound of the Timișoara County Hospital, over a period of 11 years. Based on a total number of 63453 ultrasounds, we identified 130 patients with polycystic disease (0.20%). In 30.8% of the aforementioned patients, polycystic liver was associated with polycystic kidneys, in 9.2% of cases we identified polycystic liver as single pathology (without renal involvement), and in

60.0% of cases we only identified polycystic kidney disease (without liver involvement). In conclusion, the association of polycystic liver with polycystic kidneys occurs in approximately 1/3 of the cases with polycystic disease, while in 1/10 of the cases, only liver polycystic disease occurs.

The clinical symptoms in polycystic liver are most frequently discrete or absent so that the disease is usually detected on a routine ultrasound. Some patients experience pain in the right hypochondrium, varying from mild discomfort to quasi-permanent pain. Occurrence of complications such as intracystic hemorrhage can exacerbate the symptoms.

The ultrasound appearance of polycystic liver is relatively typical, translating into multiple round or oval anechoic images (Figs. 1.48, 1.49), of variable sizes, from 1 to 5-10 cm. There are cases of polycystic liver with a smaller number of cysts (5-20), which can even be counted - the oligocystic form. In other cases, there are an impressive number of cysts, which almost completely replace the normal liver structure. In current practice, the oligocystic form of polycystic liver is the most common, usually completely asymptomatic. On ultrasound, the cysts will have a completely anechoic appearance, but sometimes internal septa can be found.

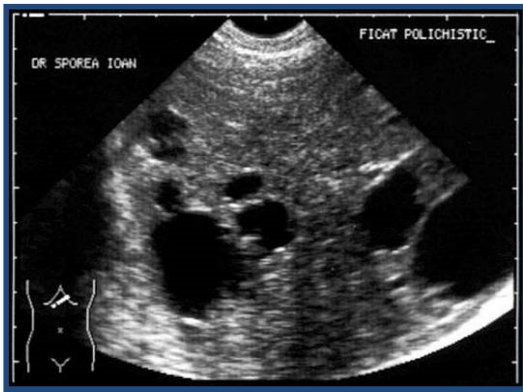


Fig. 1.48 Polycystic liver

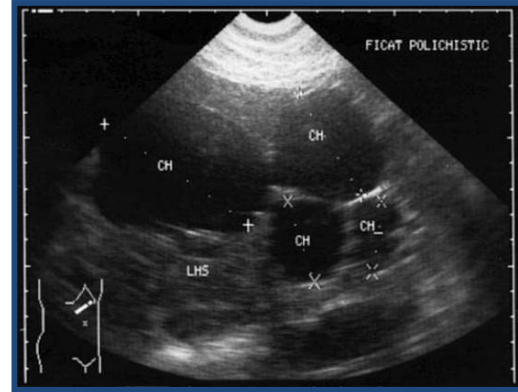
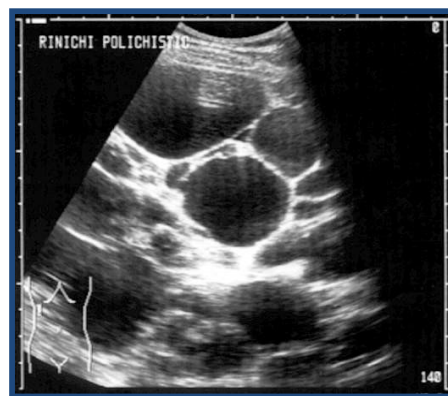


Fig. 1.49 Polycystic liver



Figs. 1.50 Polycystic kidney

The anechoic appearance of the cysts will change to hypoechoic in case of intracystic hemorrhage (which is sometimes possible) or of superinfected cyst.

Between the anechoic liver cysts, hepatic parenchyma appears as normal. Vascular displacement due to cysts is less common.

The ultrasound aspect of polycystic liver is relatively typical, differential diagnosis being made rather in theory with giant septated hydatid cysts or liver abscess, Caroli disease, or rare cases of multiple necrotic liver metastases.

It should be known that the evolution of polycystic liver is completely benign, unlike of polycystic kidneys. In time, no signs of liver failure occur, and complications are exceptional (intracystic hemorrhage). The patient should be assured of the lack of risk of his condition, ultrasound monitoring can be recommended annually or when new symptoms occur. Biological liver function tests are usually not needed, rarely discrete cholestasis is present (increased alkaline phosphatase, gamma-glutamyl transpeptidase and, even rarely, increased bilirubin) in the case of large multiple cysts that compress the bile ducts.

Polycystic liver does not require treatment. In the case of symptoms generated by the increase of pressure in some cysts or by intracystic hemorrhage, cyst decompression can be performed using a fine needle under ultrasound guidance (0.6-0.7 mm needles).

Hydatid liver cyst

Definition: it is a parasitic cyst generated by the *Echinococcus granulosus*. There are endemic areas for this disease such as the Mediterranean Region, Argentina, and the Balkan region. Endemic areas generally correspond to the regions where herbivorous (particularly sheep) are raised. So, Romania is situated within an endemic area for this pathology, which is why this disease is frequently found at a routine ultrasound and in the day to day medical practice. The most frequent location of hydatid cyst is in the liver (in approximately 60% of cases), followed by the lungs (approximately 20%), while the rest of the locations are rare.

The way of infection is by involuntarily swallowing parasite eggs (dirty hands, incompletely washed vegetables), after which they penetrate the intestinal wall and, through the portal blood flow, the parasite reach the liver where cysticerci develop in most cases.

Due to possible complications that are often severe (anaphylactic shock) and require difficult surgical approaches, with frequent postoperative recurrences, the hydatid cyst is often a disabling disease.

The clinical symptoms of hydatid cyst are non-specific. Very frequently, it is completely asymptomatic, being incidentally detected on ultrasound. Sometimes, patients complain of discomfort or intense pain in the right hypochondrium. Allergic reactions are not frequent, varying from a rash to allegrodermia or even anaphylactic shock (generally in ruptured hydatid cyst).

The ultrasound appearance of hydatid cyst varies depending on the cyst's age. Its main characteristic is the thick, well delimited cyst wall (Fig. 1.51), often with thick septa inside (Fig. 1.52). The thick cyst wall is formed by the germinal membrane and by the laminated layer (liver tissue compressed by the cyst's development). The germinal center (protoscolexes) can be sometimes identified as a polypoid endomembrane structure of 0.5-1 cm. The daughter vesicles will

determine the septated aspect of the cyst (Fig. 1.53). These ultrasound features differ from one cyst type to another.

Two main **classifications** of hydatid cyst are used, one by *Lewall and Mc Corkell*, which is simpler and divides hydatid cysts into 3 types depending on their aspect. The other classification, more complex, divides the ultrasound appearance of hydatid cyst into 5 types and belongs to *Gharbi*.

The classification of hepatic hydatid cyst according to *Lewall and Mc Corkell* includes the following characteristics:

- **Type I** – completely anechoic, with a well defined wall, with no echoes inside (Fig. 1.54);
 - subtype IR – hydatid cyst with a detached germinal layer; on ultrasound it will appear as an echogenic floating band inside the cyst, (it can occur spontaneously or following therapy) (Fig. 1.55);
- **Type II** – hydatid cyst with daughter vesicles (Fig. 1.56) or with hydatid matrix (Fig. 1.57). On ultrasound, the daughter vesicles will confer a multiseptated aspect, with thick septa, or with other cystic structures inside the cyst. The hydatid matrix (which is a gelatinous structure resulting from the dehydration of hydatid fluid) has a hypoechoic or solid like appearance, but the delimitation of the cyst's wall is obvious;
- **Type III** – old hydatid cyst, most frequently calcified (Figs. 1.58, 1.59). Calcification appear as highly hyperechoic areas in the hydatid wall (possibly with "posterior shadow"). Sometimes cyst calcification is so intense that ultrasounds cannot penetrate, resulting in a shell aspect ("the shell sign" – a highly echogenic band that generates a marked posterior shadow).

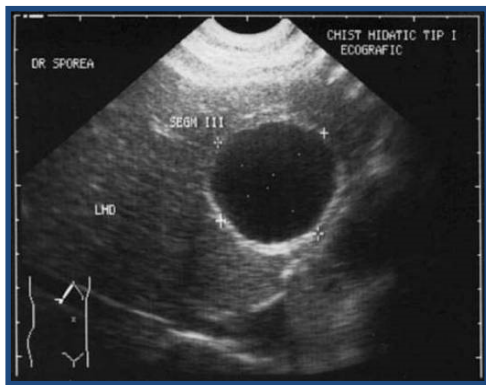


Fig. 1.51 Hydatid cyst with thick wall

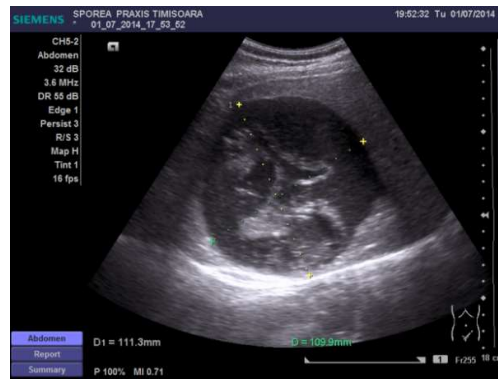

Fig. 1.52 Hydatid cyst with thick septa

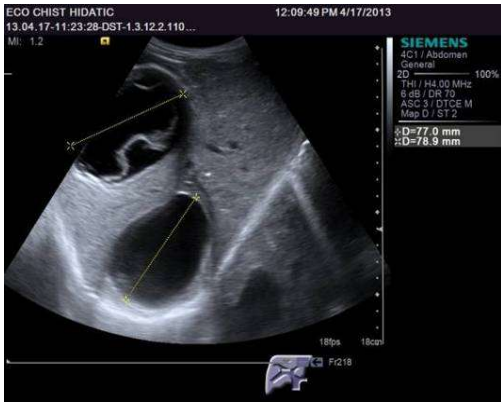

Fig. 1.53 Hydatid cysts

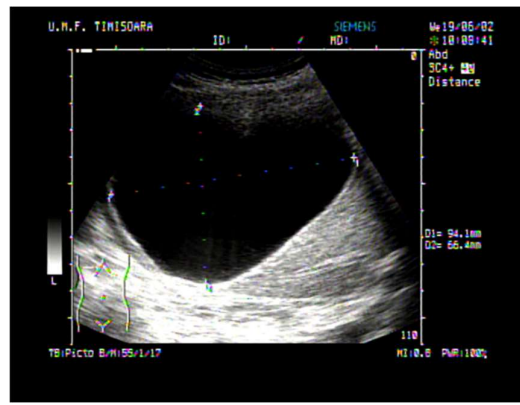


Fig. 1.54 Hydatid cyst type I

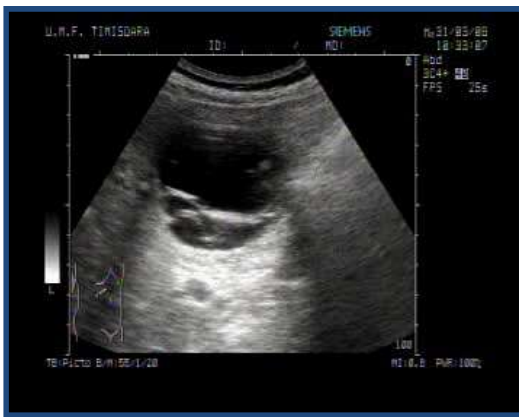

Fig. 1.55 Hydatid cyst subtype I R

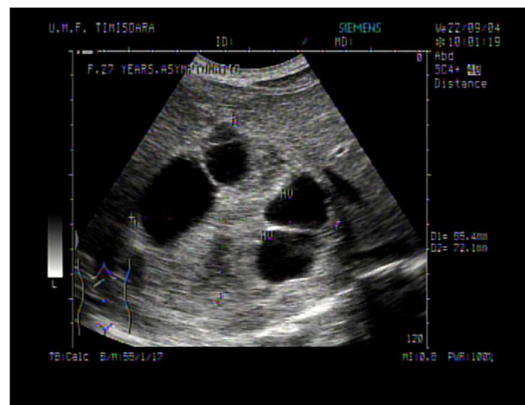

Fig. 1.56 Hydatid cyst type II containing daughter vesicles

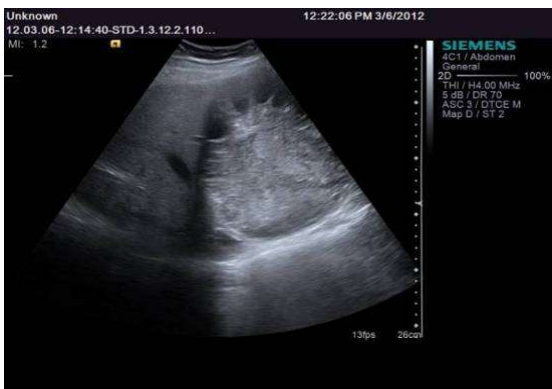

Fig. 1.57 Hydatid cyst type II that contains hydatid matrix

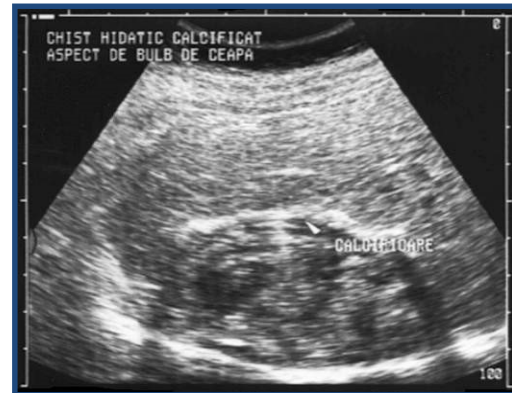

Fig. 1.58 Hydatid cyst type III - calcifications of the cystic wall

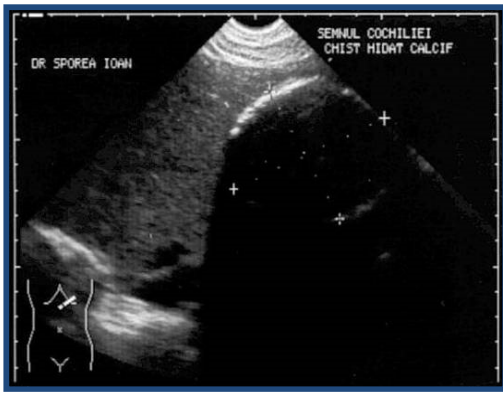


Fig. 1.59 Hydatid cyst type III – calcified cystic wall – the “shell” sign

Gharbi's classification divides the same ultrasound aspects into 5 types:

- Type I – anechoic hydatid cyst;
- Type II – hydatid cyst with a detached endomembrane;
- Type III - hepatic hydatid cyst with daughter vesicles (inner septa);
- Type IV – cyst with inner hydatid matrix (hypoechoic aspect of the content);
- Type V – calcified hydatid cyst (hyperechoic wall with posterior shadow).

Of the two classifications, the one belonging to the Anglo-Saxon school (Lewall and Mc Corkell) is brief and synthetic, while the other, belonging to the Francophone School, is explicit and more complex. Either of the two can be used, but it is preferable to mention on the ultrasound form which classification has been used.

We will address *differential diagnosis* problems regarding each of the hydatid cyst type that can be found in current practice.

A completely anechoic hydatid cyst must be differentiated from a simple cyst. The main characteristic that should be monitored is the cyst wall, relatively thick in hydatid cysts (1-2 mm), well seen by ultrasound. Then, the “sensation of tension” in the case of hydatid cyst, while hepatic cyst has a less clear-cut outline (“geographical outline”). The hydatid cyst wall frequently has a lamellar appearance (germinal membrane + hepatic tissue displaced by the cyst growth), while in the simple cyst the wall seems to be absent. The differentiation of type I cyst from biloma should also be made.

In cases requiring differentiation between various cyst structures, when ultrasound does not offer a clear answer, the anti-*Echinococcus granulosus* antibodies should be evaluated. If Elisa II tests are used, the sensitivity is about 90%, while for Immunoblotting sensitivity increases to approximately 97% (thus, the laboratory testing the samples and the type of tests are both extremely important). Authors from endemic areas (consequently, with a great clinical and imaging experience) recommend to perform ultrasound guided cyst puncture with a fine 0.6-0.7 mm needle when the serological test is not conclusive, but hydatid cyst is suspected. The cyst should be punctured only through normal parenchyma and the extracted fluid should be examined for the presence of scolexes and of the specific *Echinococcus* antigen. A correct differential diagnosis between hydatid cyst and simple cyst should be made by all available means since the prognosis and treatment are completely different for the two entities.

Regarding hydatid cyst puncture, experienced authors report rare complications, if it is performed under hydrocortisone hemisuccinate protection and possibly, albendazole protection. The complications include rashes, allergodermia and, very rarely, Quincke's edema.

The type of cyst with detached membrane is typical for hydatid cyst and the detection of such an aspect certifies the diagnosis of hydatidosis.

The type of hydatid cyst with daughter vesicles (with thick septa or small cysts inside the cyst) generally poses few differential diagnosis problems. Some simple liver cysts may rarely have a fine septum inside, but hydatid septa are thick. Sometimes, differentiation should be made with polycystic liver, where multiple cysts of variable sizes, with fine walls or no walls at all, surrounded by normal hepatic parenchyma will be detected.

The type of hydatid cyst with hydatid matrix (resulting from the dehydration of hydatid fluid), which has a jelly-like pathologic appearance, should be differentiated from a solid hypoechoic tumor. The thick, visible cyst wall allows for differentiation and represents the most useful element for the ultrasound diagnosis. Other possible differential diagnoses are cystadenoma or cystadenocarcinoma (both very rare findings), Echinococcus multilocularis infection, necrotic primary or secondary tumors (metastases).

The type of calcified hydatid cyst – which will appear on ultrasound as having a highly hyperechoic wall with a posterior acoustic shadowing – is a completely incidental ultrasound finding. The entire calcified cyst may be visualized or, because of the very intense cyst calcification, only the hyperechoic anterior wall is visualized, which generates a posterior acoustic shadowing that will hide the rest of the cyst ("the shell sign"). The "shell sign" may also occur in the case of hepatic calcifications (usually smaller in size, 1-3 cm), or in the case of scleroatrophic gallbladder (but the "shell sign" will be located in the projection area of the gallbladder).

Other complementary diagnostic methods in hydatid cyst are: X-ray (plain radiography) of the hepatic region (possibly using image enhancement), contrast enhanced ultrasound (CEUS) and computed tomography (CT). In old hydatid cyst cases, the radiography of the hepatic region will highlight the presence of a calcified cyst wall. In case of doubt, the use of the scope enhancer is helpful, as the presence of calcifications in a cyst is a sign of hydatidosis. Another method used in unclear cases is CT. The thickness of the cyst wall (a thick wall is typical for hydatidosis) and particularly, the presence and size of the wall calcifications will be accurately assessed.

Calcification of the hydatid cyst wall occurs when the parasite is dead and is an extremely important finding in determining further evolution and prognosis. In the case of a calcified cyst, serology for hydatidosis is frequently negative and treatment is not necessary. Hence, it is important to assess wall calcifications using CT.

In current practice, CT is used if available whenever there is a doubt about the thickness of the cyst wall (for diagnosis) or when we wish to find out if the hydatid cyst is viable or calcified. A viable cyst will be treated by surgery or medically, while a calcified cyst does not require therapy.

The treatment of hydatid cyst addresses viable cysts, and can be either medical or surgical.

The medical treatment of hydatid cyst is intended for young cysts, generally type I cysts since the drugs administered in echinococcal infections can penetrate the wall of young cysts. It consists

of albendazole in a dose of 800 mg/day for 30 days. A series of three courses of treatment of 30 days each, separated by one month pauses, is recommended. The treatment's efficiency is assessed by ultrasound, by monitoring the size of the cyst (which decreases or remains unchanged), the membrane detachment or disruption, and the cyst's "aging". Medical treatment is intended for young cysts, recently detected by ultrasound, or for postoperative recurrences.

In current practice, treatment with Albendazole is preferred for all young hydatid cysts, even if these will subsequently be referred for surgery or percutaneous treatment, because the risk of intraoperative dissemination and consequently, postoperative recurrence, is thus reduced.

The percutaneous treatment of hydatid cyst consists of the injection of sclerosing agents into the cyst, using 23 gauge (0.6 mm) needles. The needle is placed inside the cyst under ultrasound guidance. The technique is intended for anechoic hydatid cysts and less for cysts with "daughter vesicles" (but it can be performed in case of visualization of germinal centers – protoscolexes).

The patient is under conscious sedation with Dormicum and the cyst will be approached under ultrasound guidance, passing through unaffected liver parenchyma in order to prevent peritoneal cyst rupture. The tip of the needle will appear as a hyperechoic point on ultrasound. The cyst content will be completely aspirated, then hypertonic saline solution (50% or 20%) or, more frequently, 96° or 70° alcohol will be injected (the use of alcohol induces the sclerosis and consequently the effective destruction of the cyst. The solution injected in the cyst is left in place for approximately 10 minutes (even 20 minutes for saline solutions), after which the content is completely aspirated (under ultrasound guidance) - Pavia protocol (Fig. 1.60). The complete sclerosis of the cyst wall is performed, which prevents fluid recurrence. This injection-aspiration technique is termed PAIR (percutaneous aspiration-injection-reaspiration) and is an effective alternative to surgery. The adverse reactions of this technique include: allergic reactions, fever, rarely liver abscess, biliary lesions, vascular thrombosis.

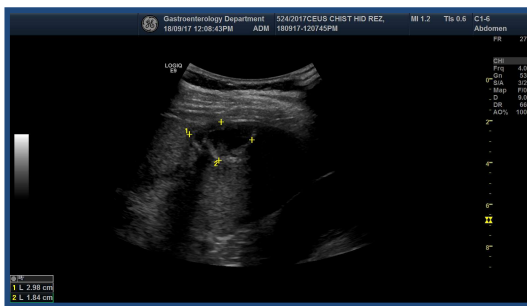


Fig. 1.60 Resected hydatid cyst

When 96° alcohol is used as a sclerosing agent (extremely strong and dangerous sclerosing effect for the bile ducts), some authors recommend that before injecting it, the aspirated fluid should be assessed for the presence of bile pigments, especially if this is not clear.

The percutaneous treatment of the hepatic hydatid cyst is preferably performed under albendazole protection (which is administered before puncture, but also after percutaneous therapy, in 1-2 treatment courses).

The posttherapeutic monitoring of the cyst will be carried out either by ultrasound or by ultrasound + CT. In general, after 24 hours, the detached cyst membrane can be visualized and a follow-up at 1-2 months will highlight the cyst disappearance. Another possible evolution is the structural change when the cyst will appear as hyperechoic. The persistence or reappearance of the fluid content is considered as a therapeutic failure, due to incomplete or insufficient treatment.

Most studies regarding the use of PAIR for treatment of liver hydatid cyst come from Turkey and Saudi Arabia (endemic areas). They showed encouraging results regarding minimal adverse reactions and treatment success (decrease or cysts disappearance in more than 80% of the cases). Similar positive results were reported by Chinese authors.

As part of the chapter on liver cystic images, we will present two particular conditions in terms of hepatic pathology: the liver hematoma and liver abscess. In both situations, the ultrasound aspect is not strictly anechoic, it is most frequently hypoechoic, the structure is generally inhomogeneous, but ultrasound is an easy and useful diagnostic and monitoring tool.

Liver hematoma

Definition: an intrahepatic or subcapsular collection of blood, usually as a consequence of trauma. There is a relationship between liver hematomas and trauma, which can be direct (a blow, a fall or a car accident) or after liver biopsy (in up to 5-10% of cases, small subcapsular, most frequently asymptomatic hematomas may occur). Factors favoring liver hematoma are: coagulopathies - decrease in the prothrombin index to less than 50%, thrombocytopenia below $100.000/\text{mm}^3$ or thrombocytopathies: biopsy of a hemangioma or even of a hypervascular hepatic tumor.

Depending on their location, liver hematomas can be *intrahepatic* or *subcapsular* (under the Glisson's capsule). It can remain strictly localized or it can open into the peritoneal cavity, leading to hemoperitoneum.

The clinical presentation of liver hematomas is extremely variable, from asymptomatic to hemorrhagic shock. Sometimes, a hematoma is incidentally detected in a patient with mild discomfort in the right hypochondrium, following a minimal right hypochondrium trauma. In other cases, the patient is in hemorrhagic shock, after abdominal trauma (very frequently after a road traffic accident), and abdominal ultrasound detects hemoperitoneum and a liver hematoma. Occasionally, a hematoma can be detected by ultrasound a few hours after liver biopsy (LB), most frequently in a patient that is asymptomatic or has a discomfort in the right hypochondrium (liver ultrasound should not be performed in asymptomatic patients, but it can be useful if the patient has post-biopsy symptoms).

Regarding post-LB hematoma, it is a known complication, with different incidences reported in the literature. In general, it occurs in 1-3% of cases in which biopsy has been performed with a thick needle (modified Menghini needles with an outer diameter greater than 1 mm, required for the evaluation of chronic diffuse liver diseases). The incidence of hematomas varies depending on the needle's size (1.2 or 1.8 mm) and on the experience of the doctor who performs the biopsy. Another

important factor are the coagulation parameters (biopsy is contraindicated if the Quick index is lower than 50% or if thrombocytes are lower than $100,000/\text{mm}^3$ – in these cases a non-invasive evaluation of fibrosis or transjugular liver biopsy are preferred, to avoid hemorrhagic complications). In our experience, with more than 2500 liver biopsies for the evaluation of diffuse liver disease, there were two cases (0.08%) of liver hematoma (one with symptomatic hemoperitoneum).

Prospective studies on ultrasound monitoring of the liver 24 hours after liver biopsy showed a 5-10% incidence of small liver hematomas (mostly subcapsular, asymptomatic). In clinical practice, the liver is assessed by ultrasound 24 hours after biopsy only in symptomatic patients (persistent discomfort or pain in the right hypochondrium, pallor, anemia, tachycardia or arterial hypotension).

The ultrasound appearance of liver hematomas can be typical, but sometimes they can be difficult to diagnose by ultrasound. Subcapsular hematomas appear as hypoechoic (more rarely anechoic or almost anechoic) crescent lesions situated between the hepatic parenchyma and Glisson's capsule. Intrahepatic hematomas are generally hypoechoic (sometimes anechoic), with different shapes and irregular margins (Fig.1.61). The clinical information is very important, because if when examining a patient after abdominal trauma or after a liver biopsy, a hypoechoic, not clearly delimited area is detected, a hematoma should be suspected. Detection of a fluid amount in the Douglas space ("dense" peritoneal effusion) is another element supporting diagnosis. Not in all cases anamnesis reveals severe trauma, sometimes a mild trauma on the background of coagulopathy or pathological liver may also induce lesions.

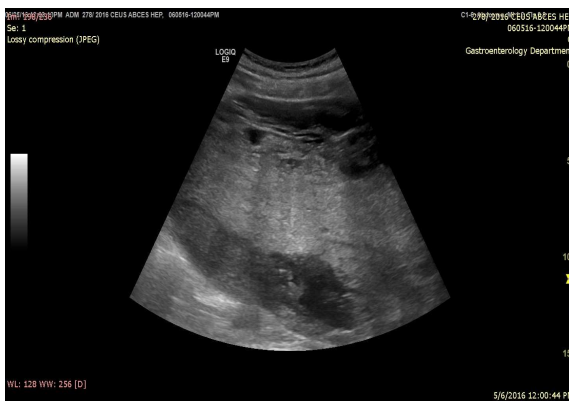

Fig.1.61 Intrahepatic hematoma.

In old intrahepatic hematomas, septation may occur, and the collection is most frequently inhomogeneous. If the patient develops fever, malaise, a superinfection of the hematoma should be suspected, with abscess transformation.

If a hematoma is suspected, power Doppler can aid in the ultrasound diagnosis but with low value, as well as CEUS (contrast enhanced ultrasound) or computed tomography. From the clinician's point of view, the use of CEUS seems to be the most practical, because in a suspicion of liver hematoma, after injecting the contrast agent (SonoVue), the correct diagnosis will be possible in 3-4 minutes (lack of enhancement following contrast bolus in the hematoma, during all vascular phases).

Ultrasound differential diagnosis in intrahepatic hematomas is made with hypoechoic liver tumors, liver abscess, infarction, lymphomatous hepatic infiltration. Subcapsular hematoma should be differentiated from a perihepatic fluid collection (usually with "dense" ascites).

In uncertain diagnosis, ultrasound-guided fine needle aspiration can be done, using 0.6-0.7 mm needles. This is performed particularly from the peritoneal collection in order to establish the presence of hemoperitoneum and, more rarely, from the intrahepatic collection (in the latter case, possibly for an emergency therapeutic decision if the other diagnostic means have failed).

The therapeutic approach in liver hematomas differs depending on the patient's clinical state, on the blood loss, and on the continuous hemorrhage (possibly evaluated by power Doppler or CEUS). Conservative therapy is preferred (haemostatic drugs, blood transfusion). In severe cases, a surgical approach is needed for haemostasis.

Liver abscess

Definition: intrahepatic pus collection. The cause is most frequently biliary germ inoculation (most frequently from angiocholitis), or hematogenic dissemination or insemination by a therapeutic gesture.

The clinical presentation of a liver abscess is mostly typical, with an altered general state, fever, chills, a septic state. Less common are mild symptoms, such as sub-fever. Anamnesis may find an invasive procedure (ERCP) or surgery in the patient's history.

The ultrasound appearance of liver abscess is somewhat typical: a hypoechoic mass, which is most frequently poorly delimited, inhomogeneous (Fig. 1.62, Fig. 1.63). It may show moderate posterior enhancement. Liver abscesses are frequently highly inhomogeneous. In cases in which gas bubbles are formed, these appear on US as echoic structures (Fig. 1.64), moving with the patient's position. Sometimes, the abscess is anechoic (Fig. 1.65), depending on the pus' consistency. Pyogenic liver abscesses can be unique or multiple. A lesion suspected of abscess can be evaluated using CEUS, the contrast agent will enhance the inflammatory periphery of the lesion, but not the lesion's center, which is avascular (SonoVue is an ultrasound contrast agent with strictly intravascular distribution).

CT can help diagnosis by clarifying some aspects such as the collection's density, the presence of air inside the abscess.

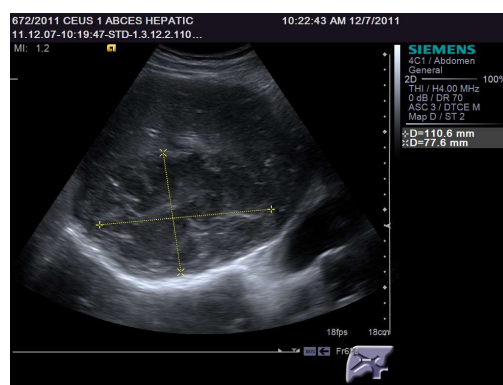
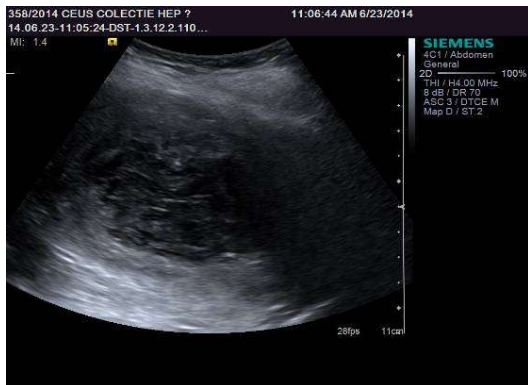

Fig. 1.62. Fig. 1.63. Hypoechoic, inhomogeneous mass – liver abscess

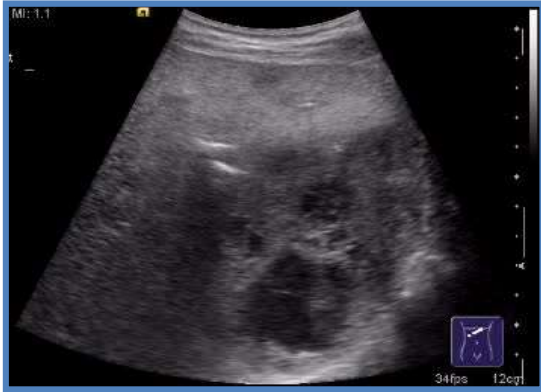

Fig. 1.64. Liver abscess

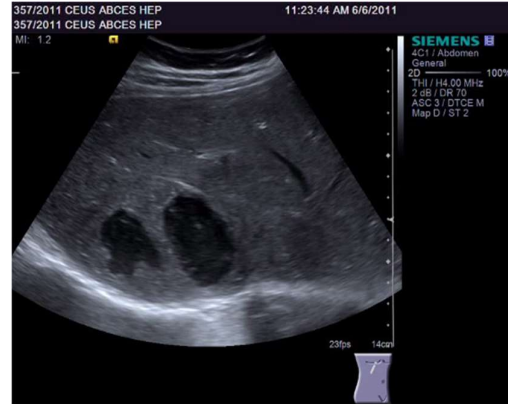

Fig. 1.65 Liver abscess with anechoic aspect

Ultrasound differential diagnosis is required particularly in cases without obvious clinical symptoms (in septic patients and an inhomogeneous hypoechoic liver lesion, the diagnosis is relatively clear). Ultrasound differential diagnosis include liver hematoma, liver tumors, hemorrhagic simple cysts, type II hydatid cyst.

In uncertain ultrasound diagnosis, the diagnostic and therapeutic method of choice is ultrasound guided puncture. For diagnosis, needles with an outer diameter smaller than 1 mm are generally used, which will be guided into the collection and the content will be aspirated. Pus of variable consistency is obtained, sometimes thicker needles are needed if the pus is very thick. An antibiogram should be performed from the extracted pus or direct slide examination, if possible. If the liquid has the color of chocolate and is fluid, amoebic abscess can be considered and serology for amebiasis should be performed).

The diagnosis of liver abscess can be followed by drainage for therapy. Pigtail drain tubes 10-15 F (3-5 mm) in diameter are used; the diameter of the chosen tube depends on the consistency of the collected pus. The majority of liver abscesses can be resolved by ultrasound guided external drainage (in centers with good experience in interventional ultrasound). If very thick pus is found, in addition to using thicker drain tubes (15 F), continuous or discontinuous aspiration should be performed, as well as washing of the cavity with saline and antibiotic.

Monitoring of the residual cavity or the area where the liver abscess was found is also performed by ultrasound, possibly complemented by CEUS or CT. A diminution of the collection up to its disappearance will be observed, with possible formation of a hyperechoic scar at the site of the resolved abscess.

2. SOLID FOCAL LIVER LESIONS

After discussing the cystic (or predominantly liquid) formations, which are usually not very difficult to diagnose by an experienced ultrasonographer, we will move to a challenging chapter on solid focal liver lesions (FLL). First, we will discuss *benign* FLLs and will continue with the *malignant* ones. This is an anatomopathological classification, as from an imaging point of view (ultrasound, computed tomography or magnetic resonance imaging) this differentiation is not always easy and sometimes not even possible. In the latter cases, the final diagnosis is made by ultrasound (or CT) guided biopsy.

BENIGN LIVER TUMORS

1. Liver hemangioma

Definition: it is a benign vascular tumor, consisting of capillary clusters and fibrous septa.

The reported prevalence of liver hemangiomas ranges between 1-4%. According to H. Bismuth, it will be detected in 2% of the population examined by US. In order to determine the prevalence of hemangiomas in our region, we conducted a prospective ultrasound study in 3564 patients (2215 women and 1349 men). We considered as hemangiomas only those FLL which had a typical aspect on ultrasound. We found 0.92% patients with typical hemangiomas, 63.6% of them women and 36.4% men (women/men ratio 2/1), 60.6% of them had a single hemangioma, while 39.4% had multiple hemangiomas.

The clinical presentation offers no specific information, as manifestations are absent. Most of hemangiomas are detected incidentally, on a routine ultrasound. Even large hemangiomas can be asymptomatic. The ultrasound diagnosis of a FLL will frequently induce symptoms such as pain in the right hypochondrium. Although consumption coagulopathy is very rarely described in giant hemangiomas, we did not encounter it in our current practice.

In clinical practice, hemangiomas are divided into typical hemangiomas, up to 5 cm in size, relatively frequent, and cavernous angiomas (more than 5 cm in size, with an atypical ultrasound appearance).

The ultrasound appearance of liver hemangiomas is typical in 90% of the cases, being described as homogeneous, hyperechoic, well delimited images (Figs. 1.66, 1.67, 1.68). They often show posterior acoustic enhancement (due to the liquid blood content). For non-specialists, it seems difficult to explain why a hemangioma, which is a vascular structure (capillary cluster), appears as hyperechoic on ultrasound. The connective stroma that supports the vascular cluster generates the hyperechoic ultrasound appearance, together with the fibrous septa inside the hemangioma. Vascular thrombosis, fibrosis and calcification (particularly in cavernous angiomas) may also occur inside the hemangioma (Fig. 1.69).

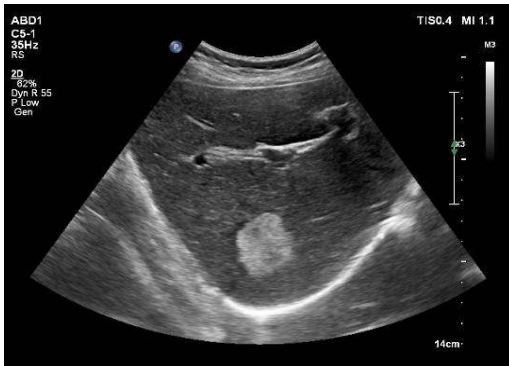

Fig. 1.66 Liver hemangioma – homogeneous, hyperechoic , well delimited FLL

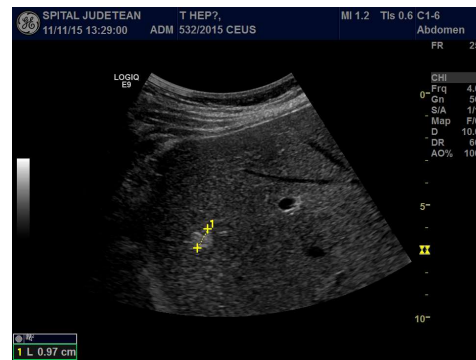

Fig. 1.67 Liver hemangioma - homogeneous hyperechoic , well delimited FLL

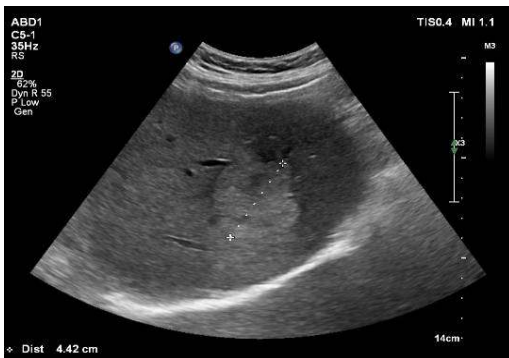

Fig. 1.68 Liver hemangioma

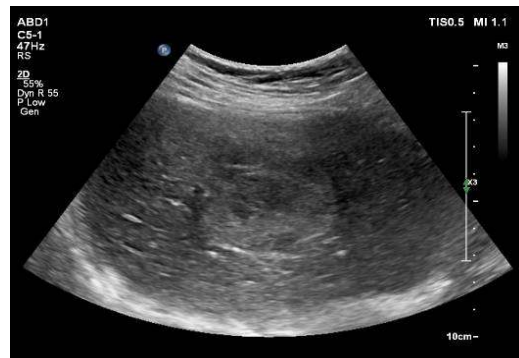

Fig. 1.69 Liver hemangioma with vascular thrombosis

Usually, hemangiomas are less than 3 cm in diameter, they are frequently multiple (in our study approximately 40% of the cases had 2 or more hemangiomas) (Figs. 1.70, 1.71, 1.72), they are often located in the posterior segments, sometimes at the bifurcation of two hepatic veins. Hemangiomas may compress adjacent vascular structures, without invading them.

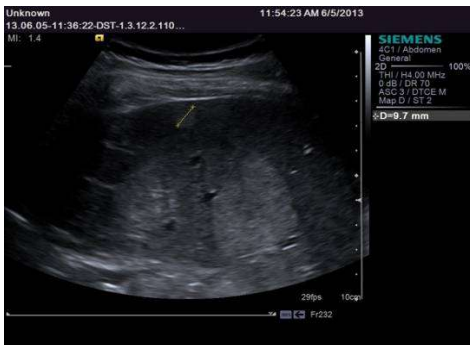

Fig. 1.70 Liver hemangiomas

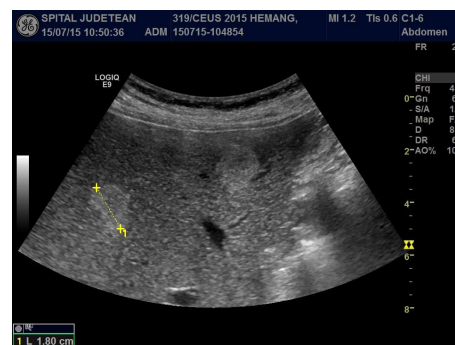


Fig. 1.71 Liver hemangiomas

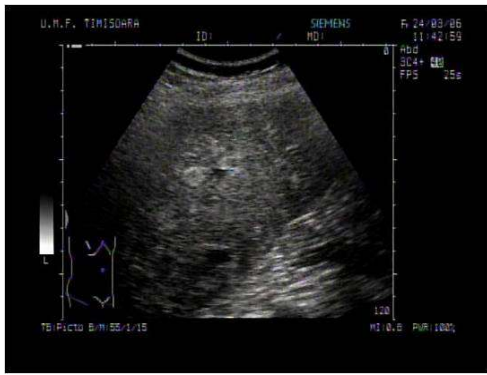

Fig. 1.72 Liver hemangiomas

In approximately 10% of the cases, hemangiomas have an atypical hypoechoic or isoechoic appearance (Fig. 1.73, fig. 1.74). In these cases, they are extremely difficult to differentiate from other FLL by standard US alone. The diagnosis criteria used are the firm delimitation from adjacent parenchyma and vascular compression without invasion of any surrounding structures.

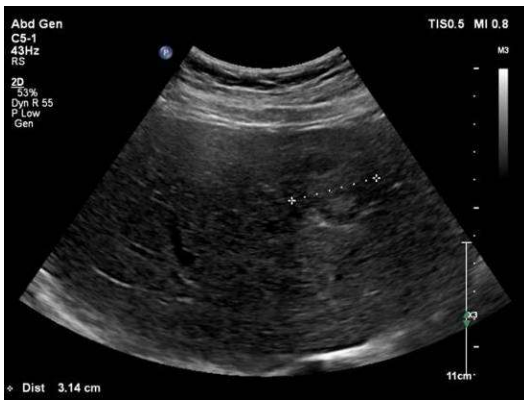


Fig. 1.73 Atypical liver hemangioma

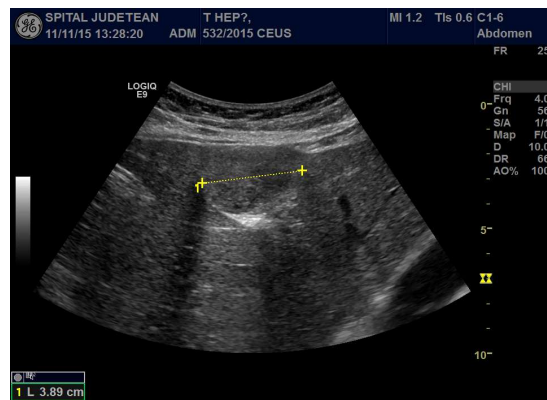


Fig. 1.74 Atypical liver hemangioma

With the introduction of CEUS, these cavernous angiomas or atypical hemangiomas have become easy to diagnose. Thus, in the case of an ultrasonographically unclear FLL, the US contrast agent SonoVue is injected right after ultrasound examination. The typical appearance of a hemangioma following contrast is arterial centripete nodular enhancement, in the late phase with homogeneous enhancement (in cavernous angiomas, there may be areas of vascular thrombosis, with no enhancement). Also, typical for hemangiomas is the presence of contrast inside the mass during the venous and late phases (absence of wash-out). CEUS is diagnostic in approximately 90% of cavernous angiomas or atypical hemangiomas.

Complementary imaging methods for the diagnosis of hemangiomas are CT and MRI. CT can demonstrate a hypodense mass that will subsequently enhance following contrast from periphery to the center of the lesion, and will become isodense or hyperdense in later phases. However, it has been proven that some malignant tumors have the same type of contrast behaviour, so this sign is not characteristic of hemangiomas. This is why the *ideal diagnostic method* for hemangioma (when

contrast enhanced ultrasound is not conclusive) is *MRI*. MRI examination highlights hemangiomas as white, homogeneous lesions on T2 sequence.

In clinical practice, the great majority of hemangiomas are typical and easy to diagnose by ultrasound. The well delimited homogeneous hyperechoic image, possibly with posterior acoustic enhancement, is typical for a hemangioma and does not require complementary examinations. Ultrasound monitoring is sufficient in these cases.

In less typical (sometimes inhomogeneous) hemangiomas, diagnosis should be preferably verified by CEUS or, if it cannot confirm the diagnosis, by MRI (which will show a typical white and homogeneous image on T2 sequence). For masses larger than 5 cm in size (cavernous angiomas) (Figs. 1.75, 1.76), diagnosis in the past was performed using technetium 99m-labeled red blood cell scintigraphy (the SPECT technique), but this method has currently been replaced by CEUS or MRI. It is very important to accurately diagnose hemangiomas or to exclude it as a possible diagnosis. Typical hemangiomas will be monitored, while a lesion that is not a hemangioma will be evaluated by other imaging methods or by ultrasound guided fine needle biopsy.

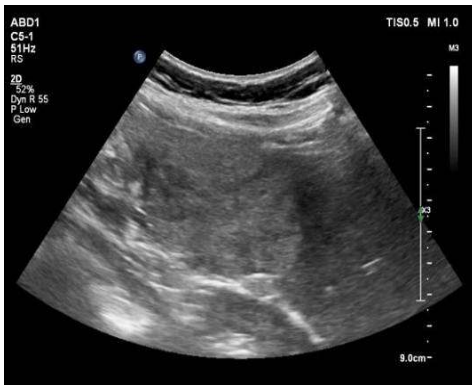


Fig. 1.75 Cavernous angioma

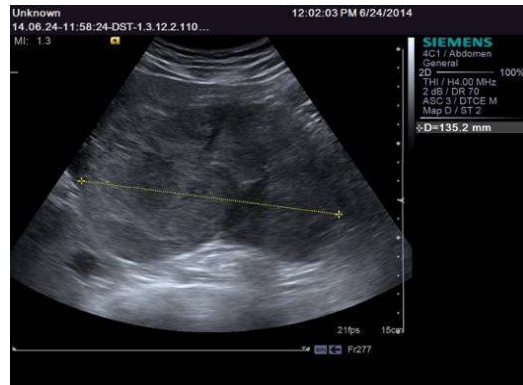

Fig. 1.76 Cavernous angioma

In cavernous angiomas (with giant sizes of up to 10 or even 15 cm), the most frequent appearance is that of an inhomogeneous, hyperechoic lesion; polycyclic outline and inner calcifications can also be present. CEUS will show contrast enhancement from the periphery to the center, but central enhancement-free areas will also be visualized (vascular thrombosis).

In the presence of an atypical FLL, liver diseases such as chronic hepatitis or particularly liver cirrhosis should be excluded. Altered liver function tests (mainly GOT, GPT), along with positive viral markers (HBs Ag or anti-HCV Ab) will suggest a hepatocellular carcinoma (HCC) occurring on the background of most postnecrotic liver disease with severe fibrosis and cirrhosis.

Other *ultrasound differential diagnoses* that should be considered in the case of hemangiomas are: liver metastases (most frequently hyperechoic in cases with digestive adenocarcinoma), hepatocellular carcinoma, adenoma, focal nodular hyperplasia (FNH), focal steatosis areas or fatty free areas on the background of steatosis.

In a clear diagnosis of liver hemangioma, which shows an obvious tendency to increase in size on ultrasound monitoring, diagnosis will be reconsidered (because there is a risk of confusion

between a hemangioma and a malignant tumor). Other imaging and morphological techniques will be used for differential diagnosis.

2. Liver adenoma

Definition: a relatively rare benign liver tumor. It occurs in an otherwise healthy liver and may frequently be accompanied by necrosis or intratumoral hemorrhage. It is less common as compared to focal nodular hyperplasia (which will be discussed later). It can spontaneously rupture, with secondary intrahepatic hematoma or hemoperitoneum.

The ultrasound appearance of adenoma is not typical, it is often slightly hyperechoic (Fig. 1.77), most frequently inhomogeneous. The Power Doppler examination can reveal peritumoral circulation, as well as the presence of an exclusively venous signal towards the center of the mass. In other cases, adenomas can be slightly hypoechoic (Fig. 1.78) or even isoechoic, and the diagnosis can be established through the "bulge sign" (Fig. 1.79) (deformation of the liver outline) or vascular impingement.

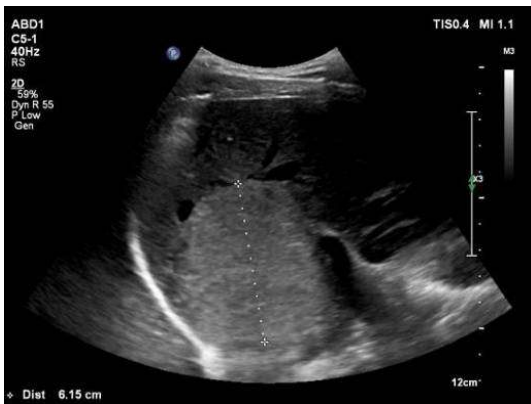

Fig. 1.77 Hyperechoic FLL – adenoma

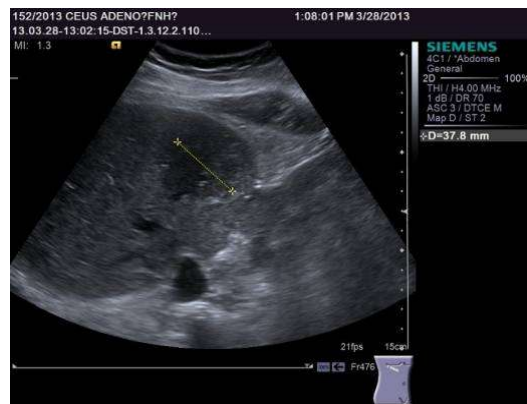

Fig. 1.78 Slightly hypoechoic FLL - adenoma

Complementary diagnosis methods for adenoma are CEUS, contrast enhanced CT, MRI or sometimes, ultrasound guided biopsy.

In a suspected liver adenoma, the evaluation preferably begins with CEUS (the method has a 50-70% sensitivity), which demonstrates the presence of the contrast agent inside the lesion during the venous and parenchymal phases (consequently, a benign lesion). In case of uncertain diagnosis, CT or MRI will be performed for a more accurate diagnosis, taking into consideration a 30% risk of spontaneous rupture and bleeding, as well as a small chance of malignant transformation.

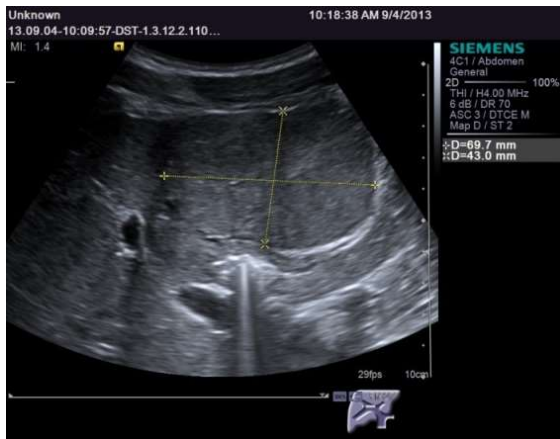

Fig. 1.79 Liver adenoma - the "bulge sign"

3. Focal nodular hyperplasia (FNH)

Definition: it is a benign FLL, an area of liver regeneration, correlated with the patient's gender (it predominantly occurs in women, due to the effect of estrogens on nodule growth) and chronic oral contraceptive use. The typical imaging element of FNH is the arterialization of the lesion and the central fibrous scar.

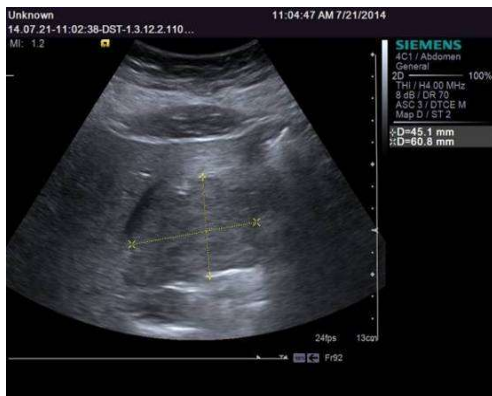

Fig. 1.80 Isoechoic FLL – FNH

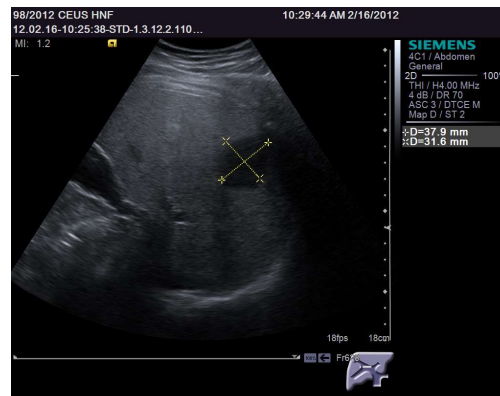


Fig. 1.81 Hypoechoic FLL - FNH

The ultrasound appearance is not typical. There are differences between a single nodule and multiple nodules. The appearance is frequently isoechoic (very close to that of the liver) (Fig. 1.80), or it can be slightly hyperechoic (possibly mild fatty loading) or slightly hypoechoic (particularly on the background of diffuse liver steatosis) (Fig. 1.81). FNH delimitation is not always very clear. In multiple FNH nodules, they may be confused with the aspect of a nodular cirrhotic liver or with a metastatic liver. The central scar typical for FNH is rarely visible by ultrasound (Figs. 1.82, 1.83, 1.84), the diagnostic methods of choice being CT or MRI. Power Doppler or color Doppler can show vascularization that is somewhat typical for FNH (with regular, radial multiple vessels – “spoke-wheel” pattern).

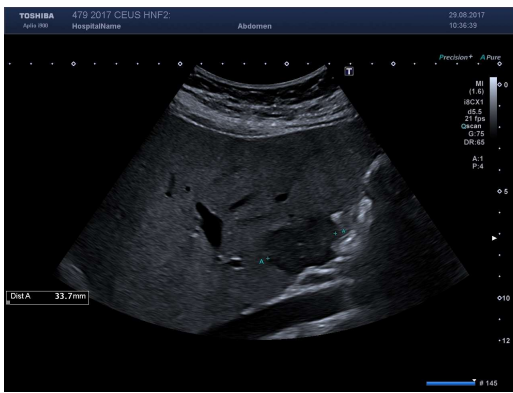


Fig. 1.82 Focal nodular hyperplasia (FNH)

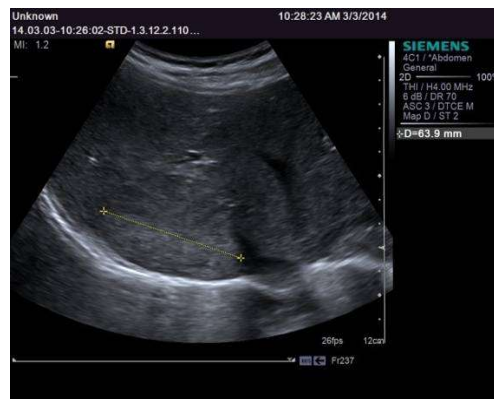

Fig. 1.83 Focal nodular hyperplasia (FNH)

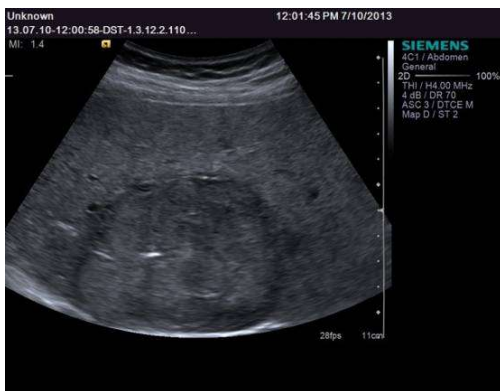

Fig. 1.84 Focal nodular hyperplasia (FNH)

A problem of differential diagnosis that may occur is that with a fibrolamellar carcinoma, which can present inner scar tissue areas, visible on US.

The first line diagnostic method that is currently used for FNH is CEUS. FNH present rapid arterial enhancement following contrast (10-15 seconds), with a pattern that can be typical, resembling the spokes of a wheel. The lesion will remain hyper-enhancing during the portal and late phases, the appearance being pathognomonic for this pathology. The sensitivity of CEUS for the diagnosis of FNH is about 90%. Uncertain cases will be referred for CT or MRI.

The biological picture of FNH is usually normal. The presence of chronic liver disease and of viral markers will be excluded. Alpha-fetoprotein will be determined, which will be normal. In large or multiple FNH, mild cholestasis syndrome can be found (increased gamma-glutamyl transpeptidase and alkaline phosphatase levels).

After diagnosing FNH (most frequently by CEUS), the cessation of oral contraceptive use will be indicated if necessary and the mass will be monitored by ultrasound.

MALIGNANT LIVER TUMORS

In this subchapter, we will discuss the problem of malignant liver tumors. The most frequent are: hepatocellular carcinoma, cholangiocarcinoma, and liver metastases. Sometimes, it is very difficult to decide based on imaging methods if a tumor is benign or malignant. CEUS, or contrast CT, or contrast MRI, or biopsy with pathological examination will be used for differential diagnosis. The same challenge occurs in differentiating a primary tumor from a secondary tumor (metastasis) by imaging. Contrast enhanced imaging methods (CEUS, CT or MRI), or histopathological examination can as well aid the differential diagnosis.

1. Hepatocellular carcinoma (HCC)

Definition: a malignant liver tumor arising from the hepatocytes, which usually occurs on the background of chronic liver disease with severe fibrosis or cirrhosis.

The incidence of hepatocellular carcinoma among cirrhotic population varies with the geographical area, reaching 2-5% in Western Europe and 4-10% in Eastern Europe (including Romania). In endemic areas of viral B or C infection, it can reach 30% (East Africa or South-East Asia). There is a close relationship between chronic infection with hepatitis B or C viruses and the presence of HCC in the population.

HCC most frequently develops on the background of postviral cirrhosis or on the background of alcoholic cirrhosis or hemochromatosis. Another favoring factor is exposure to aflatoxin - a substance that develops particularly in cereals kept under inadequate humidity and heat conditions, especially in African or Asian countries.

In a personal study carried out in the Department of Gastroenterology Timișoara, we found that HCC developed on a background of cirrhosis in 94.4% of cases. This observation was confirmed by studies carried out in other centers - in Bucharest 94.3% HCC were diagnosed in cirrhotics, while in Cluj-Napoca, a background of cirrhosis was found in approximately 72% of HCCs.

The etiology of cirrhosis that led to HCC in our study was: hepatitis C virus infection in 66.6% cases (in 9.2% associated with alcohol abuse); in 20.3% cases it was hepatitis B virus infection (associated with alcohol abuse in 9.2%); while 27.7% of cirrhosis cases were caused only by alcohol abuse.

Considering all these, the clinical approach when detecting a FLL suspected to be a HCC is different depending on the presence of a concomitant chronic liver disease (particularly liver cirrhosis). The *clinical signs* of liver cirrhosis should be searched for: spider naevi on the chest or collateral abdominal circulation. Clinical examination will include liver and spleen palpation. A firm hepatomegaly, frequently with an irregular surface on palpation, is highly suggestive for cirrhosis. A subsequent ultrasound examination of the liver can find the signs of cirrhosis that were detailed in a previous chapter: caudate lobe hypertrophy, usually greater than 40 mm; inhomogeneous liver texture; nodular liver surface - visible particularly if ascites is present; splenomegaly; ascites, gallbladder wall changes – thickened, doubled wall; signs of portal

hypertension. The assessment should continue with FibroScan or other elastographic technique and will end with upper digestive endoscopy, to search for additional signs of PHT - esophageal varices. If one or more of the above mentioned signs are present, the diagnosis of cirrhosis is relatively easy.

The biological picture is not very revealing in cirrhosis, although the following can be detected: cytotoxicity - increased GOT and GPT, which however can sometimes be normal; inflammatory syndrome with increased gamma-globulin levels - in inactive cirrhosis gamma-globulins can be normal; or abnormal biliary excretory syndrome - increased bilirubin, but compensated cirrhosis has normal bilirubin values: and signs of liver failure - decreased prothrombin index, increased urinary urobilinogen and especially, decreased serum cholinesterase. Of all these biological tests, we consider the decrease of serum cholinesterase values below the lower normal limit to be the most specific for liver cirrhosis, because this occurs in no other disease except for acute organophosphate poisoning (easy to diagnose based on anamnesis).

After the diagnosis of liver cirrhosis has been made, etiology will be established based on anamnesis and/or biological tests. The search for viral markers HBs Ag, anti-HCV antibodies and anti-delta antibodies (only if HBs Ag is present) will reveal a possible viral etiology. Diagnosis is much more difficult for ethanol etiology (where the main diagnostic element is personal and family history, biological tests having a limited value, particularly in a patient abstinent for a long time). For less common etiologies of cirrhosis, the following tests should be performed:

- ceruloplasmin, Kayser-Fleischer ring, neurological signs, particularly extrapyramidal (for Wilson cirrhosis with copper storage) will be investigated when cirrhosis is detected in a young man;

- transferrin saturation and ferritin in order to diagnose cirrhosis as part of hemochromatosis; a possible pancreatic (bronze diabetes) or myocardial involvement will also be investigated on this occasion;

- alpha-1-antitrypsin in order to diagnose cirrhosis secondary to its deficit;

- ANAs (antinuclear antibodies), gamma-globulins, auto-antibodies (anti-LKM1, anti-SLA or anti-SMA) for autoimmune cirrhosis;

- cholestasis enzymes (gamma-glutamyl transpeptidase, alkaline phosphatase), bilirubin, along with AMA (antimitochondrial antibodies) in primary biliary cirrhosis.

The clinical approach to the diagnosis of cirrhosis (including etiology) will facilitate the subsequent diagnosis of a possible primary liver tumor. Thus, HCC is more frequent in viral cirrhosis (B or C), being less common in primary or autoimmune biliary cirrhosis.

The ultrasound diagnosis of hepatocellular carcinoma (HCC) starts with detection of a FLL in a patient with severe fibrosis or cirrhosis. Hepatocellular carcinomas may have a hypoechoic, hyperechoic, isoechoic or rosette-like (with a peripheral hypoechoic halo) appearance. None of the mentioned ultrasound appearances is typical. Usually (but not as a rule), small hepatocellular carcinomas are hypoechoic (Fig. 1.85). Large sized HCCs (more than 5-6 cm in size) are inhomogeneous (Fig. 1.86), due to tumor necrosis, or intratumoral hemorrhage. In a personal study regarding the ultrasound appearance of hepatocellular carcinomas, we found the hypoechoic,

hyperechoic and rosette-like appearance in almost equal proportions (about 30%) (Figs. 1.87, 1.88, 1.89).

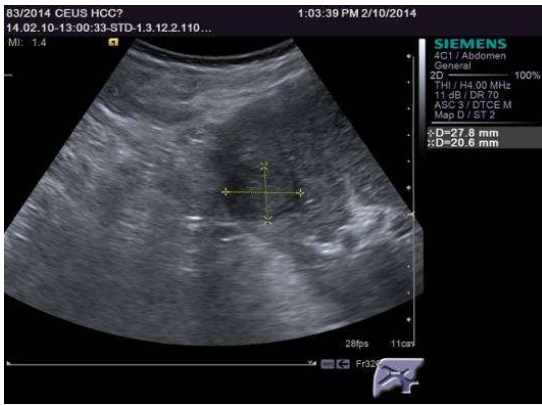


Fig. 1.85 Hepatocellular carcinoma

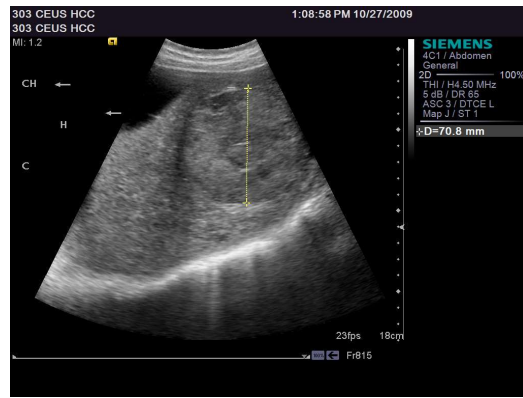


Fig. 1.86 Hepatocellular carcinoma

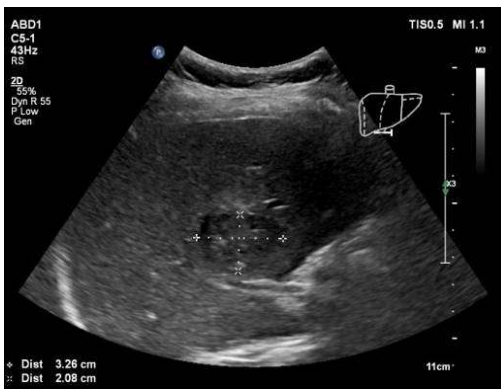


Fig. 1.87 Hepatocellular carcinoma

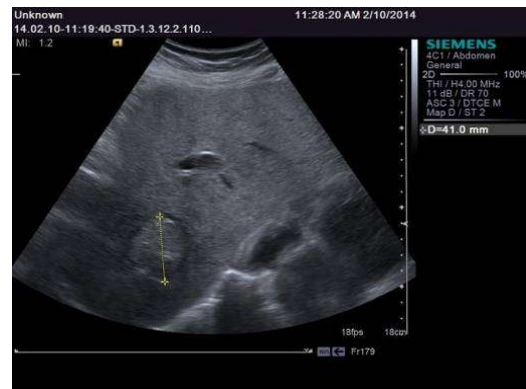

Fig. 1.88 Hepatocellular carcinoma

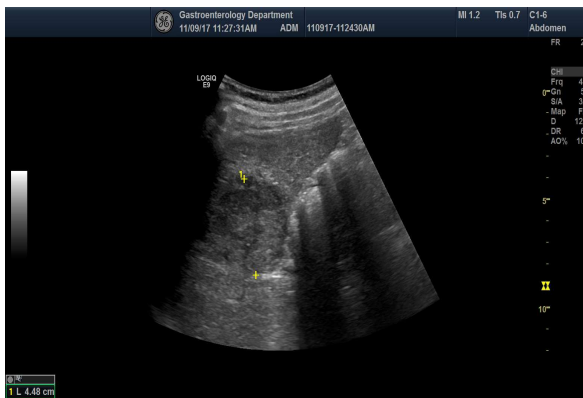


Fig. 1.89 Hepatocellular carcinoma

If a hyperechoic mass is detected in a cirrhotic liver, HCC should be suspected in the first place, and only after its exclusion the possibility of a hemangioma can be discussed.

A relatively frequent diagnostic element found in HCC is portal thrombosis. It appears as a solid like structure in the lumen of the portal vein (Figs. 1.90, 1.91). *Portal thrombosis* can be *complete*, affecting both the common portal vein, and its right and left branches, or it can be *segmental*. Examining the portal branches in order to detect portal thrombosis is essential in any suspicion of HCC, for establishing diagnosis as well as for therapy - malignant portal thrombosis classically contraindicates surgery.

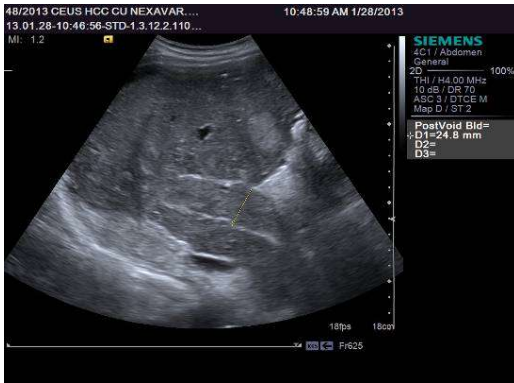

Fig. 1.90 Portal vein thrombosis

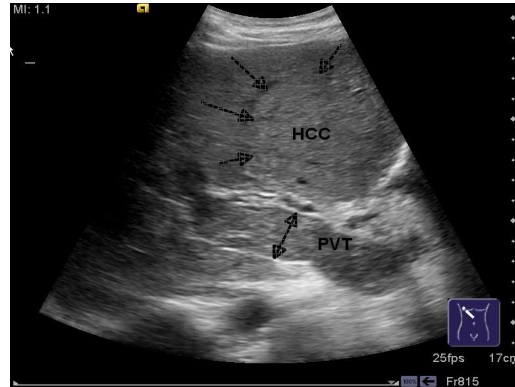


Fig. 1.91 Portal vein thrombosis

In a prospective personal study that included patients with HCC, we found that portal thrombosis was present in 15.4% of the cases. In a Japanese study including the ultrasound assessment of segmental portal branches, the authors found portal thrombosis in 30% of HCC cases.

Portal thrombosis in the absence of hepatocellular carcinoma in liver cirrhosis is relatively rare. There are situations in which portal thrombosis is detected, but HCC cannot be seen by ultrasound. By monitoring liver cirrhosis, a HCC nodule will subsequently be discovered. Sometimes, when the liver structure is extremely heterogeneous, differentiation between HCC and liver cirrhosis is almost impossible.

The diagnostic approach if a FLL is discovered by ultrasound in a patient with liver cirrhosis is as follows: search for signs of portal thrombosis (their detection confirms the diagnosis of malignancy), determine serum alpha-fetoprotein (AFP) levels. Normal AFP values are lower than 7-10 ng/ml. Values higher than 200-400 ng/ml are diagnostic for hepatocellular carcinoma. Unfortunately, only about 1/3 of HCC have pathognomonic AFP values, even if the size of the liver tumor is relatively large. In another third, AFP values range between 10 and 400 ng/ml, thus significantly facilitating the diagnosis.

CEUS will always be used for the evaluation of a newly developed nodule in a cirrhotic liver. Typical for HCC is the arterial enhancement, followed by wash-out during the venous and/or late phases. CEUS sensitivity for the diagnosis of HCC is 80-85%. In uncertain cases, other diagnostic means can be used, such as spiral contrast-CT or contrast-MRI.

Sometimes it is very difficult to establish only by imaging techniques whether the hepatic nodule is a regeneration nodule in liver cirrhosis, an adenoma, a HCC, or a fibrolamellar carcinoma. In these cases ultrasound guided biopsy should be performed. *Differentiation* between HCC and focal nodular hyperplasia can be made using CEUS, CT or MRI (central scar); differential diagnosis

with hemangioma, using CEUS or MRI (white and homogeneous image on T₂). Differentiation between focal steatosis area or fatty free area and HCC will be made using CEUS or CT (by establishing tissue density in different areas).

Lately, liver ultrasound for FLL diagnosis has been greatly improved by the use of *ultrasound contrast agents*. They consist of phospholipidic shells that include an inert gas, forming microbubbles less than 7 microns in size. They are injected intravenously, cross the pulmonary capillaries and reach the liver first by the hepatic artery (10-40 seconds following the contrast bolus – the arterial phase), and later by the portal vein (40-120 seconds after the contrast bolus – the portal phase). Starting from 120 seconds following contrast is the equilibrium phase – the late phase – that lasts until the microbubbles are destroyed and gas is expelled by the lungs, usually 5-6 minutes following bolus. Assessment of tumor vascularization may help diagnosis, but is not always pathognomonic. European and American guides currently consider that in a hepatic nodule larger than 2 cm, in a cirrhotic liver, with arterial enhancement by CEUS, contrast CT or MRI, followed by washout is sufficient for the diagnosis of HCC. In uncertain cases, ultrasound guided biopsy with *histopathological examination* is required in order to differentiate FLLs.

Fine needle aspiration biopsy (FNA) uses fine needles, with an outer diameter smaller than 1 mm, which will be ultrasound guided to the center of the tumor (CT or MRI guidance is also possible, but is somewhat more laborious). 0.6 and 0.7 mm (23 or 22 gauge) needles are used for obtaining cytologic material and 0.8 and 0.9 mm (21 or 20 gauge) needles for microhistology.

Using large needles for biopsy (core biopsy), bigger samples are obtained for pathological exam. Usually FLLs biopsies are ultrasound guided, "biopsy guns" are used with vacuum type (Vacu-Cut) needles, by which adequate tumor samples are obtained.

The sensitivity of FLL biopsy in centers with good experience is about 90%, with specificity higher than 95%. In a positive morphological diagnosis, the therapeutic stage follows. The problem is more difficult when the diagnosis is negative for malignancy. In this case, a decision should be made between repeating biopsy and monitoring the nodule by imaging. This is the most difficult situation, in which estimating prognosis and deciding the therapy is impossible.

In FNA using cytology needles (0.6 and 0.7 mm), the sample is smeared on a slide and the cytologist will search for malignant cells. Using microhistology needles (0.8 and 0.9 mm), microfragments will be obtained, which will be fixed in formalin and then embedded in paraffin, sectioned and read. The rest of the material obtained by puncture can be used for cytology. An extremely difficult problem is that of cytologists. In Romania, the number of specialists in this field is limited. Core biopsy using needles 1.1-1.4 mm in diameter is probably the most useful method for the assessment of a cirrhotic liver nodule unclear by imaging.

For the prognosis of a liver tumor, it is essential to detect it as early as possible, so that therapy can be initiated in time. HCCs smaller than 2-3 cm are ideal for therapy, but even nodules smaller than 5 cm have an acceptable outcome.

Considering that HCC most frequently occurs on the background of cirrhosis, it is logical that patients with cirrhosis should be screened for the early detection of HCC. *The imaging screening of liver cirrhosis* consists of abdominal ultrasound (every 3-4 months in Japan, every 6 months in Europe, in USA every 6 months in viral cirrhosis and every year for alcoholic cirrhosis or primary

biliary cirrhosis) and bi-annual measurement of alpha-fetoprotein. The periodicity of ultrasound monitoring depends on the extension of the ultrasound network and particularly on the medical costs. In Romania, where an extensive ultrasound network is available, ultrasound monitoring every 6 months is useful and possible, during which the presence and volume of ascites (for diuretic dose adjustment) and suspect liver nodules can be assessed.

Is ultrasound screening of cirrhosis needed? It certainly is both useful and needed for an early diagnosis. In a personal retrospective study regarding HCC size at the time of diagnosis, we investigated a number of HCC cases diagnosed by biopsy. The mean size of HCC at the time of diagnosis was 5.9 cm (late diagnosis). In 16.4% of cases, tumors smaller than 3 cm were found, in 41.8% cases tumors ranging from 3.1 to 5 cm, in 32.8% tumors from 5.1 to 10 cm, and in 8.9% of cases, HCCs larger than 10 cm. This study showed that approximately 58% of HCC cases were diagnosed when they were less than 5 cm in diameter, and thus considered for therapy, but only in 16.4% of the cases, smaller than 3 cm, complete resolution by percutaneous approach is expected.

In a retrospective study of Livraghi in 391 monitored Child-Pugh A cirrhosis cases in which HCC was detected, if the nodule was less than 5 cm in size and no treatment was performed, the 3-year survival rate was 26% and the 5-year survival rate was 11%.

After a HCC has been diagnosed, it can be treated by various means. In tumors smaller than 5 cm, surgical resection or various ultrasound guided techniques are preferred. In patients with HCC in Child Pugh A cirrhosis, postoperative results after 5 years confirm a 33-64% survival rate, directly related to the severity of liver failure.

The results are similar for ultrasound guided percutaneous techniques. Survival is significantly shorter in Child-Pugh B and particularly in Child-Pugh C class. In tumors larger than 5 cm, therapy is palliative, curative results are extremely rare. TACE (transarterial chemoembolization) is used as a first line treatment in these cases, using gelspene particles and chemotherapeutic substances or, more recently, antiangiogenic oral therapy using sorafenib (Nexavar) can be administered.

Ultrasound guided percutaneous treatment is intended for small HCCs (usually less than 3 cm) and can be performed by injecting into the tumor of: absolute alcohol - PEIT; acetic acid (30 or 50%) - rarely used; hot saline solution - rarely used. Another percutaneous treatment option that can be applied to HCCs up to 5 cm is thermal ablation by: radiofrequency ablation - RFA; microwave coagulation; laser ablation.

Percutaneous ethanol injection therapy (PEIT) is intended for small hepatic tumors, ideally less than 3 cm in size. The technique is easy, inexpensive (the price of needles and alcohol), repetitive. Absolute alcohol (96°) is used, which is sterilized by autoclaving. Injection is performed using 0.7 mm Becton-Dickinson needles (spinal needles), or with dedicated PEIT needles (Hakko, Tokyo, with 20 cm length and 21 gauge diameter). These Hakko needles have a conic tip and 3 lateral terminal orifices.

The patient is treated under conscious sedation with Midazolam (2-4 mg i.v.), and the ultrasound guided needle will be introduced into the center of the tumor. If the needle cannot be easily visualized, fine back and forth movements will be initiated in order to make it visible. After the needle is correctly placed, an adequate alcohol amount will be injected, usually 5-20 ml

alcohol/session. The amount of alcohol needed is calculated as to completely cover the tumor volume. Following alcohol injection the lesion becomes highly hyperechoic, which will allow assessment of the treatment's result (Figs. 1.92, 1.93).

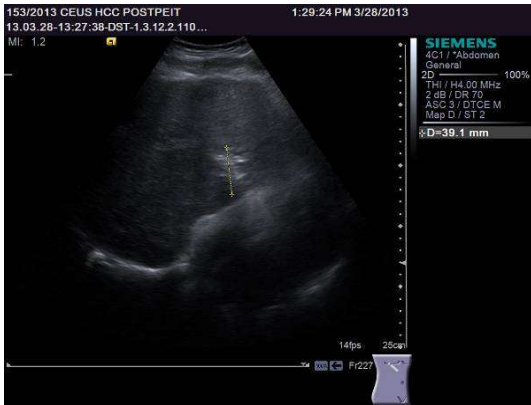

Fig. 1.92 HCC - hyperechoic aspect post PEIT

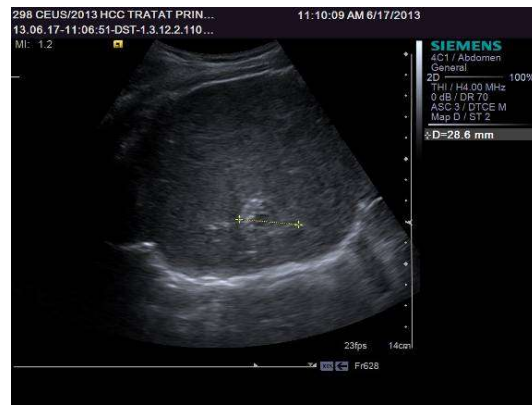

Fig. 1.93 HCC - hyperechoic aspect post PEIT

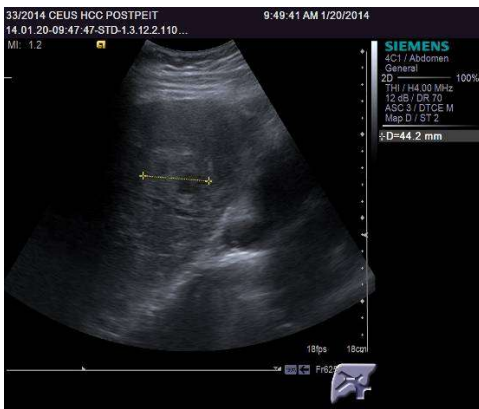


Fig. 1.94 HCC after PEIT

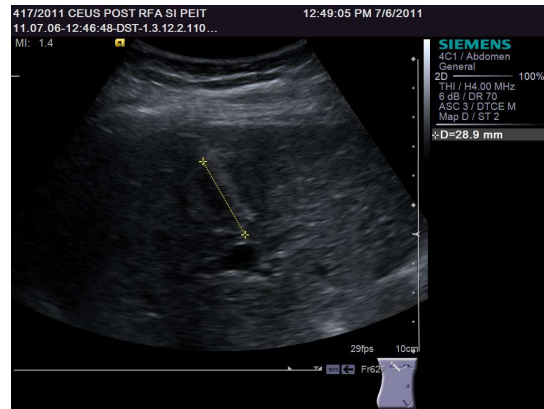


Fig. 1.95 HCC after PEIT therapy

The number of PEIT sessions differs depending on the size of the tumor. Thus, according to Livraghi, 3-4 sessions are required for tumors smaller than 2 cm, 4-6 sessions for tumors between 2-3.5 cm. Japanese authors use the following formula to calculate the amount of alcohol needed for efficient treatment:

$$V = 4/3 \pi (r + 0.5)^3 \text{ ml}$$

where r = tumor radius, $\pi = 3.14$

PEIT technique is used for single nodules (Figs. 1.94, 1.95) or for a maximum number of three nodules. The largest number of PEIT sessions that we performed in a patient was 14. In a group of 22 patients treated by PEIT in the department of Gastroenterology Timișoara, the mean number of sessions/patient was 3.6 and the mean alcohol amount/session was 5.6 ml. The mean number of tumor nodules treated in a patient was 1.4 (limits 1-5 nodules).

Adverse reactions to injection are minimal; transient pain may occur. Sub-fever or fever may appear and pain can persist for 2-3 days.

The absolute alcohol or acetic acid injected into the tumor dehydrates the tumor cells cytoplasm. By entering the circulation, alcohol induces endothelial cell necrosis and platelet aggregation, followed by small vessel thrombosis and tissue ischemia. Two important elements facilitate the therapeutic effect of alcohol: tumor hypervascularization and the low consistency of HCC as compared to the surrounding cirrhotic tissue, which creates a sort of tumor capsule.

PEIT results are monitored by Doppler examination (Figs. 1.96, 1.97), but mostly by CEUS (which in complete tumor destruction will show no enhancement following contrast), or by dynamic contrast enhanced CT (if the lesion is not seen well enough by CEUS). CT monitoring is performed before treatment, 1 month after treatment and subsequently, every 6 months. The advantage of CEUS is that it can be carried out immediately after PEIT or the next day, and if tumor destruction is not complete, the protocol can be repeated.

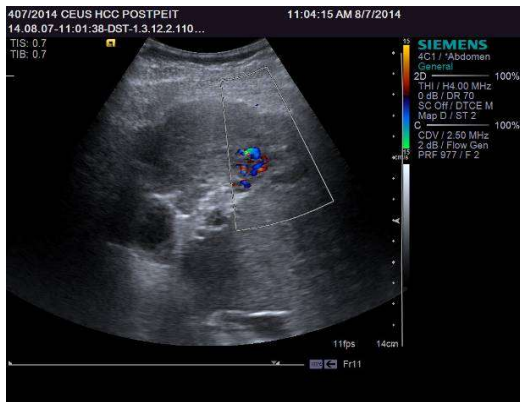


Fig. 1.96 Doppler examination after PEIT

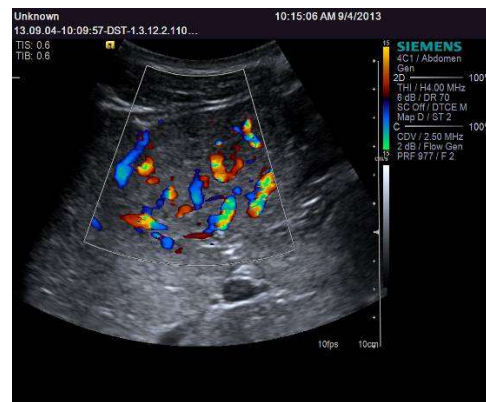


Fig. 1.97 Doppler examination after PEIT

Percutaneous acetic acid injection (PAAI). Several studies proposed the injection of 30-50% acetic acid instead of absolute alcohol, due to better penetration, particularly in fibrous tissue, in the capsule, and consequently, and thus reducing the number of residual tumor cells that risk remaining viable after therapy. Thus, the number of therapeutic sessions and the number of local recurrences is smaller. A comparative PEIT-PAAI study showed better results for acetic acid injection (for tumors less than 3 cm in size). The 1-year survival rate was 83% after PEIT and 100% after PAAI, while the 2-year survival rate was 63% compared to 92% ($p=0.0017$). At the same time, specific complications of acetic acid injection such as acute renal failure were described (Van Hoof).

Livraghi reported survival rates following percutaneous therapy of 88% at 1 year, 70% at 2 years 70%, and 47% 3 years. Survival depends firstly on the tumor size, followed by the Child Pugh class. Thus, in tumors smaller than 5 cm (293 patients reported by Livraghi), the 5-year survival rate was 47%, and in tumors larger than 5 cm (28 patients), the survival rate was 30%. The 5-year survival rates, directly proportional to hepatic function, showed the following results: Child Pugh A

(293 patients) - 47% survival; Child Pugh B (149 patients) - 29% survival; Child Pugh C (20 patients) - 0% survival.

Livraghi also compared results of PEIT, surgery, and TACE and reported the following 5-year survival rates:

- 1838 liver resections, with a 51% 5-year survival rate and 7% perioperative mortality (in highly specialized centers for this type of intervention);
- 737 ultrasound guided PEIT, with a 47% 5-year survival rate and 0% perioperative mortality (other studies report 0.09% perioperative mortality);
- 155 TACE, with a 44% 5-year survival rate.

Radiofrequency ablation (RFA) is another percutaneous technique used in the clinical practice indicated in the treatment of primary or metastatic hepatic tumors (maximum 3-4 metastases). Energy is transmitted into the tumor through a 14-18 gauge needle/electrode. The needle/electrode is ultrasound guided into the tumor. Its terminal portion is non-insulated, thus allowing transmitting radiofrequency energy only to the tumor, which results in heating the region to more than 60°C. This will lead to tissue death, via coagulation necrosis. Some radiofrequency devices (Radionics) have a cool tip electrode, which allows heating of only the region of therapy, without negative effects on the surrounding tissues, while others have needles that spread like an umbrella into the tumor, inducing necrosis of a larger tumor volume.

RFA is performed under sedation if one or two electrodes are inserted, or under general anesthesia if more than two insertions are needed - larger tumors. A RFA session lasts approximately 10 minutes. During the procedure, the treated area will have a hyperechoic appearance, due to cavitation and the vaporizing effect.

Livraghi compared the results of RFA and PEIT in 86 patients with 112 HCCs smaller than 3 cm and found out that RFA resulted in a higher percentage of complete tumor necrosis (90% vs. 80% following PEIT), and required fewer therapy sessions (mean 1.2 for RFA vs. 4.8 for PEIT). Based on these favorable results, Livraghi's team treated 80 patients with liver tumors 3-5 cm in size and 40 patients with tumors 5 to 9 cm, with good results in both groups. The cost of a RFA generator is approximately 30,000-40,000 USD, and an ablation needle costs 1000 USD.

Other thermal techniques use *microwaves or laser* to produce thermal energy.

As a conclusion to the chapter on hepatocellular carcinoma (Fig. 1.98), when a FLL is detected by US, it is mandatory to search for clinical, ultrasound, biological, elastographic and endoscopic signs of cirrhosis, which can indicate a possible HCC. If markers of hepatitis viruses infection are positive, the diagnosis is much more probable and the risk higher. CEUS, CT and/or MRI can be used for a definite diagnosis. In uncertain cases, liver biopsy can decide the diagnosis of malignancy. As follows, potential portal thrombosis should be investigated in order to decide the therapeutic approach.

Regarding therapy, considering that HCC usually develops on the background of advanced liver cirrhosis, less than 10% of HCC cases can be operated. The rest will be treated by ultrasound guided percutaneous techniques. PEIT or RFA are the most frequently used techniques. PEIT, as

well as PAAI, are inexpensive, easy to perform, and do not require particular equipment. For large tumors, TACE is the recommended treatment.

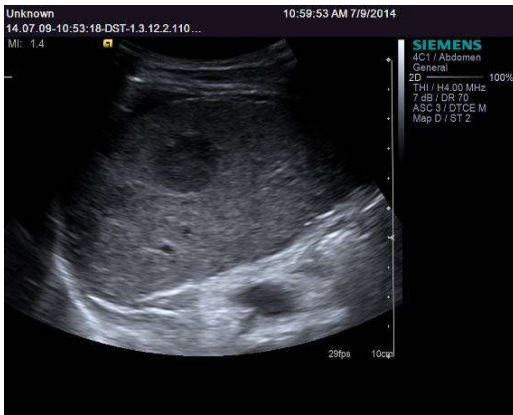

Fig. 1.98 Hypoechoic FLL - Hepatocellular carcinoma

2. Fibrolamellar carcinoma

Definition: hepatic carcinoma that occurs in the absence of chronic liver disease, frequently in young people, with important fibrotic areas.

Imaging diagnosis and sometimes even pathological diagnosis are difficult. Clinically, this type of carcinoma is rarely suspected, because there are no signs of liver cirrhosis, the subjects are young, and alpha-fetoprotein values are normal.

3. Cholangiocarcinoma

Definition: a carcinoma with starting point in the biliary epithelium. It is generally well differentiated, poorly vascularized and does not produce bile. It is relatively rare, the HCC/cholangiocarcinoma ratio is approximately 15:1.

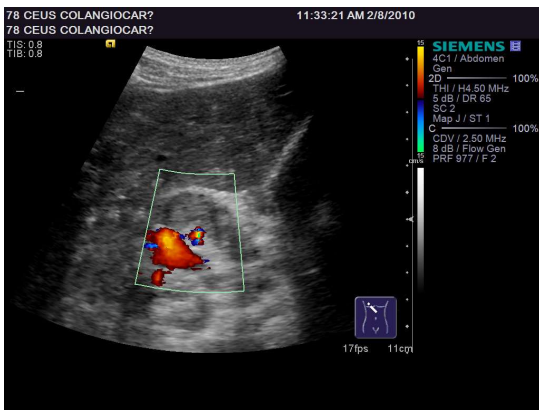


Fig. 1.99 Extrahepatic cholangiocarcinoma

Depending on location, there are three types of cholangiocarcinoma: peripheral - cholangiocellular carcinoma, hilar - Klatskin tumor and extrahepatic (main biliary duct tumor - Fig. 1.99).

Quite rarely diagnosed by imaging, a Klatskin tumor is relatively easy to see by ERCP (endoscopic retrograde cholangio-pancreatography) or MRCP (magnetic resonance cholangio-pancreatography).

The ultrasound appearance of cholangiocarcinoma is not typical. It can appear as a peripheral rosette-like lesion or as inhomogeneous, hypoechoic tumor. Klatskin tumor is rarely detected by ultrasound. Usually, obstructive jaundice with a high obstruction is found, in which intrahepatic bile ducts are dilated (Figs. 1.100, 1.101), but the main biliary duct is not. In these conditions a hilar tumor is suspected, and MRCP or ERCP with brush cytology should be performed. They will show the exact location and etiology of obstruction.

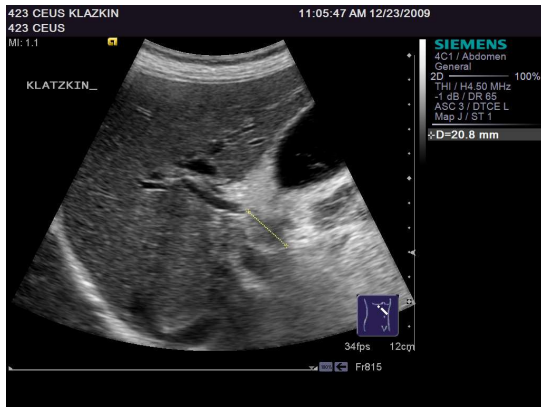


Fig. 1.100 Klatskin tumor

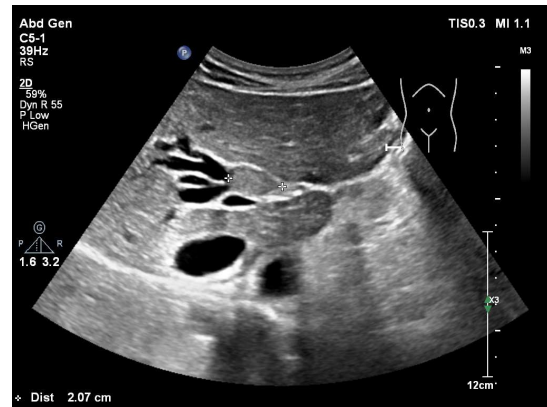

Fig. 1.101 Intraductal cholangiocarcinoma

ERCP will establish whether the cholangiocarcinoma has developed at the level of the biliary bifurcation, in the common hepatic duct or in the right or left hepatic duct. Diagnostic ERCP will be continued in the same session with endoscopic therapy, i.e. biliary stenting. Teflon stents (cheap and quite effective) or metal stents (wall stents, much more expensive) can be used. Usually Klatskin tumors are not operable at the time of their detection, when jaundice has developed. Palliative stenting is the best solution in this situation.

CEUS will show a poorly vascularized tumor in case of cholangiocarcinoma. 3D ultrasound allows tumor reconstruction for planning a possible resection therapy. Another complementary diagnostic method is endoscopic ultrasound (EUS).

Thus, ultrasound is not the ideal diagnostic method for cholangiocarcinoma, but it can suggest the diagnosis that will be confirmed by other techniques (MRCP or ERCP).

4. Liver metastases

Definition: they are the single or multiple hepatic disseminations of tumors located in other organs. Liver metastases most frequently develop in colorectal cancer, small cell bronchial carcinoma, gastric carcinoma, pancreatic carcinoma, breast carcinoma, endocrine tumors of the digestive tract, malignant melanoma, as well as renal tumors.

In clinical practice, there are two particular situations. The first is the incidental ultrasound detection of liver masses, which are suspected to be metastases. A primary starting point will be searched for, and its discovery will confirm the diagnosis. The second situation is that of a patient with known cancer. Ultrasound (or other imaging techniques) are used to detect potential secondary liver involvement.

The ultrasound appearance of metastases is not typical. Metastases can be hypoechoic, hyperechoic or rosette-like. Metastases generated by rapidly growing tumors (pancreatic or pulmonary for example) (Figs. 1.102, 1.103) are most frequently hypoechoic, and so are metastases secondary to breast neoplasms. Metastases from tumors with a slow evolution (colorectal cancer) are frequently hyperechoic (Figs. 1.104, 1.105).

A German study (Bleck) showed that 39.4% of metastases were hypoechoic, 38.9% were hyperechoic, 17.3% were isoechoic, and 4.2% had a cystic appearance. Sometimes, a single metastasis is found, which is difficult to differentiate from other FLLs (hepatocellular carcinoma, peripheral cholangiocarcinoma, adenoma, focal nodular hyperplasia, hemangioma, focal steatosis). Most frequently, metastases are multiple. If multiple hyperechoic, hypoechoic or rosette-like lesions are found (Figs. 1.106. 1.107. 1.108), the ultrasound appearance is relatively typical for metastases.

The most typical image for liver malignancy is the rosette pattern, but it does not allow to differentiate a primary malignant tumor from a metastatic tumor. Other imaging methods such as CEUS or contrast CT can confirm the ultrasound diagnosis of metastasis. Lately, CEUS has been increasingly used for the evaluation of liver lesions suspect of being metastases. According to CEUS enhancement pattern, metastases can be hypervascular (arterial enhancement following SonoVue bolus) or hypovascular (poor enhancement in the arterial phase). Both types of metastases have as a characteristic a hypoenhancing aspect (washout) during the venous and late phases. Large multicentre clinical studies have shown that CEUS had similar sensitivity to contrast CT for the diagnosis of metastatic liver, but at a significantly lower price.

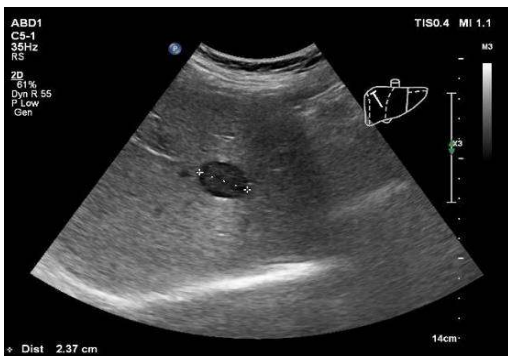


Fig. 1.102. Hypoechoic liver metastasis

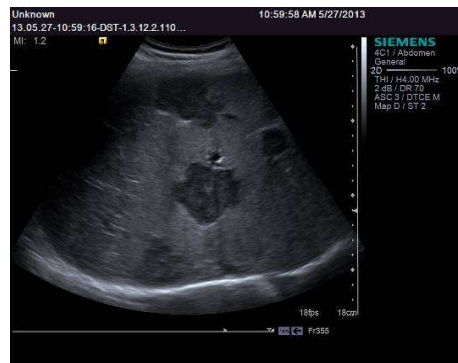

Fig. 1.103. Hypoechoic liver metastases

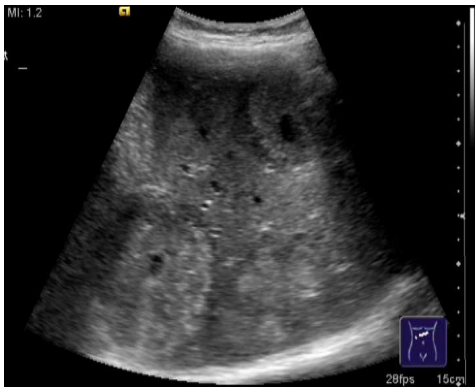

Fig. 1.104. Hyperechoic liver metastases

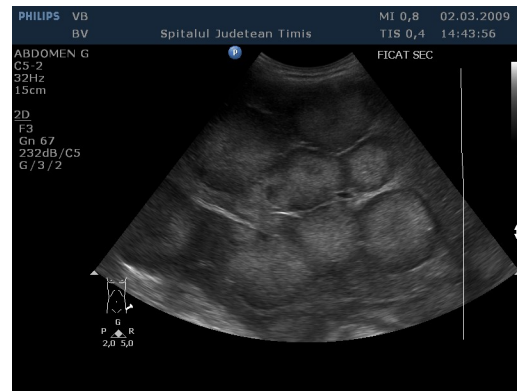


Fig. 1.105. Hyperechoic liver metastases

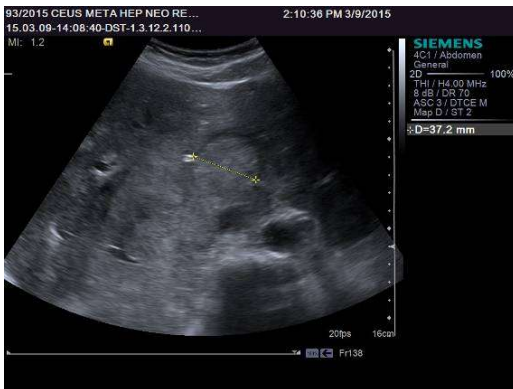

Fig. 1.106. Rosette-like liver metastases

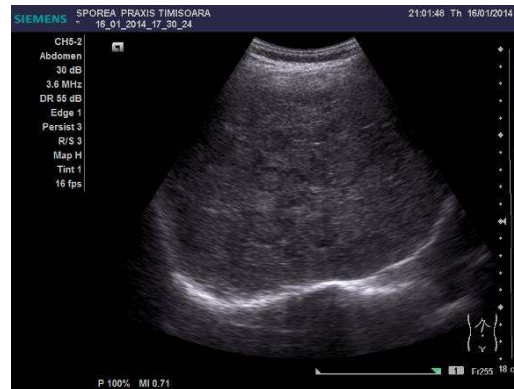

Fig. 1.107 Rosette-like liver metastases

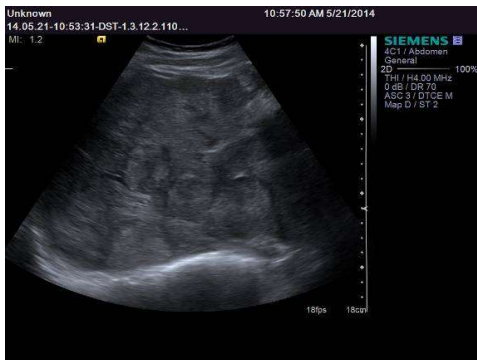

Fig. 1.108 Rosette-like liver metastases

Liver metastases can decrease in size during chemotherapy or may undergo tumor necrosis (the central area becomes hypoechoic or anechoic) and calcification. Sometimes metastases may compress the intrahepatic bile ducts, generating obstructive jaundice. Another ultrasound finding is the low frequency of metastases in a cirrhotic liver.

Standard ultrasound is a good diagnostic method for FLLs, without allowing to determine their origin. CEUS is the method of choice to establish the diagnosis of malignancy.

In current practice, if typical FLLs (rosette pattern, or multiple hyperechoic ones in a digestive cancer) are found in a patient known to have a cancer the ultrasound diagnosis of metastases is established. In a typical single image, CEUS or contrast CT will be performed to confirm diagnosis.

In the case of multiple hepatic images that suggest metastases are found in a patient without a history of cancer, the strategy to search for the starting point will include the following investigations: a full clinical examination including skin inspection for a possible melanoma, breasts and testicles palpation; chest radiography or pulmonary CT - for pulmonary cancer; general abdominal ultrasound (pancreas, kidney, signs of lymphoma, pelvic examination); upper and lower digestive endoscopy or barium enema. Gynecological examination in women and prostate touch in men are minimal examinations. Mammography/breast ultrasound, bronchoscopy, chest and abdominal CT, PSA (prostatic specific antigen in men) can also be performed. In spite of the many laborious paraclinic investigations, in about 30-40% of the cases no starting point of liver metastases can be found. Ultrasound guided biopsy may be attempted, in the hope that histological examination can indicate the type of primary tumor (e.g: metastasis from a digestive tract adenocarcinoma). This procedure does not particularly change therapy and prognosis, which is why it is used less frequently.

Chemotherapy is used in multiple liver metastases. It is usually performed in an oncologic service. Single or few metastases can be treated by surgery or by an ultrasound guided technique (RFA). There are centers with extensive experience in the treatment of liver metastases by RFA. Immediate and long-term results are good. Vascular, biliary complications are frequent (1-14%).

The major risk of percutaneous ultrasound guided treatment in liver metastases is of microscopic metastases that cannot be visualized by ultrasound and which are left untreated.

We conclude the chapter on liver ultrasound by mentioning that in the presence of various ultrasound changes, the operators' experience is extremely important. In addition, the use of high performance ultrasound machines and CEUS helps diagnosis. In unclear diagnosis by imaging methods, ultrasound guided biopsy is used for a definite diagnosis.

CHAPTER 2

THE GALLBLADDER

The gallbladder is a chapter of ultrasound pathology with which the practitioner is confronted daily. It is probably the easiest and the most attractive part of ultrasound, which can, however, frequently raise serious diagnostic problems.

Ultrasound examination most frequently starts with the gallbladder, most patients examined by ultrasound complaining of biliary problems. The gallbladder is relatively easy to examine, first the gallbladder content will be analyzed, then the gallbladder walls. Ultrasound will continue with the evaluation of the main bile duct and of the intrahepatic bile ducts.

In the chapter on biliary ultrasound, we will present the gallbladder malformations, gallbladder polyps, biliary sludge, biliary lithiasis, acute and chronic cholecystitis, gallbladder cancer and post-cholecystectomy disorders.

1. Gallbladder malformations

Definition: they are particular shapes of the gallbladder. Normally, the gallbladder has an ovoid or pyriform shape, is completely anechoic and has well defined walls, up to 4 mm thick.

The gallbladder is 6-8/2-3 cm in size. In particular situations, a length of up to 10 cm is possible. However, if the gallbladder is larger than 8 cm, a cause of this increase should be considered, such as gallbladder hydrops, Courvoisier-Terrier's sign (obstructive jaundice), enlarged gallbladder in pregnancy or liver cirrhosis.

Changes of the gallbladder's shape can be quite frequent, varying from a bisaccular (Fig. 2.1) to a globulous or drop shaped gallbladder. Gallbladder septa can sometimes be present. It should be known that infundibular septa (Heister's valves) are a normal anatomical situation. Most ultrasonographers pay great attention to describing these changes in the gallbladder shape and to the more or less "real" septa, aiming to explain biliary dyspeptic disorders.

We must mention that the term biliary dyskinesia disappeared from the European gastroenterological literature more than 20 years ago. The notion of dysmotility-like functional dyspepsia (nausea, vomiting, bloating) or the notion of irritable bowel (intestinal cramps, bloating, motility disorders) are currently used. Currently, headache is no longer considered to be related to gallbladder pathology; vomiting in headache is due to brain edema, not to gallbladder disease. However, uninformed patients, supported by the medical world, continue to hold the gallbladder responsible for dyspeptic and headache symptoms.

If changes of the gallbladder shape are found, the doctor tends to hold these anomalies responsible for the patient's symptoms. The fact that these particular shapes of the gallbladder had

always existed, without causing any symptom for a long time, is overlooked. Studies on gallbladder motility (Boyden's test) will prove that the gallbladder will also have a normal evacuation function.

Ultrasound Boyden's test is performed by measuring the gallbladder volume under fasting conditions and 45 minutes after the ingestion of 100 g chocolate. The following formula is used to calculate the gallbladder ejection fraction (EF) :

$$EF = \frac{IGV - FGV}{IGV} \times 100$$

where: IGV = initial gallbladder volume

FGV = final gallbladder volume

In order to *calculate the gallbladder volume*, the length, width and thickness of the gallbladder must be measured. Because the gallbladder is pyriform, its width and thickness are identical. The gallbladder is assimilated to an ellipsoid, and the formula to calculate the *ellipsoid volume* is:

$V = \pi/6 \times L \times l \times g$ if $l = g$ and $\pi/6 = 0.5$ the formula will become:

$$V = 0.5 \times L \times l^2$$

In clinical practice, in all cases in which a gallbladder evacuation disorder is suspected, ultrasound Boyden's test will be performed. Surprisingly, in the majority of cases the gallbladder ejection fraction will be normal (an ejection fraction higher than 50-60% is considered normal).

To conclude the chapter on changes in the shape of the gallbladder, we will emphasize that it is part of a normal picture and in most cases it does not explain the dyspeptic or headache syndrome. The causes of these disorders should be correctly evaluated, and then the patients will be treated.

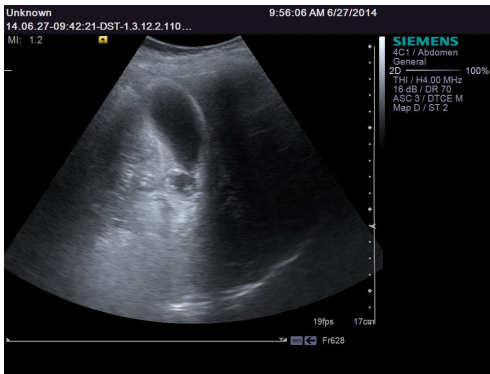


Fig. Bisaccular gallbladder

2. Gallbladder polyps

Definition: they are prominences of the gallbladder mucosa, mostly cholesterol polyps.

Gallbladder polyps have a variable frequency. According to Gebel, they are found in 1.5-5% of women and 4 to 6% of men, being incidentally found by ultrasound.

The clinical presentation of gallbladder polyps is completely asymptomatic. They are detected incidentally by routine ultrasound. However, a false relationship can be established between a dyspeptic syndrome and the detection of gallbladder polyps. The patient must be assured of the lack of significance and danger of incidentally discovered polyps. The real cause of dyspeptic syndrome must be searched for.

The ultrasound appearance of gallbladder polyps is relatively typical and consists of echoic prominences in the gallbladder wall (Figs. 2.2, 2.3, 2.4). The sizes of the polyps generally vary between 3 and 10 mm, rarely exceeding this limit.

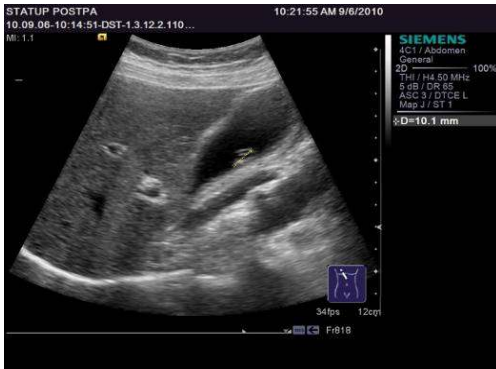

Fig. 2.2 Gallbladder polyps

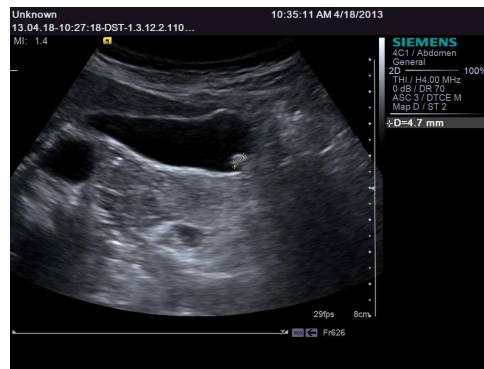


Fig. 2.3 Gallbladder polyps

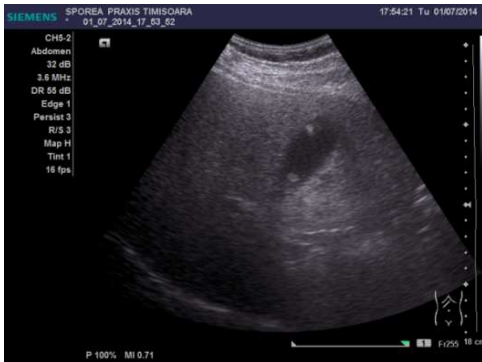
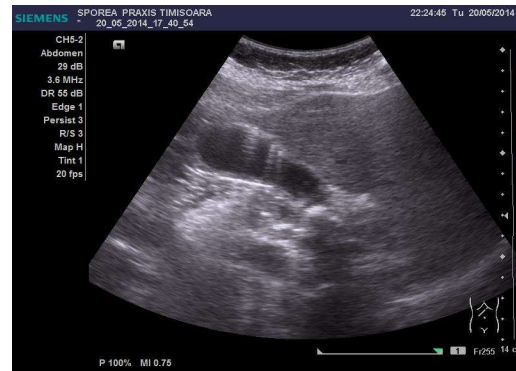
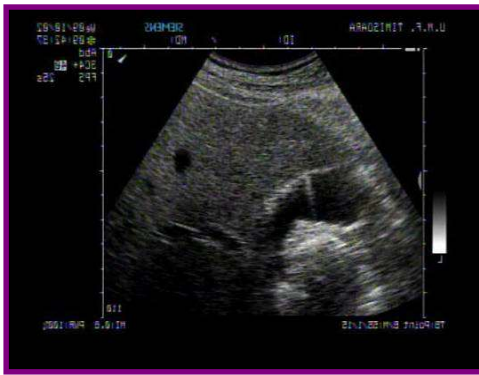Fig. 2.4 Gallbladder polyps

Sometimes a single polyp is found, other times gallbladder polyposis is present. In some cases, the polyps will have a posterior "comet tail" artefact (Fig. 2.5, 2.6)



Figs. 2.5, 2.6 Gallbladder polyps - posterior "comet tail" artifact

Ultrasound diagnostic criteria for gallbladder polyps are: echogenic protrusion attached to the gallbladder wall, without posterior shadow, as well as lack of gravitational fall with the change in the patient's position (unlike the gallstones). Sometimes, the use of high frequency transducers (5 or even 7.5 MHz) may reveal additional diagnostic elements.

Gallbladder cholesterosis is characterized by an irregular gallbladder wall, generated by small excrescences protruding into the lumen (Fig. 2.7) and the presence of "comet tail" artefacts. It may affect the whole gallbladder wall or just a portion of it.

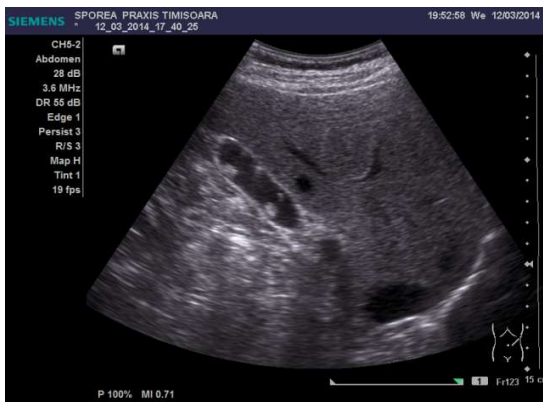

Fig. 2.7 Gallbladder cholesterosis (anterior wall) and polyps (posterior wall)

Gallbladder adenomyomatosis is another anatomopathological alteration of the gallbladder wall, characterized by irregular and thickening (Fig. 2.8). In segmental adenomyomatosis, the gallbladder wall in the affected area has a "festooned" appearance, with similar echogenicity to that of the normal wall.

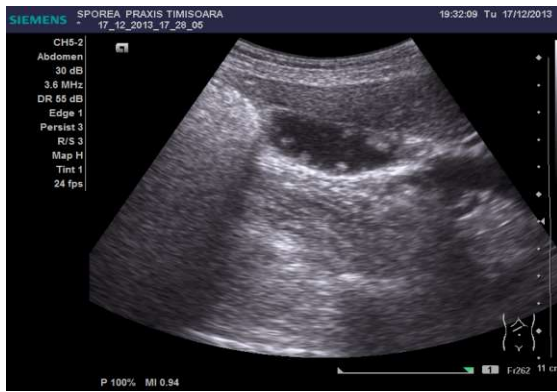

Fig. 2.8 Gallbladder adenomyomatosis

The practical approach in gallbladder polyps consists of monitoring. Small polyps, up to 10-15 mm in size, do not pose diagnostic problems, being completely typical. In polyps larger than 10-15 mm, differentiating the polyp from gallbladder carcinoma should be considered. All diagnostic methods should be used for differential diagnosis: for example, harmonic ultrasound (which will make the image clearer, full of details), 3D ultrasound, contrast enhanced ultrasound, CT, endoscopic ultrasound or MRI. However, when the imaging diagnosis is not clear (with a suspicion of gallbladder carcinoma), diagnostic cholecystectomy is preferred instead of delaying diagnosis (gallbladder carcinoma has a potential for a very rapid malignant development).

Typical gallbladder polyps should be monitored by ultrasound annually. If there is a rapid change in their size or appearance, diagnosis should be reconsidered. Practically, gallbladder polyps, gallbladder cholesterosis and gallbladder adenomyomatosis are completely asymptomatic diagnostic entities, which are detected incidentally and have no clinical significance. The only problem is the possible imaging differentiation from other potentially severe lesions (acute cholecystitis, gallbladder cancer, "tumor-like" biliary sludge or hemobilia).

3. Biliary sludge

Definition: according to Goldberg it is a mixture of mucus, calcium bilirubinate and cholesterol crystals. It occurs when the normal bile becomes thick and viscous.

Following the introduction of new imaging techniques such as ultrasound, "specific" entities such as biliary sludge have been described, unknown in the age of radiology. The cause of biliary sludge is considered to be an alteration of bile components, along with biliary evacuation disorders. According to some authors, biliary sludge is a precursor state of gallstones, while others consider it a completely reversible transient state.

In order to study the natural history of biliary sludge, Goldenberg monitored 96 patients with biliary sludge over a mean period of 38 months. During this time, 14 patients (14.5%) developed gallstones, in 17 cases, the sludge completely disappeared, while in 65 patients biliary sludge was seen intermittently by ultrasound.

Regarding the *cause of biliary sludge*, it can be *secondary* or *primitive*. *Secondary* sludge occurs in association with gallstones, after extracorporeal lithotripsy, in pregnancy, in liver

cirrhosis, in obstructive jaundice, after prolonged parenteral nutrition, in diabetes mellitus, in hemolytic anemia or, sometimes, following ceftriaxone therapy. Biliary sludge is considered to be *primitive* when none of the above mentioned causes can be demonstrated.

We conducted a study on the prevalence and etiology of biliary sludge in the department of Gastroenterology Timișoara, over a 4 year period. 11800 abdominal ultrasounds performed with 3.5 and 5 MHz transducers, using a high performance ultrasound machine were retrospectively analyzed and in 68 cases (0.6%) *biliary sludge* were found. Regarding the etiology of biliary sludge, 75% of the cases were secondary, and only 25% were primitive. Secondary biliary sludge most frequently occurred in liver cirrhosis, accompanying gallbladder stones or in obstructive jaundice.

The ultrasound appearance of biliary sludge is typical (Figs. 2.9, 2.10, 2.11), in the form of a mobile echoic material in the gallbladder. This echoic material does not display a "posterior shadow", and its shape and location in the gallbladder change with the change in the patient's position. A horizontal sludge level is relatively frequent.

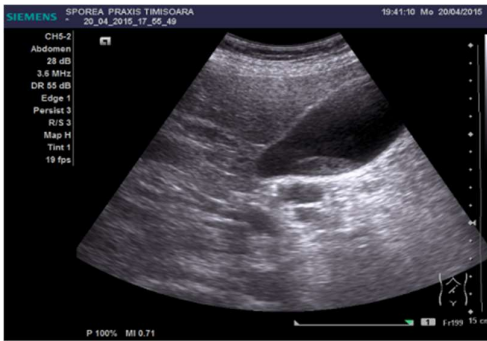


Fig. 2.9 Biliary sludge

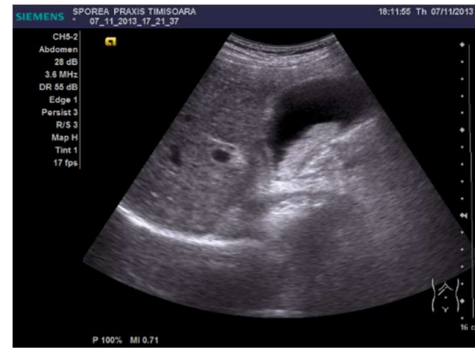

Fig. 2.10 Biliary sludge

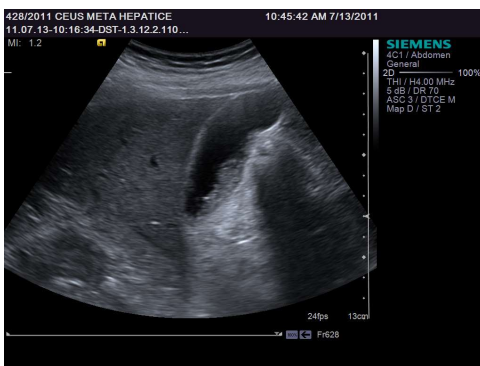


Fig. 2.11 Biliary sludge

Sometimes, biliary sludge can fill the entire gallbladder (Fig. 2.12), conferring the appearance known as "hepatization" of the gallbladder (Fig. 2.13).

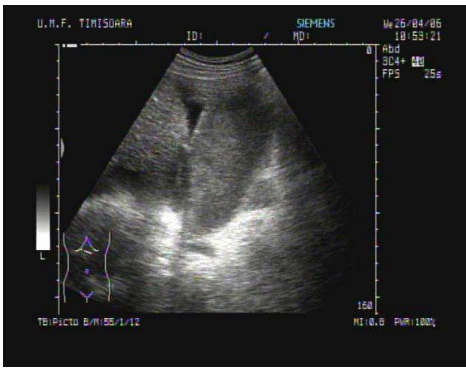


Fig. 2.12 Biliary sludge

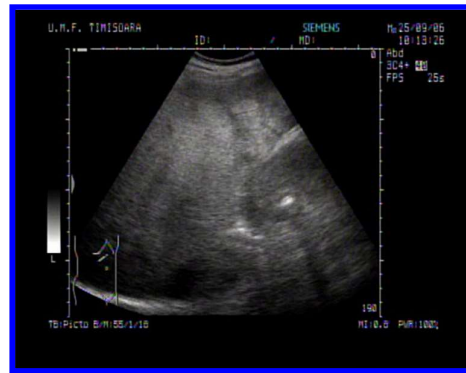


Fig. 2.13 "Hepatization" of the gallbladder

This appearance may occur in hydrops, in pregnancy, or following prolonged parenteral nutrition. Another particular variant of biliary sludge is the ball-like or pseudotumoral aspect (Figs. 2.14, 2.15). It is characterized by a globulous appearance, which can be maintained after gravitational fall, or its "disintegration" may occur.

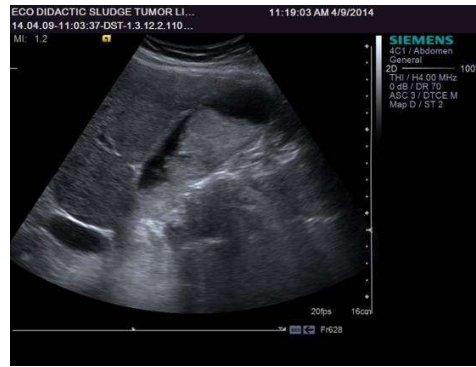
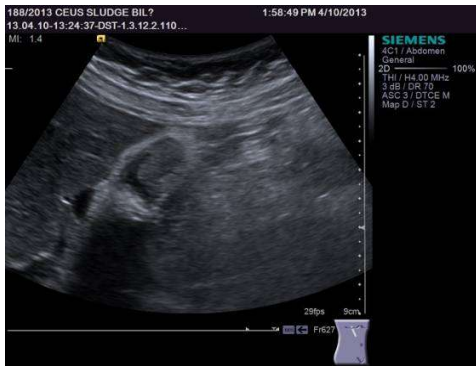
Fig. 2.14 Ball-like or pseudotumoral biliary sludge Fig. 2.15 Pseudotumoral biliary sludge

The *ultrasound differential diagnosis* of biliary sludge should be made with a gallbladder tumor (CEUS is very useful, because the tumor will enhance following contrast, while sludge will not), with gallbladder polyps (which have no gravitational fall), or with gallbladder stones which have a posterior shadow.

In current clinical practice, the ultrasound detection of biliary sludge should be followed by establishing its etiology. In secondary sludge, etiological resolution should be attempted. For primitive sludge, there are two solutions: periodic monitoring by ultrasound or treatment with dissolution drugs (ursodeoxycholic acid – Ursosfalk), until the echogenic material disappears from the gallbladder. To date, there is no clear strategy, possibly also due to the small number of biliary sludge cases that are followed up.

4. Gallstones

Definition: the presence of cholesterol or calcium bilirubinate stones into the gallbladder.

Epidemiology: the prevalence of gallstones in the general population varies from one region to another, ranging from 5 to 20%, depending on genetic factors, on the presence of obesity, dyslipidemia and diabetes mellitus.

In order to evaluate the prevalence of gallstones in our geographical area, we performed a retrospective study in a group of 1318 subjects from urban and rural environment (954 women and 364 men, with a mean age of 46.3±14.55 years). All patients were evaluated by ultrasound for the presence of gallstones or for previous cholecystectomy for gallstones. In 146 cases gallstones were found (123 women and 22 men), and 56 patients had a previous cholecystectomy. Then, we corrected this group to match it with the demographic data of Timiș county regarding age and gender and, we recalculated the estimated prevalence of gallstones in this area. We found it to be *13.4% in the general population, with 8.1% in men and 18.4% in women* (female/male ratio of 2.2/1). Obesity was present in 60.9% of women and in 63.9% of men diagnosed with gallstones. The prevalence increased with age. Thus, if women aged 30-39 years had a 9.4% prevalence, it increased to 25.3% in the 60-69 age group, while in men it increased from 3.9% in the 40-49 age group to 17.4% after 70 years of age.

The known factors favoring gallstones occurrence are: genetics, multiparity, female gender, advanced age, obesity, dyslipidemia, diabetes mellitus, hemolytic anemia, liver cirrhosis.

In clinical practice, a patient has a significantly increased chance to have gallstones if he has a family history of gallstones. This relationship is stronger in the female line (between mother and daughter), and particularly in case of multiple births.

In order to clarify the *relationship between gallstones and diabetes mellitus*, we carried out a prospective study in 696 diabetic patients (362 women and 334 men). We found gallstones in 128 (18.3%) of the diabetic patients. The prevalence of gallstones in diabetic women was 20.7% and in diabetic men, 15.8%. These results show a significantly higher prevalence of gallstones in diabetics as compared to non-diabetic patients (18.3% vs 13.4%, $p<0.01$).

The relationship between gallstones and liver cirrhosis was studied by in a group of 194 patients (113 men and 81 women) with known liver cirrhosis. We found a 21.6% prevalence (42 cases) of gallstones in cirrhotic patients, with 28.3% in women and 16.8% in men. When comparing the prevalence of gallstones in cirrhotics with the general population we found a significant risk ($p<0.01$) for gallstones in liver cirrhosis, both in women ($p<0.05$) and men ($p<0.01$).

An important clinical problem is whether gallstones are symptomatic or not. *Symptomatic* gallstones generate biliary colic. Biliary colic is an intense pain located in the epigastrium and/or right hypochondrium, which lasts for more than 30 minutes. Nausea, vomiting, bloating or headaches are not signs of symptomatic gallstones. Labeling gallstones as symptomatic or asymptomatic is essential for therapy. Surgery is indicated in symptomatic gallstones, and periodic ultrasound monitoring is the approach for asymptomatic gallstones. Surgery in a patient with gallstones just for headache will lead to unexpected results. Thus, headache will persist (gallstones are not a cause of headache), but symptoms belonging to the postcholecystectomy syndrome

(diarrhea, bitter taste, bilious vomiting) may also occur in a patient who was previously asymptomatic.

This is why, if gallstones are detected by ultrasound, a careful inquiry should be conducted, which will allow to categorize them as symptomatic (usually referred for surgery) or asymptomatic (referred for periodic ultrasound monitoring as long as no symptoms are present). Extensive studies have monitored patients with gallstones for 20 years. Of the cases of asymptomatic gallstones, only about 20% became symptomatic and only 10% developed complications (usually after becoming symptomatic). This is why periodic ultrasound monitoring is preferred for asymptomatic gallstones. If a biliary colic occurs, the diagnosis and therapeutic approach should be reconsidered.

The ultrasound appearance of gallstones is typical (sensitivity 95-96%). One or more hyperechoic images of variable sizes inside the gallbladder which generate a "posterior shadow" (Figs. 2.16, 2.17, 2.18, 2.19, 2.20). The "gravitational fall" of gallstone is another general characteristic; if it is not impacted in the infundibulum, it will move with the change in patient's position. The diagnostic triad: echodense, mobile image, which generates a posterior shadow, is typical of gallstones. It should be added that the echodense image must be inside the gallbladder (thus, it will be differentiated from digestive air, usually duodenal air).

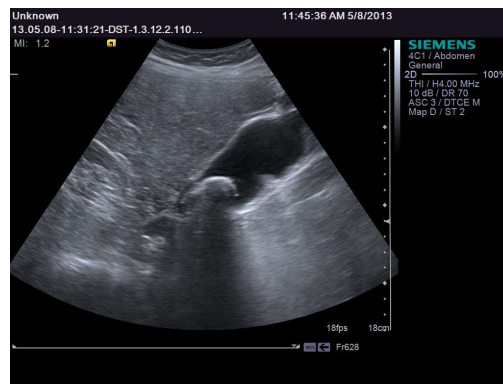
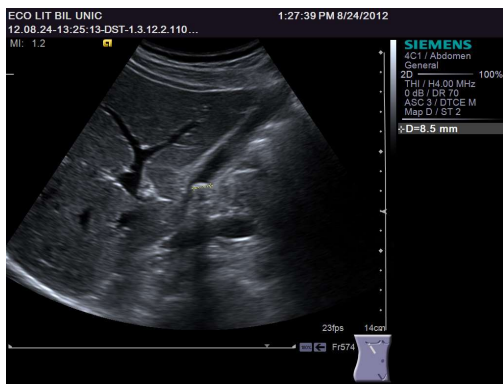


Fig. 2.16; 2.17. Gallstone - hyperechoic image with "posterior shadow"

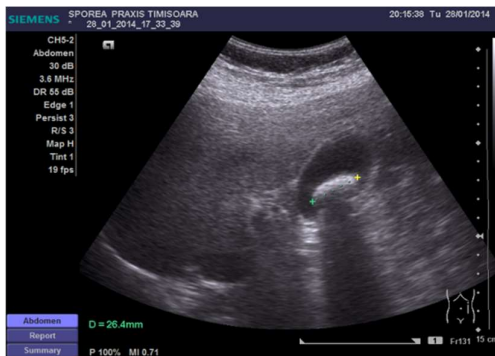

Fig. 2.18 Gallstone

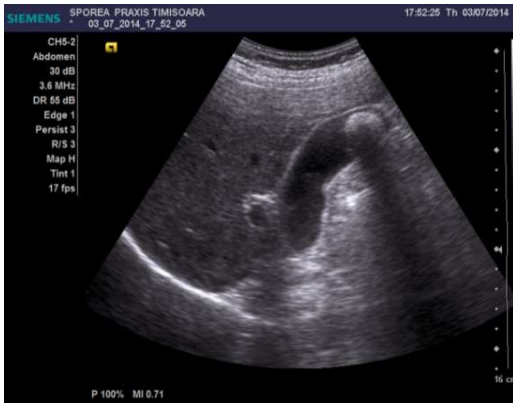

Fig. 2.19 Gallstone

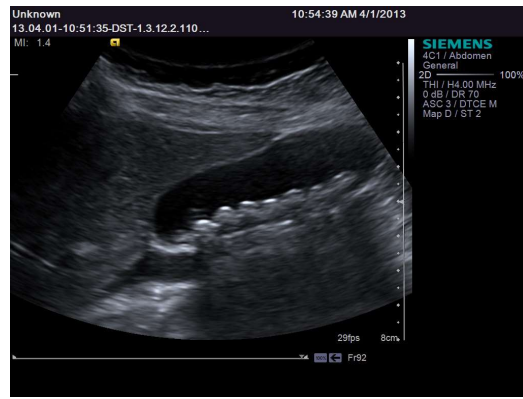


Fig. 2.20 Multiple gallstones

Most frequently, the ultrasound diagnosis of gallstones is relatively easy. It can see whether one or more gallstones are present (without necessarily counting them). Also, their size, their mobility or impaction can be assessed, by changing the patient's position from dorsal decubitus to left lateral decubitus. It is very important to demonstrate the gallstones' mobility in order to exclude one of their complications, the infundibular impaction that leads to gallbladder hydrops (in this case, the gallbladder is usually large, globulous, more than 10/3 cm in size).

Most gallstones generate a "posterior shadow", only small stones (single calculi less than 2-3 mm in size) do not generate a shadow. Sometimes, bilirubinate calculi may not have a posterior shadow (Fig. 2.21).

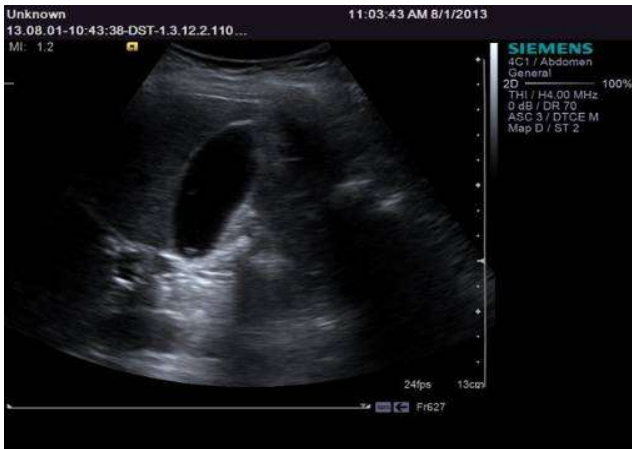

Fig. 2.21 Bilirubinate calculi without "posterior shadow"

There is a Japanese classification of gallstones aspect depending on their chemical content (Tsuchiya classification). Gallstones with pure cholesterol content reflect ultrasounds the most and have a crescent, or half-moon appearance. Usually, bilirubinate calculi have a full moon appearance. The other variants of mixed calculi (calcium carbonate, cholesterol, calcium bilirubinate) have a shooting star appearance. Starting from this ultrasound and at the same time chemical classification of gallstones, we performed a prospective study in the Ultrasound Service of

the Gastroenterology department in Timișoara regarding the types of gallstones found in clinical practice. We studied 263 gallstones cases and we found 35.7% crescent calculi, 37.6% half moon calculi, 16.4% shooting star calculi, and 10.3% full moon calculi. Considering that the crescent and half moon types are typical of cholesterol rich gallstones, we can conclude that in our geographical area, more than 70% of the calculi are cholesterolic and only about 10% are pigment or calcium bilirubinate calculi.

We must emphasize the importance of ultrasound examination of the gallbladder under strict fasting conditions (for at least 8 hours), also with no coffee intake, since it has a cholecystokinetic effect. Fasting is important especially for beginners in ultrasound, so that the gallbladder is filled with bile, thus allowing for a good "ultrasound window" needed to estimate the presence of gallstones. Also postprandial the gallbladder wall will appear as doubled (even if it is less than 4 mm thick), which may raise problems of differential diagnosis with acute cholecystitis.

The typical ultrasound image of a gallstone is generally easy to recognize. *Ultrasound differential diagnosis* will be more difficult in the following cases:

- a gallbladder full of calculi, where the absence of bile will make it difficult to visualize the gallbladder bed (Fig. 2.22);
- an extremely large gallstone that occupies the entire gallbladder, where bile is absent. The ultrasound image will generate the "shell sign" (an echogenic crescent with a large posterior shadow) (Fig. 2.23);
- small calculi (1-2 mm), which may or may not generate a posterior shadow, where it is difficult to differentiate small gallstones from biliary sludge (an etiopathogenic interrelation between the two is common);

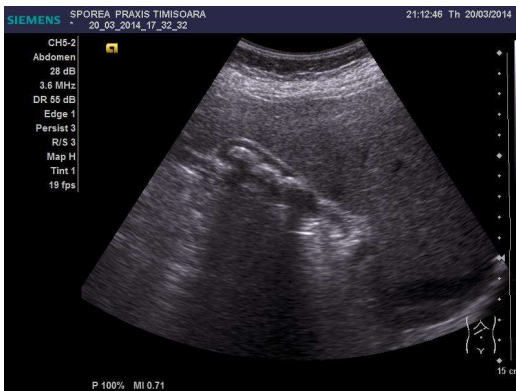

Fig. 2.22 Gallbladder full of gallstones

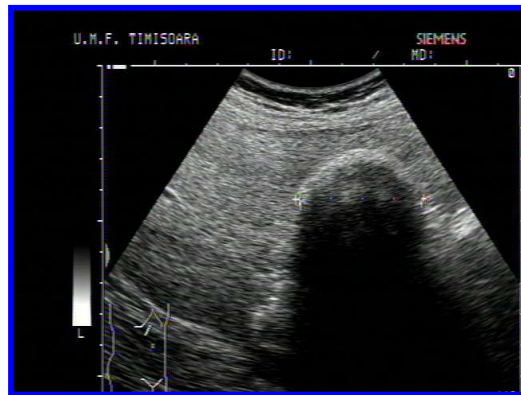

Fig. 2.23 Gallstones - the "shell sign"

– gallstones that do not generate a posterior shadow (brown bilirubinate calculi), which can be confused with gallbladder polyps (but these do not have gravitational fall) or hemobilia (appearance similar to that of ball-like biliary sludge).

Ultrasound is a sensitive and specific diagnostic method for gallstones. In experienced hands, sensitivity can reach 96%."Missed" gallstones can be due to the use of less performant equipment,

to the lack of patient's mobilization during examination (we consider positioning the patient in left lateral decubitus compulsory, since it will favor the gravitational fall of a possible calculus), to an unfavorable examination window (in which case intercostal examination will be used instead of right oblique recurrent subcostal sections), to the presence of very small (and few) calculi, or to the infundibular impaction of the gallstone

A gallstone impacted in the infundibulum is sometimes difficult to see, particularly if it is impacted in the infundibulo-cystic area. In these cases it is possible to see only a large (globulous) gallbladder, under tension. All possible ultrasound maneuvers should be performed in order to demonstrate the gallstone, which can be small, but sometimes even those larger than 10-20 mm are difficult to see (the examiner's experience is also important).

Ultrasound is currently the standard diagnostic method for gallstones. Endoscopic ultrasound (EUS) is the most precise method to evaluate the infundibular area or the main biliary duct for gallstones. CT is rarely useful in detecting a gallstone impacted in the infundibulum that could not be seen by ultrasound. In addition, Te HIDA scintigraphy of the bile ducts (although rarely used in practice) can be performed, which will demonstrate absence of gallbladder enhancement in infundibular obstruction. Sometimes, when it is unclear whether a large gallbladder or hydrops is present (particularly in an asymptomatic patient), ultrasound Boyden's test can be (cautiously) used. A reduction of the gallbladder volume 45 minutes after chocolate ingestion supports the absence of infundibulo-cystic impaction.

From a clinical point of view, ultrasound can be accompanied by the evaluation of the gallbladder sensitivity upon pressure with the transducer (ultrasound Murphy's sign), thus estimating if the lithiasic gallbladder is painful or not on pressure. These data will be complemented by an accurate anamnesis, which will allow to classify gallstones as symptomatic or asymptomatic.

Symptomatic gallstones must be treated. Most cases are treated by surgery. Following the introduction of laparoscopic cholecystectomy, surgery has become much easier. However, a small number of patients refuse or have a contraindication for surgery, in which case there is a *non-surgical treatment alternative* for gallstones, intended only in a limited number of cases.

The non-surgical treatment of gallstones includes drug litholysis and ESWL (extracorporeal shock wave lithotripsy). Drug litholysis is indicated in cholesterol calculi whose volume does not exceed 1/2 of the gallbladder, generally stones smaller than 1 cm (ideally, smaller than 5 mm). It is imperative that the infundibulocystic area is permeable. Ideally, the gallstones composition is verified by cholecystography (possibly CT), which will also assess cystic permeability through the opacification of the gallbladder. Drug litholysis is performed with ursodeoxycholic acid (Ursofalk, 250 mg capsules), or with chenodeoxycholic acid associated with ursodeoxycholic acid (Lithofalk). The Ursofalk dose is 10-15 mg/kg body weight/day, so for a normal weight patient, 3-4 capsules/day are needed (the dose is administered at bedtime so as to accumulate in the gallbladder during the night). The duration of treatment is 6-24 months. Positive results are obtained in 50-80% of the cases, depending on the type of calculi, their number and size. An important practical problem is the relatively high cost for a period of several months. The response to treatment is assessed by ultrasound, with monitoring of the residual amount of calculi.

After successful drug dissolution, there is a risk of recurrence. This generally depends on lithogenic factors existing prior to therapy. It is considered that after successful litholysis or ESWL therapy, there is a 5-year recurrence risk of 30-50%. This high recurrence rate has reduced the enthusiasm for drug therapy, and cholecystectomy (usually laparoscopic) has become the standard method for symptomatic gallstones treatment.

Extracorporeal lithotripsy (ESWL) has copied the extracorporeal treatment model used in urology. In this case, the patient is positioned in ventral decubitus, and the shock waves are targeted on the stones under ultrasound guidance. ESWL therapy is preceded for 2 weeks of dissolution medication (Ursofalk) that will be continued until the complete disappearance of gallstone fragments. In fact, lithotripsy induces gallstone fragmentation, then the bile that has become litholytic under therapy will cause the dissolution of the gallstone fragments. The litholytic mechanism in oral administration of biliary acids (Ursofalk or Lithofalk), which will be subsequently absorbed by the intestine and eliminated in the bile, is the change of the balance between cholesterol, lecithins and biliary acids, making cholesterol soluble into the bile. Thus, the slow dissolution of calculi occurs. The key of success is directly proportional to the continuous administration of treatment.

For extracorporeal lithotripsy, single or maximum 3 pure or predominantly cholesterol calculi up to 10 mm in size will be chosen (beyond this limit the success rate is much lower). After gallstone fragmentation, litholytic therapy is continued for about 3-6 months (until all the small fragments resulting from lithotripsy are no longer seen by ultrasound).

Practically, the two techniques have lost ground over the past 10-15 years, with the increasingly good results of laparoscopic cholecystectomy (hospitalization for 3-4 days, rare complications, mortality close to 0). Patients who ask for drug litholysis must be informed of its advantages, but also of costs, failures and post-dissolution recurrences.

In *conclusion* to the chapter on gallstones, we should mention that ultrasound is a sensitive (95-96%) diagnostic method for this disease. After imaging diagnosis, anamnesis and clinical examination will determine the *symptomatic or asymptomatic* nature of the disorder, which will allow for a correct therapeutic approach.

5. Acute cholecystitis

Definition: it is an acute inflammation of the gallbladder wall. Acute cholecystitis most frequently occurs on the background of gallstones – acute lithiasic cholecystitis. Acute non-lithiasic cholecystitis (generated by germs such as Salmonella, Escherichia coli, fecal streptococcus, etc.) is much more rare. Acute ischemic cholecystitis may also occur after surgery, chemoembolization or after tumor percutaneous ultrasound guided therapy (PEIT, PAAI or RFA).

The clinical presentation of acute cholecystitis is typical in most patients. Intense pain in the right hypochondrium and/or epigastrium (frequently with right subscapular radiation), fever, chills - the sepsis signs depend on the severity of acute cholecystitis. Clinical exam will show pain on palpation in the right hypochondrium (Murphy's sign), which can lead to muscular defense. In most cases, the general state of the patient is altered, but we also found cases of paucisymptomatic acute

cholecystitis in patients with a history of biliary colics and most frequently, previously diagnosed gallstones.

The ultrasound diagnosis in acute cholecystitis is typical and consists of the thickening doubling of the gallbladder wall (Figs. 2.24, 2.25). A normal gallbladder wall is 4 mm thick. In acute cholecystitis, due to edema, it can be 6-8 mm (even 10 mm) thick. The doubled aspect of the gallbladder wall with a sandwich appearance is quite common and typical (Fig. 2.26). In addition to the parietal changes, inflammatory pericholecystic exudate can be found, which appears as an anechoic or hypoechoic band. The amount of pericholecystic exudate is usually minimal (appearing as an anechoic "eyebrow"). In other cases, it is obvious on ultrasound. It is due to a localized peritoneal reaction and more rarely to generalized peritonitis. The integrity of the gallbladder wall should be assessed. Parietal discontinuities are sometimes found, which suggest gallbladder perforation.

The diagnosis of gallbladder perforation is difficult. It is easier if the perforation occurs into an aerated digestive organ (duodenum, intestine, colon) resulting in a bilio-digestive fistula and thus air will permeate into the gallbladder appearing as a hyperechoic image in the upper part of the organ, mobile with the patient's movements. Air in the gallbladder can also be found in acute cholecystitis generated by gas forming bacteria. When gallbladder perforation is suspected, 3D ultrasound can be useful to demonstrate gallbladder wall discontinuity, or CT scan can evidence the air in the gallbladder.

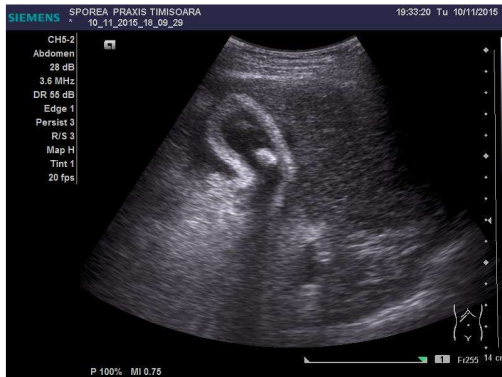

Fig. 2.24 Double layered gallbladder wall - acute cholecystitis

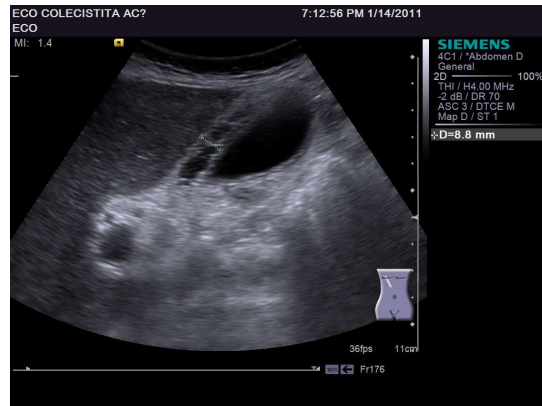


Fig. 2.25 Double layered gallbladder wall - acute cholecystitis

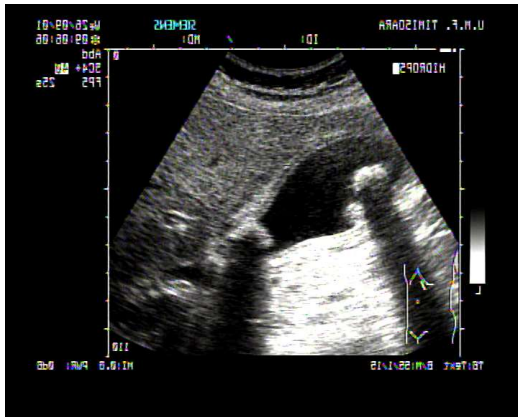


Fig. 2.26 Thick gallbladder wall, gallstones

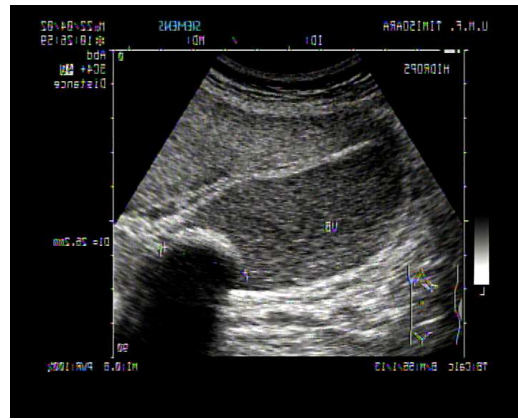
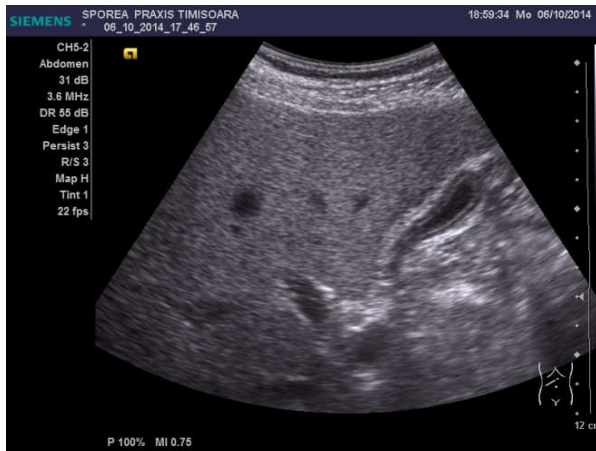

Fig. 2.27 Gallstone impacted in the infundibulum, thick gallbladder wall

Given that in acute cholecystitis gallstones are most frequently involved, their presence or of a calculus impacted in the infundibulum should be demonstrated by ultrasound (Fig. 2.27). A calculus in the infundibulo-cystic area is one of the most frequent causes of acute cholecystitis, because the resulting gallbladder hydrops favors gallbladder ischemia and allows flora exacerbation with the inflammatory phenomena. In some cases an inhomogeneous echoic material can be seen along with gallstones, which can be either biliary sludge or pus (gallbladder empyema). In addition to inflammatory parietal phenomena, the presence of gallbladder empyema is frequent in acute cholecystitis. A common ultrasound sign found in acute cholecystitis is Murphy's sign (the pressure of the transducer on the gallbladder will cause intense pain).



of the transducer on the gallbladder will cause intense pain).

Fig. 2.28 Postprandial doubled gallbladder wall

The ultrasound differential diagnosis of acute cholecystitis should be made in the first place with chronic cholecystitis (in which the gallbladder wall is thicker and hyperechoic, but not doubled). Another difficult differential diagnosis involves the thickened and doubled gallbladder wall that can occur in cirrhosis, acute viral hepatitis, nephrotic syndrome, chronic renal failure and heart failure. The gallbladder wall appears thickened and doubled also in HIV infection (a clinically inapparent gallbladder infection, often with opportunistic germs). Postprandial, the gallbladder wall also appears as doubled (sandwich appearance) (Fig. 2.28), but not thickened (anamnesis will allow to differentiate between a lithiasic gallbladder, postprandially altered, and acute cholecystitis) also ultrasound Murphy's sign is negative.

The most difficult ultrasound differential diagnosis is between acute lithiasic cholecystitis and a thickened and doubled gallbladder wall in a patient with gallstones and liver cirrhosis (in 1/3 of liver cirrhosis cases, gallstones may be present, mostly asymptomatic). The most useful element is the presence or absence of ultrasound Murphy's sign. If violent pain is induced by the contact of the transducer with the gallbladder area, acute cholecystitis is highly probable. In our clinical and ultrasound experience of more than 25 years, acute lithiasic cholecystitis in cirrhosis is exceptional. Fortunately, the majority (more than 90%) of the cases of gallstones in cirrhosis are asymptomatic and do not generate complications.

In a clinical suspicion of acute cholecystitis, in addition to classic ultrasound examination with a 3.5 MHz transducer, 5 MHz linear transducer may be used for a higher accuracy. Also, harmonic ultrasound can be used for a clearer visualization of the gallbladder wall and content. CT scan can be useful in difficult cases. Biological tests (leukocytosis, the presence of inflammatory syndrome) may be helpful. Other tests should be used for differentiation from diseases with similar clinical signs (i.e. 3-fold increased serum lipase, for the diagnosis of acute pancreatitis).

In clinical practice, the most difficult diagnostic problems are raised by acute non-lithiasic cholecystitis. Due to its relative rarity (patients in shock or in intensive care, after corticotherapy, but frequently without an obvious cause), this pathological entity is underestimated. However, in the presence of an acute clinical presentation of painful right hypochondrium with fever and an ultrasound appearance of gallbladder with no gallstones but with a thickened and doubled wall, the diagnosis of acute non-lithiasic cholecystitis should be considered. The biological tests will confirm leukocytosis and inflammatory syndrome. The therapeutic approach is difficult to decide in these cases. In acute lithiasic cholecystitis, the surgical indication is clear. In acute non-lithiasic cholecystitis, cholecystectomy will be delayed or avoided in most cases. Parenteral antibiotic treatment should be started. Clinical monitoring (local pain disappearance, as well as of local defense and fever), and close ultrasound monitoring will allow to delay surgery, intending to avoid cholecystectomy if possible.

Treatment of acute lithiasic cholecystitis is surgical, which can be performed in emergency or as a delayed emergency. Gallbladder hydrops, even is asymptomatic, also requires cholecystectomy due to the risk of subsequent major complications. There are cases of severe acute cholecystitis in which surgery is contraindicated (severe cardiac or coronary disease, severe respiratory failure, etc.). In these cases and particularly in gallbladder empyema that must be evacuated, percutaneous ultrasound guided drainage of the gallbladder can be performed. Pigtail drain tubes of 10-12 F (3-4 mm) are used, which are placed into the gallbladder under ultrasound guidance (preferably by transhepatic route). The gallbladder pus will be drained, septic conditions will be improved and, depending on the evolution, the best approach for the patient will be adopted.

6. Chronic cholecystitis

Definition: chronic inflammation of the gallbladder wall that occurs in the presence of gallstones.

Gallstones are accompanied in some cases by chronic inflammation of the gallbladder wall. This relationship is not necessarily present; some cases cholecystectomized for gallstones have a

macroscopically and microscopically normal gallbladder wall. The diagnosis of chronic cholecystitis can be suspected by ultrasound and is confirmed by pathological examination after cholecystectomy.

The ultrasound appearance in chronic cholecystitis consists of a thickening of the gallbladder wall exceeding 4 mm, most frequently with a hyperechoic appearance. When gallstones are diagnosed, it is important to perform an objective evaluation of the gallbladder wall. Many ultrasonographers tend to describe gallbladder wall changes when they detect gallstones even if they are less than visible. This approach is incorrect and can even be dangerous. We recommend a correct evaluation of the gallbladder wall by objective measurement (preferably the anterior gallbladder wall, ultrasound measurement being performed perpendicular to the wall) and an accurate evaluation of its echogenicity. These data are needed for the therapeutic approach, because asymptomatic and uncomplicated gallstones should only be clinically monitored. The type of surgery (classic or laparoscopic cholecystectomy) is decided depending on the state of the gallbladder wall. Laparoscopic cholecystectomy is more difficult in chronic inflammation of the gallbladder wall, when classic cholecystectomy is probably preferred.

The ultrasound differential diagnosis of chronic cholecystitis should be made with: acute cholecystitis, gallbladder cholesterosis, gallbladder adenomyomatosis, early gallbladder cancer, porcelain gallbladder.

Porcelain gallbladder is a particular situation characterized by the partial or complete calcification and thickening of the gallbladder wall. It is considered as a precancerous state, thus having an indication of cholecystectomy, even if asymptomatic. It should be differentiated from the so-called "limy bile", a condition in which only the bile is hypercalcic, without gallbladder wall changes. The ultrasound diagnosis of the porcelain gallbladder is established based on the detection in the gallbladder area of a hyperechoic crescent that generates a marked posterior shadow. The calcified gallbladder wall may have a variable thickness. The porcelain gallbladder should be differentiated from a gallbladder filled with stones or a large stone that completely fills the gallbladder.

In diagnostic uncertainty regarding the porcelain gallbladder, plain abdominal X-ray is recommended, which will demonstrate calcifications of the gallbladder wall (possibly scopic control with image enhancer). Computed tomography can also be performed, which will accurately assess the extension of parietal calcification areas. In case of a limy bile, the plain abdominal X-ray will reveal an appearance similar to that of the gallbladder after administration of a radiopaque contrast agent. Since porcelain gallbladder is considered to be a condition that favors gallbladder carcinoma, all the measures required for diagnosis will be taken, given the need for prophylactic cholecystectomy in this case.

7. Gallbladder carcinoma

Definition: it is a gallbladder cancer. It may be polypoid or schirrhous - infiltrating the gallbladder wall.

Gallbladder cancer is a relatively rare entity, taking into account the high number of gallstones in the general population. The direct relationship between gallstones and gallbladder

carcinoma must be emphasized. The association of carcinoma with gallstones is described in 80-100% of the cases, thus, gallstones can be considered as a condition favoring gallbladder carcinoma. This is true, but particularly rare (almost exceptional), occurring particularly in patients aged over 70 years. Considering that the risk of gallbladder cancer is extremely low, prophylactic cholecystectomy is not justified in all gallstones cases (the risk of perioperative morbidity and mortality exceeds the risk of carcinoma). This is why the practical approach is the same as discussed in relation to gallstones, according to which only symptomatic gallstones will be treated by surgery.

The clinical presentation of gallbladder carcinoma is most frequently non-characteristic or asymptomatic. It is frequently detected by ultrasound in patients with persistent pain or discomfort in the right hypochondrium or, more rarely in patients with biliary colic. Additional symptoms may be weight loss or, in more advanced disease, jaundice due to liver invasion.

The ultrasound appearance of gallbladder carcinoma is not typical, depending on its form (polypoid or scirrhous), as well as on the time of diagnosis. In the early phases, polypoid gallbladder cancer appears as an endoluminal excrescence of variable size, similar to a gallbladder polyp. In small sizes, less than 1-1.5 cm, it is almost impossible to differentiate a gallbladder polyp from a carcinoma. It has a parenchymal echogenicity (Fig. 2.29), and when examined with a 5 or 7.5 MHz transducer it will show an irregular outline, unlike a larger gallbladder polyp. In scirrhous carcinoma forms that infiltrate the gallbladder (Fig. 2.30), the imaging diagnosis is particularly difficult, given the frequent association with gallstones. The ultrasound differential diagnosis with chronic or acute cholecystitis may raise serious problems. The gallbladder wall is thick, anfractuous, irregular, thickening is usually much more obvious and irregular as compared to cholecystitis. In advanced forms, a limit between the gallbladder and the liver cannot be established (hepatic neoplastic invasion) (Fig. 2.31). In these cases, the palpation of the gallbladder area usually reveals a hard tumoral liver.

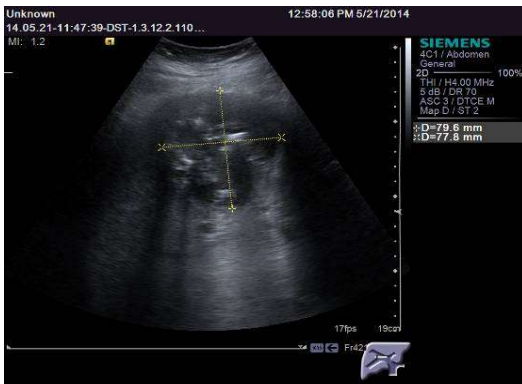

Fig. 2.29 Gallbladder carcinoma

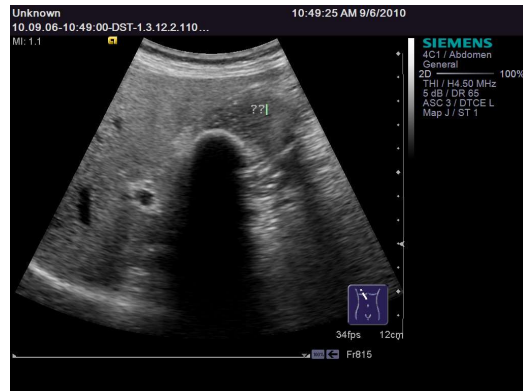


Fig. 2.30 Gallbladder carcinoma

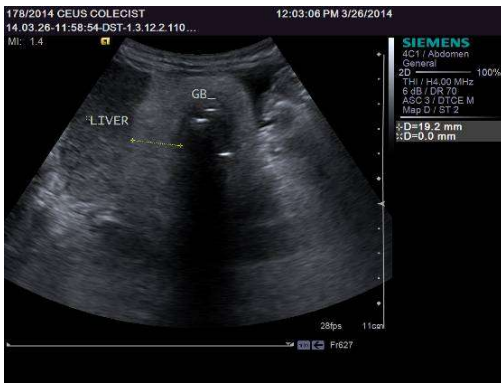

Fig. 2.31 Gallbladder carcinoma - liver invasion

Practically, either a protrusive mass larger than 1.5-2 cm is found in the gallbladder, or there is a marked thickening of the gallbladder wall (particularly eccentric). The presence of both on a gallstones background raises the suspicion of a gallbladder carcinoma. Other useful investigations for diagnostic are: harmonic ultrasound (more precise delimitation of the mass), power Doppler for the study of tumor vascularization, CEUS (showing vascular enhancement of the tumor, followed by washout during the venous and late phases), CT or MRI.

The positive diagnosis, particularly in early stages, is frequently difficult. However, because of the high growth and invasion rate of this type of carcinoma, cholecystectomy is preferred when there is the slightest suspicion. Even in an unconfirmed suspicion, given that gallbladder cancer may occur on the background of gallstones, cholecystectomy will not be an important error. In contrast, delaying surgery in a small carcinoma will lead to the invasion of the gallbladder bed to local and regional metastases, making subsequent intervention useless.

Sometimes, a tumor mass surrounding the gallstones will be found by ultrasound (Fig. 2.32). This is an invasive gallbladder carcinoma, extending into the liver structure. The tumor mass most frequently has a rosette appearance, but sometimes it can be inhomogeneous, hypoechoic. In invasive gallbladder carcinoma, loco-regional liver metastases may also be detected on ultrasound.

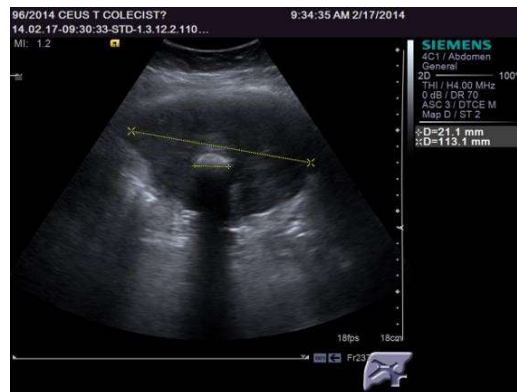


Fig. 2.32 Tumor mass surrounding gallstones in the gallbladder bed

The ultrasound differentiation of gallbladder carcinoma should be made with large gallbladder polyps, ball-like or tumor-like biliary sludge, gallbladder wall changes in acute or chronic cholecystitis.

Practically, in the slightest suspicion of a gallbladder cancer, the solution is cholecystectomy, which will clarify the diagnosis and will also allow the loco-regional invasion assessment.

8. Post-cholecystectomy disorders

Definition: all early or late symptoms following cholecystectomy.

The prevalence of post-cholecystectomy disorders depends on the correctness of gallstones diagnosis and on their accurate classification as symptomatic or asymptomatic.

Ultrasound is the standard diagnostic method for gallstones, having 90-96% sensitivity depending on the examiner's experience. The correct diagnosis of gallstones should be followed by a correct, detailed anamnesis and an objective examination that will allow to estimate gallstones as symptomatic or not (presence or absence of biliary colic). Classic or laparoscopic surgery in symptomatic gallstones is the rule, and immediate and long-term results are generally good (few symptoms such as dyspeptic syndrome through biliary reflux, postprandial diarrhea with green stools, etc.). A false positive diagnosis of gallstones (i.e. confusion of duodenal air with gallstones) or surgery in asymptomatic gallstones (for a headache syndrome) will lead to unpleasant immediate and long-term results. On the other hand, cholecystectomy will not resolve the headache, but drug therapy, which influences the vasomotricity of cerebral vessels.

It is difficult to differentiate post-cholecystectomy disorders generated by a wrong surgical indication from disorders generated by postoperative complications.

Early complications are: damage of the extrahepatic bile ducts during surgery, with the possible appearance of bile peritonitis, perihepatic bile collection, biloma or seroma of the gallbladder bed. Ultrasound will demonstrate in these cases the presence of localized fluid collection.

Late complications: bile duct stenosis after accidental intraoperative lesion and choledocholithiasis. It is relatively difficult to detect these complications by ultrasound. If a cholecystectomized patient complains of typical biliary colic symptoms, ultrasound examination will be performed, which may show dilated intrahepatic ducts (even if slightly dilated) that can underlie a posttraumatic fibrotic lesion of the main bile duct (MBD). A normal ultrasound appearance may also be seen. In order to help diagnosis, biological cholestasis tests should be performed: alkaline phosphatase, gamma-glutamyl transpeptidase and bilirubin (in a cholestatic hepatic disorder, GOT and GPT will also be increased). If cholestasis is found, suspicion of bile duct lesion or choledocholithiasis is reinforced. Cholestasis can be anicteric (with normal bilirubin) or icteric (with elevated bilirubin). *Cholestasis* can be *intrahepatic* (after drug therapy, in primary biliary cirrhosis, etc.), with non-dilated intrahepatic bile ducts, or *extrahepatic* (through choledocholithiasis, Vater's ampulloma, pancreatic head neoplasm, choledocolithiasis, etc.), with dilated intra- and extrahepatic bile ducts.

Ultrasound is a sensitive method for diagnosing dilation of bile ducts, but it is less sensitive regarding the etiology of these dilations. Even if a main bile duct stone is present, the chance to detect it by ultrasound is 50-70%. The ultrasound examination must be performed by an experienced ultrasonographer, who will thoroughly examine the case, with a high end ultrasound machine. Ultrasound will be followed by endoscopic ultrasound - the most sensitive non-invasive method, MRCP (magnetic resonance cholangiopancreatography). ERCP (endoscopic retrograde cholangiopancreatography), will also diagnose a possible stone, but its purpose is therapeutic endoscopic sphincterotomy with stone extraction.

In current practice, ultrasound is performed to find changes that can explain post-cholecystectomy disorders. Cholestasis tests are useful. If positive, they increase the probability of organic pathology. A careful ultrasound assessment of the intrahepatic bile ducts and of the entire main biliary duct may show an underlining disease. Main biliary duct stones will appear as hyperechoic images with "posterior shadow" (beam attenuation) (Figs 2.33 and 2.34). However, the diagnosis of choledocholithiasis is almost impossible in bilio-digestive derivations, where hyperechoic air in the bile ducts will prevent stones visualization. In these cases, MRCP is preferred for the diagnosis of choledocholithiasis. If choledocholithiasis is seen by ultrasound or in the case of difficult evaluation, ERCP will be used to continue the assessment and therapy.

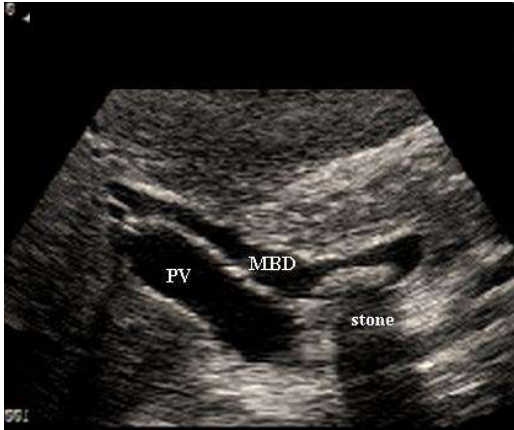

Fig. 2.33. Main biliary duct stone

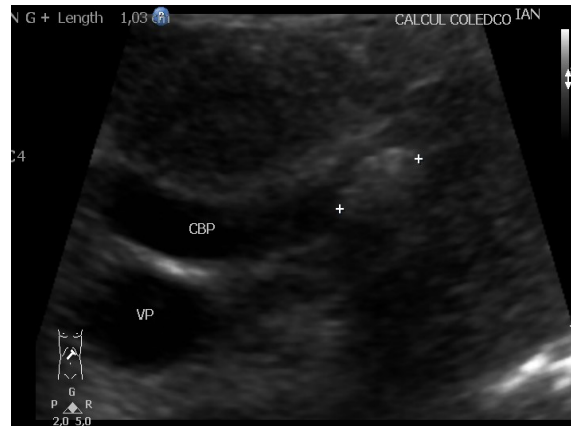


Fig. 2.34. Main biliary duct stone

The results of endoscopic therapy in choledocholithiasis, in experienced centers, show a success rate higher than 90%, even if the stones are multiple or large (for which mechanical or shock wave lithotripsy is also used). Considering all these, surgery in choledocholithiasis is reserved for cases in which endoscopic procedures have failed.

After common bile duct clearance, biological cholestasis will be monitored, which will normalize in several days if no other calculi or bile duct stenosis are present. If there are no residual stones, the persistence of cholestasis can be the consequence of main biliary duct stenosis, which requires diagnostic exploration by another ERCP and possibly, biliary stenting.

Ultrasound in biliary pathology is an easy method, but it involves some traps. Diagnostic errors in gallstones are possible, with false positive as well as false negative results, depending on examiner's experience.

Performing a minute examination, based on a long ultrasound experience, will result in fewer errors. The preoperative examination of the main biliary duct or after cholecystectomy is a real challenge for the ultrasound practitioner. Evidencing the main biliary duct along its entire length, estimating its size (normal choledochus less than 6 mm in diameter in non-cholecystectomized patients and less than 7-8 mm following cholecystectomy) are important stages for the ultrasound diagnosis of choledocholithiasis. Ultrasound examination in biliary pathology will start from a clinical suspicion and will end with the possible recommendations for complementary diagnostic methods, mentioned on the ultrasound form.

CHAPTER 3

THE PANCREAS

Pancreatic ultrasound is the touchstone of ultrasound exploration. This is why the examination of this organ is a permanent stress for beginners in ultrasound. Hundreds or thousands of explorations are still required before the examination of the normal or pathological pancreas is no longer a challenge for the ultrasound exploration.

The first tens/hundreds of pancreas examinations will be a nightmare for the inexperienced ultrasonographer. In order to shorten the uncertainty period, the beginner in ultrasound should spend sufficient time learn to see the pancreas and its adjacent landmarks. First, the anatomical landmarks delimiting the pancreas (the spleno-portal axis, the superior mesenteric vein, the relationship with the omental bursa and the gastric antrum) should be studied using anatomy atlases. All the available materials (atlases, videotapes, CD-ROMs) will be used to study the ultrasound appearance of the pancreas and its relationship with the adjacent organs. Then, patient examination will follow, using at first transverse epigastric sections. A 3.5 MHz (or multi-frequency) convex transducer is preferred; for thin (or cachectic) persons, a 5 MHz linear transducer is needed.

The exploration of the pancreas should be performed on a fasting patient. Food in the stomach may prevent the correct and complete exploration of the organ or may create false pancreatic tumor images. The fasting period is 7-8 hours. Patient will not have breakfast if the examination takes place in the morning or will stop eating after 8-9 p.m. if the examination takes place in the afternoon. Liquids are allowed, but fizzy drinks are forbidden (air in the stomach will make pancreatic examination difficult).

The examination of the pancreas should start through a transverse epigastric section that will detect the spleno-portal axis (the portal vein and the splenic vein), which delimits the pancreas posteriorly (Fig. 3.1.). The pancreas is delimited anteriorly by the gastric antrum or the left liver lobe (depending on the level at which the transverse section is performed) (Fig. 3.2.). The pancreas will be examined above the gastric antrum (if the transducer is at a high level in the epigastrium), through the stomach, or more rarely, below the antrum (the position of the transducer is midway between the xiphoid appendix and the umbilicus).

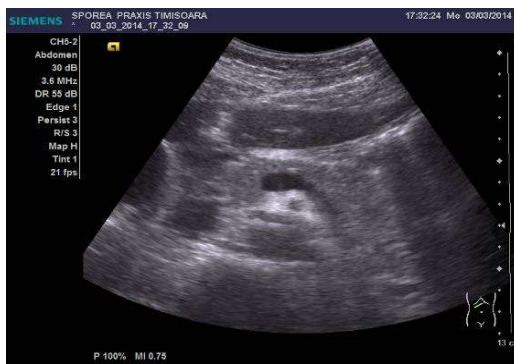

Fig. 3.1 Normal pancreas

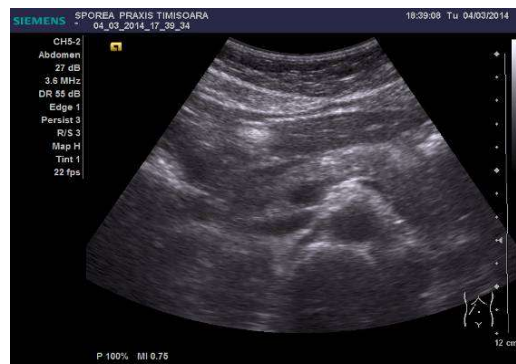

Fig. 3.2 Normal pancreas

The best ultrasound view for the pancreas is obtained through high sections (avoiding the colon), through the left liver lobe (which acts like an ultrasound window for the pancreas), or through the stomach. For transgastric pancreatic assessment, the stomach (antrum) should contain liquid but not air. Liquid in the stomach plays the role of an ultrasound window for the pancreas. If the pancreas is difficult to visualize, the patient will be asked to drink 500-700 ml plain water that will form an ultrasound window in the stomach. The examination will start 10-15 minutes after ingestion, thus allowing the air bubbles formed during swallowing to disappear. If not, the stomach content will appear as hyperechoic (not anechoic) due to the air bubbling in the water during deglutition. After 10-15 minutes, the liquid inside the stomach will become anechoic. In some cases, no liquid will be seen in the stomach if the patient is in dorsal decubitus. In this case, the patient will be placed in a sitting position, so that water accumulates in the antrum, which is the ideal anterior landmark of the pancreas.

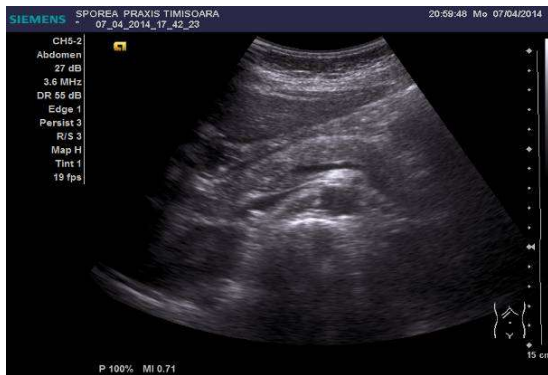

Fig. 3.3 Normal pancreas

All the technical artifices described above, together with a good ultrasound experience, allows pancreas' visualization in more than 90% of the cases. We also recommend continuous "training" for the exploration of the pancreas, i.e. attempting to correctly identify the entire pancreas in all ultrasound explorations, even if the patient is referred for renal or gallbladder ultrasound exploration.

During the ultrasound assessment, both the posterior landmark (the spleno-portal axis) and the anterior landmarks (the gastric antrum and the left hepatic lobe) should be seen, so that the pancreas parenchyma is identified in between. Normal pancreatic parenchyma has similar echogenicity to the liver (sometimes slightly hypoechoic). The pancreas can be slightly hyperechoic in obese (due to fatty loading) or in elderly (due to fibrosis). All these appearances are normal, provided that the pancreatic parenchyma is homogeneous (Fig. 3.3). A normal Wirsung duct can be visualized

particularly in young persons, with a diameter of up to 2 mm. Usually only a segment is seen, rarely along its entire length.

Usually a large portion of the pancreas is seen in a transverse section, but the entire pancreas is very difficult to see in one section. This is due to the slightly ascending trajectory of the pancreas tail. The transverse section usually enables a good assessment of the body and partially of the tail of the pancreas. For the examination of the head of the pancreas, sagittal sections are preferred, while for the pancreatic tail (particularly in a bulbous tail), left oblique recurrent subcostal sections are preferred.

Opinions differ regarding the normal size of the pancreas in its various segments. Thus, it is possible to find variable sizes for a normal pancreas according to various references. We do not consider the pancreatic size as very important because of its wide individual variability. The easiest to measure is the body of the pancreas, by anteroposterior measurement in transverse epigastric section. In general, the body of the pancreas has an anteroposterior diameter of 10-20 mm. The head of the pancreas is considered normal if the anteroposterior diameter is less than 30 mm. The tail of the pancreas is up to 20-25 mm, but a larger, bulbous tail, is relatively frequent. All these measurements have only a relative value, because the essential element for pancreatic ultrasound are structural changes.

The ultrasound assessment of the pancreas can be performed as part of a routine procedure, or as a targeted procedure, for instance for epigastric pain. The main pancreatic diseases that will be discussed are: acute pancreatitis, chronic pancreatitis, pancreatic cysts and tumors.

1. ACUTE PANCREATITIS

Definition: it is an acute inflammation of the pancreas, most frequently generated by alcohol abuse and/or gallstones. It is a potentially severe disease (with lethal cases in acute necrotic-hemorrhagic pancreatitis). However, the great majority of acute pancreatitis cases are mild, edematous forms.

The main *causes of acute pancreatitis (AP)* are *alcohol abuse* (acute alcoholic pancreatitis) and *gallstones* (acute biliary pancreatitis). The mixed biliary and alcoholic etiology is possible, the acute episode being triggered by a substantial meal associated with alcohol, in a patient with gallstones. The alcoholic and biliary etiology are responsible for 80-90% of acute pancreatitis cases. In 10-20% of the cases, AP may have other causes: drugs, mumps, severe hypertriglyceridemia, pancreatic trauma, ERCP (endoscopic retrograde cholangio-pancreatography), pancreatic anatomic anomalies (pancreas divisum), familial pancreatitis, etc. In general, acute pancreatitis can be classified as acute alcoholic pancreatitis (A), acute biliary pancreatitis (B), and non-alcoholic non-biliary (non-A non-B) acute pancreatitis.

The clinical presentation of acute pancreatitis is typical, characterized by "band-like" pain or epigastric pain, often with posterior radiation. The pain intensity can vary from mild to violent. Vomiting is frequently present. The alteration of the general state in variable degrees, with fever,

shock is possible, proportionally to the severity of AP. Hypotension, tachycardia are signs of severity. If AP is suspected, the following biological tests should be performed serum lipase, amylasuria, blood leukocytes, glycemia, calcemia. Lipase higher than 3 times the upper limit of normal in the presence of clinical signs, is a diagnosis criteria. Assessment of C reactive protein (CRP), leukocytosis, glycemia or calcemia is aimed at determining the severity of AP. CRP values higher than 150 mg% are considered to be prognostic for a severe form of AP.

Useful imaging techniques in AP are abdominal ultrasound (possibly contrast enhanced ultrasound) and computed tomography (CT), possibly ERCP (for sphincterotomy, in some cases of acute biliary pancreatitis).

The ultrasound appearance of AP is not always very suggestive. In mild edematous forms, ultrasound may not provide diagnostic data. The most typical element of AP is pancreatic edema, which causes an enlargement of the pancreas (Fig. 3.4) with a hypoechoic aspect (Fig. 3.5) (provided that the organ previously had normal echogenicity). The pancreatic outline becomes unclear and an enlarged hyperechoic omental bursa may be observed in severe necrotic forms (Figs. 3.6, 3.7). The omental bursa is a virtual cavity, delimited anteriorly by the stomach and posteriorly by the anterior margin of the pancreas. In acute necrotic-hemorrhagic pancreatitis, an enlargement and an increase in the echogenicity of the omental bursa occur through cytoosteonecrosis (Fig. 3.8). In AP, left pleural effusion and peritoneal effusions in various locations can be seen by ultrasound. The periparetic intestinal loops may be filled with anechoic fluid and are visible in peripancreatic areas.

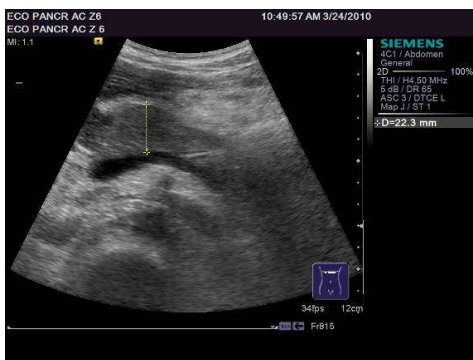

Fig. 3.4 Hypoechoic pancreas - acute pancreatitis

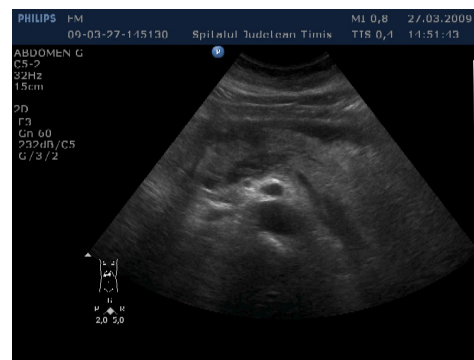


Fig. 3.5 Hypoechoic pancreas - acute pancreatitis

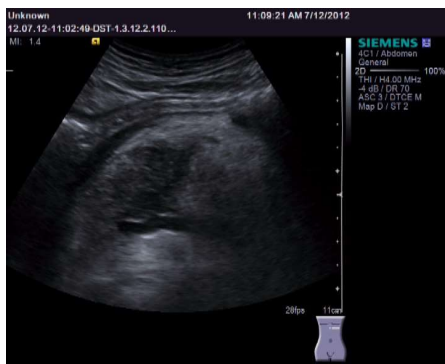

Fig. 3.6 Acute pancreatitis

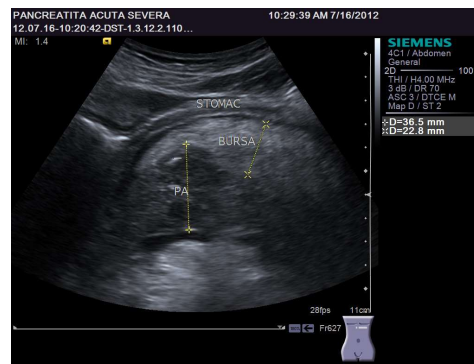


Fig. 3.7 Acute pancreatitis

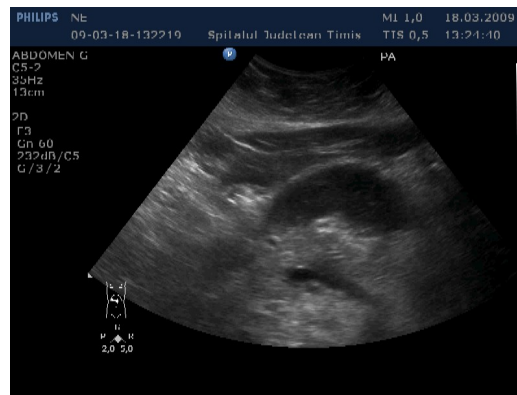


Fig. 3.8 Acute pancreatitis - collection
in the omental bursa

Sometimes, in AP the pancreatic area cannot be adequately assessed by ultrasound (air in the colon, pericolic loops, extreme obesity, very painful abdomen on pressure with the transducer, etc.). Frequently, this obstacle cannot be overcome by the use of a high performance ultrasound machines by an experienced ultrasonographer. In this case, CT is preferred, which will accurately assess the lesions.

Biliary assessment in AP is useful for defining its etiology. First, potential gallstones should be searched for, which can involve small calculi or, more rarely, only biliary sludge, possibly with cholesterol macro-crystals. The assessment of the main bile duct (MBD) is difficult in AP. A potential dilation due to a gallstone should be searched for. If the MBD is dilated (as well as in all cases of suspected acute biliary pancreatitis), endoscopic ultrasound is the method of choice to evaluate the MBD.

The value of ultrasound in the diagnosis of AP should be interpreted in a known clinical context, when along with clinical (pain) and biological elements (lipase), ultrasound examination supports diagnosis and allows to assess severity. The diagnostic elements are: enlarged, hypoechoic pancreas; hypoechoic pancreatic areas of tissue necrosis; enlarged hyperechoic omental bursa; fluid collections around the pancreas or at a distance (parieto-colic gutters). Ultrasound is extremely

useful for assessing the evolution of AP, for monitoring the pancreatic size, the disappearance of peripancreatic (or distant) fluid collections, or the appearance of pseudocysts.

Contrast enhanced ultrasound (CEUS) on the 4th day after pain onset has lately been proposed for pancreatic necrosis assessment in severe acute pancreatitis. Seconds after SonoVue bolus, the pancreas enhances, but necrotic areas will not enhance (allowing to assess the extension of necrotic areas).

The contribution of **computed tomography** to the staging of AP is unquestionable, so that it is recommended in all severe AP cases, in which CEUS could not be performed or was irrelevant.

If ultrasound examination in AP has its limitations, CT is the gold standard. It can assess pancreatic size, necrotic areas, the changes in the omental bursa, fluid effusions. CT also evaluates the signs of chronic pancreatitis existing prior to the acute episode (such as pancreatic calcifications or even microcalcifications) as well as pseudocysts.

Some authors recommend to perform **ERCP** (retrograde endoscopic cholangiopancreatography) early after the onset of biliary acute pancreatitis, within 72 hours. It will enable the diagnosis of a potential MBD or papillary stone, and endoscopic sphincterotomy through its decompressive effect is beneficial for the prognosis of severe acute biliary pancreatitis.

AP should be monitored clinically, biologically, by ultrasound and CT. The return of biological test values to normal, along with a pancreas that becomes normal by US are signs of a positive evolution. In some situations, peripancreatic collections or pseudocysts (anechoic lesions with hyperechoic walls) may be observed, whose size and evolution can be monitored by ultrasound (Figs. 3.9, 3.10). If these lesions are not completely anechoic and if there is a suspicion of pancreatic abscess (a hypo/anechoic lesion), ultrasound guided fine needle aspiration should be performed. Fluid culture or slide examination will allow to evaluate fluid infection. Then, the collection can be drained by ultrasound guided placement of a drain tube.

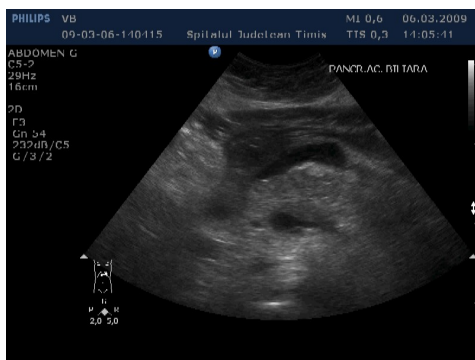


Fig. 3.9 Acute pancreatitis –peripancreatic peripancreaticcollection

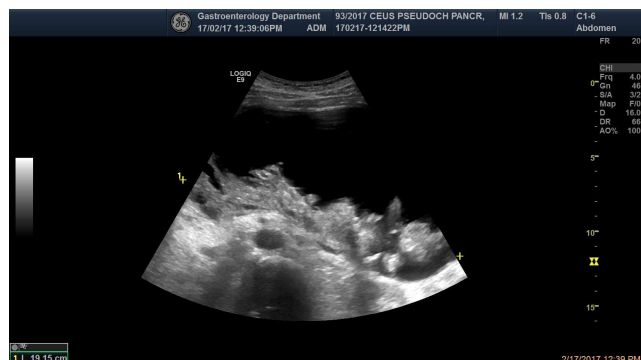

Fig. 3.10 Acute pancreatitis - collection

2. CHRONIC PANCREATITIS

Definition: it is a chronic inflammation of the pancreas that evolves towards progressive destruction of the organ, accompanied by parenchymal calcifications, and dilatation of the Wirsung duct.

The *etiology* of chronic pancreatitis (CP) involves chronic alcohol abuse as the main factor. Other etiological factors are less common: hyperparathyroidism, chronic familial pancreatitis, etc. In more than 90% of cases, the cause is chronic alcohol consumption (years) in pathological doses. The toxic dose for the pancreas is higher than 60-70 grams pure alcohol/day for men and 30-40 grams/day for women.

The clinical presentation of CP is not always the same. CP can be completely asymptomatic, being detected incidentally, within an ultrasound exploration. Clinical signs include diffuse or epigastric abdominal pain. The pain can be "band-like" or with posterior radiation. Pain exacerbation occurs especially in acute episodes, generated in particular by alcohol consumption. Pain can also be exacerbated by a high fat diet. Vomiting is frequent and may be related to digestive obstruction due to a hypertrophic pancreas. Other clinical signs are steatorrhea and progressive weight loss.

The diagnosis of CP is clinical and paraclinic. Paraclinic tests include biological and imaging tests.

Biological tests in CP show pancreatic involvement. For the specific testing of pancreatitis, serum lipase (which is organ specific) is preferred. In CP, this enzyme does not have very high values.

Functional pancreatic tests can be indirect and direct tests. *Indirect tests* include the pancreolauryl test and the PABA (para-aminobenzoic acid) test. These tests demonstrate the pancreas insufficient secretory function after administration of substrates such as pancreolauryl or PABA. *Direct tests* include the secretin test and the Lundt test, which consist of collecting pancreatic juice and measuring its pancreatic enzyme and bicarbonate content. They are rarely used in current clinical practice.

Another functional test in chronic pancreatitis is *fecal elastase 1* (an easy, sensitive modern test), which diagnoses pancreatic disease even in its early stages. Measurement of steatorrhea over 24 h is a useful test, which shows pancreatic lipase insufficiency (it is considered to be pathological, if lipid excretion is higher than 7 g lipids/day after normal eating).

Glycemia is determined or, if the values are normal, OGTT (oral glucose tolerance test) can be performed in order to diagnose secondary diabetes mellitus.

Imaging methods in CP

Imaging in CP will establish the diagnosis and will evaluate the lesions' extent. The following tests are useful: plain abdominal X-ray, standard abdominal ultrasound, spiral computed tomography, endoscopic ultrasound, MRCP (MR cholangio-pancreatography) and ERCP. Imaging changes also depend on the *type of CP*: *calcific* (where parenchymal calcifications are dominant) or *obstructive* (where the obstruction of the Wirsung duct is dominant).

Plain abdominal X-ray focused on the pancreatic region will reveal in about 1/3 of the cases the presence of pathognomonic pancreatic calcifications.

Abdominal ultrasound is a useful diagnostic method in CP. It may establish the diagnosis of CP in an asymptomatic patient (incidental detection), or it may be part of the work-up in a patient with clinical abdominal complaints.

The ultrasound assessment of CP requires an experienced examiner, with hundreds or thousands of ultrasounds performed, allowing him to see the pancreas in almost all the examined patients. The examiner should be familiar with the normal appearance of the pancreatic parenchyma (in all its variants), with Wirsung duct assessment (1-2 mm in size in normal cases), and with changes that can be seen regarding the pancreas outline and structure (assessment of abnormal pancreatic heterogeneity or parenchymal calcifications).

It is mandatory to visualize by US all parts of the pancreas (head, body and tail) in order to be able to see all possible segmental changes or pancreatic pseudocysts. Epigastric transverse and sagittal sections are used with the inferior vena cava and the aorta as landmarks. Thus, the pancreatic isthmus is found before the inferior vena cava (so, the head of the pancreas is situated to the right of the vein), and the body of the pancreas is found before the aorta (thus, the tail of the pancreas is situated left of the aorta).

When it is difficult to visualize the entire pancreas, 500-700 ml plain of water will be administered, which will form an ultrasound window in the gastric antrum, enabling the correct anterior delimitation of the organ.

Ultrasound changes in CP are parenchymal structure changes and duct changes. In chronic pancreatitis, the *parenchymal structure* will be inhomogeneous due to fibrotic areas (Fig. 3.11). *Pancreatic calcifications* may also be seen. Usually they are small, difficult to see by ultrasound, but sometimes they are large, generating a posterior shadow (Figs. 3.12, 3.13). The *pancreatic outline* can be irregular. The pancreas can be slightly enlarged or, on the contrary, it can be smaller in atrophic CP.

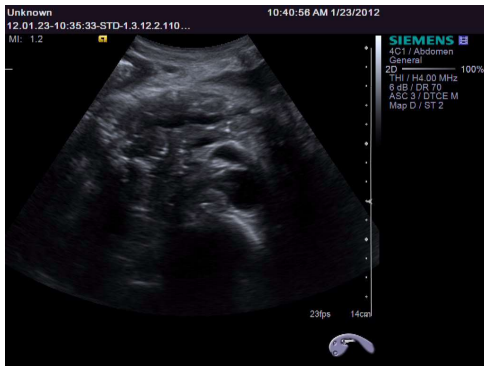

Fig. 3.11 Chronic pancreatitis - parenchymal heterogeneous structure, large Wirsung duct

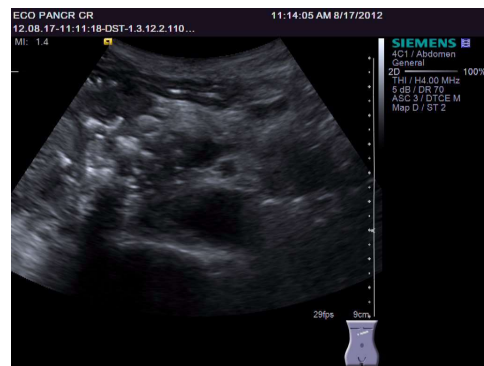


Fig. 3.12 Chronic pancreatitis, pancreatic calcifications

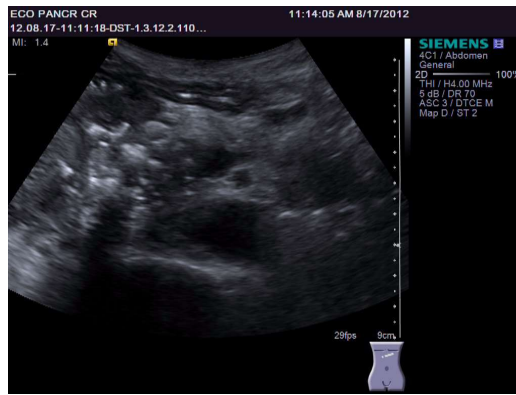

Fig. 3.13 Chronic pancreatitis,
pancreatic calcifications

Changes in the Wirsung duct may occur in chronic obstructive pancreatitis. The duct appears as "too visible" in some cases, because of its enlargement (Figs. 3.14, 3.15). In severe forms, it is extremely large, 7-9 mm in diameter (Figs. 3.16, 3.17), and may completely replace the pancreatic parenchima.

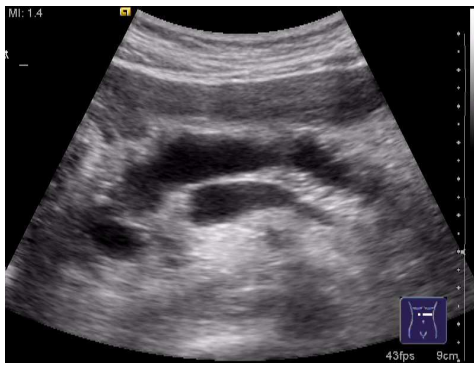


Fig. 3.14 Chronic pancreatitis,
large Wirsung duct

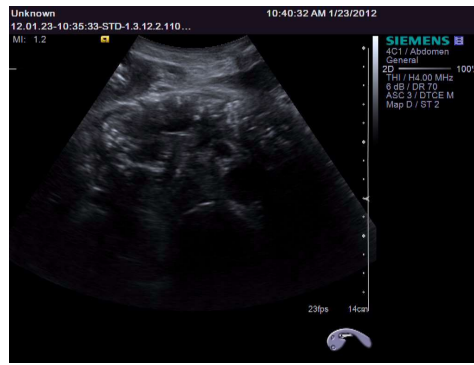

Fig. 3.15 Chronic pancreatitis,
large Wirsung duct

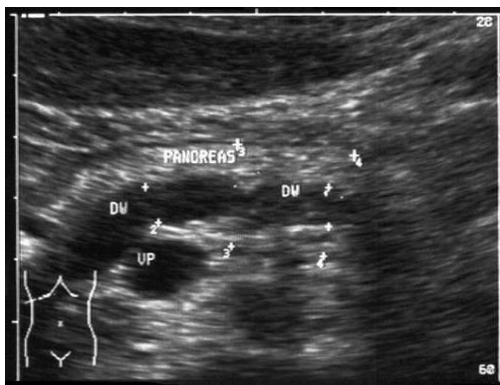


Fig. 3.16 Chronic pancreatitis,
extremely large Wirsung duct

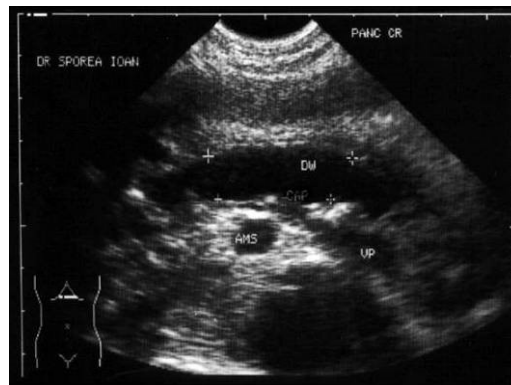


Fig. 3.17 Chronic pancreatitis,
extremely large Wirsung duct

In most cases, Wirsung duct is irregular, with enlargements and narrowings. Anyway, when a Wirsung duct larger than 2 mm is seen, or when it has an irregular, sinuous trajectory, the diagnosis of chronic pancreatitis is highly probable. Stones of different sizes up to 10 mm that generate a marked posterior shadow are frequently found in the Wirsung duct in CP (Figs. 3.18, 3.19, 3.20).

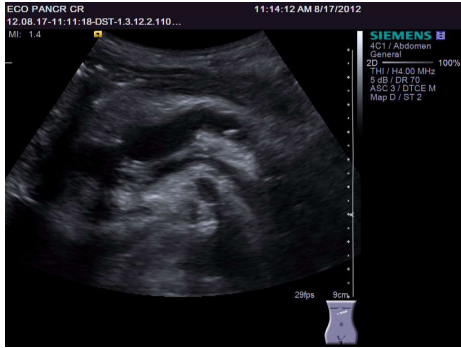

Fig. 3.18 Chronic pancreatitis, stones in the Wirsung duct

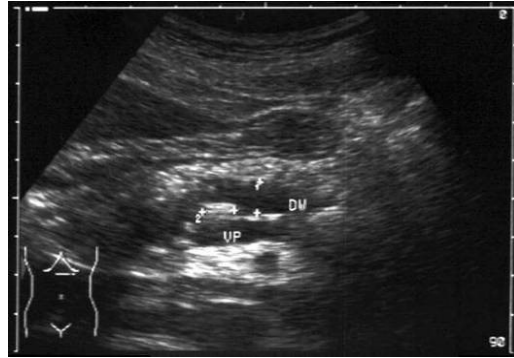


Fig. 3.19 Chronic pancreatitis, stones in the Wirsung duct

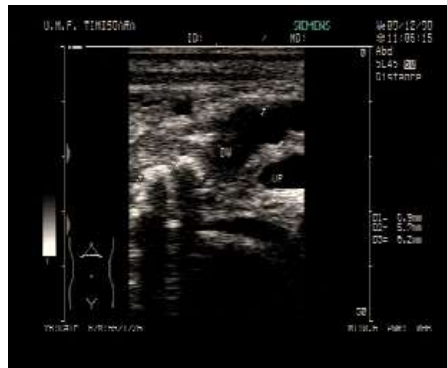

Fig. 3.20 Chronic pancreatitis, stones in the Wirsung duct

An inexperienced ultrasonographer may confuse the spleno-portal axis or the splenic artery with a dilated Wirsung duct. In order to differentiate the two, the spleno-portal axis must be detected, possibly by following the portal vein up to the hilum. The splenic artery must be followed from its origin from the celiac trunk. These vascular elements will be very easy to be visualized using color Doppler or power Doppler.

In some cases of CP, a hypertrophic head of the pancreas, 4-5 cm in size, will be detected. In this case, it is relatively difficult to distinguish a chronic cephalic pancreatitis from a pancreatic head cancer. The absence of a hypoechoic area (present in pancreatic cancer) can be useful. CEUS may help differentiation (hypoechoic tumor). An increased CA 19-9 is useful for a positive diagnosis of pancreatic cancer.

In all cases of CP, the MBD should also be evaluated. Sometimes, CP is accompanied by compression of the MBD and development of obstructive jaundice. The MBD will be measured in the hilum, where its diameter must be smaller than 7 mm, and the appearance of intrahepatic bile ducts will also be evaluated (whether they are enlarged or not).

The *presence of pancreatic pseudocysts* is quite common in CP. They appear as anechoic lesions, with hyperechoic walls, with different locations and sizes (Figs. 3.21, 3.22, 3.23).

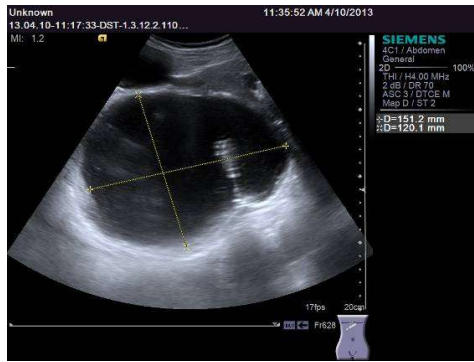


Fig. 3.21 Pancreatic pseudocyst

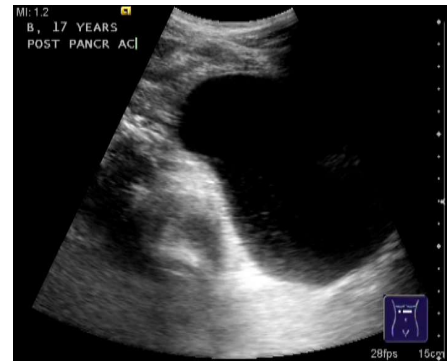


Fig. 3.22 Pancreatic pseudocyst

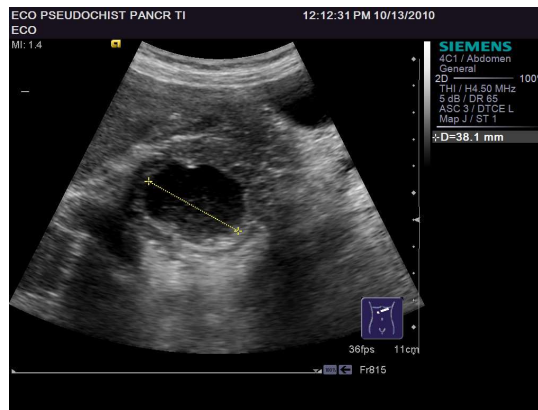


Fig. 3.23 Pancreatic pseudocyst

Pseudocysts in the body of the pancreas are easy to diagnose even for a beginner in ultrasound, but those of the head and tail of the pancreas may raise ultrasound diagnostic problems. For the head of the pancreas, sections perpendicular to the right costal margin are useful, they will show the MBD in the hilum, leading the investigation towards the head of the pancreas. For the tail of the pancreas, the presence of cysts in very distal locations could be a trap, especially in areas that are difficult to explore by ultrasound. In these case, the tail of the pancreas should be examined in procubitus using the ultrasound window of the left kidney.

Pseudocysts are measured and can be monitored for growth or resorption. Ultrasound guided diagnostic aspiration can be performed to differentiate it from cystadenocarcinoma or therapeutic cyst puncture is also possible. Based on the size of pseudocysts, the fluid volume of the cyst can be assessed (using the sphere formula) and the amount of pancreatic fluid that must be extracted can be estimated.

In the presence of a pancreatic pseudocyst, the problem arises whether it is a sequelae of acute pancreatitis or if it is a consequence of chronic pancreatitis (according to the Cambridge classification). We conducted a personal study in 30 patients with pancreatic pseudocysts detected by ultrasound. We used the Malfertheimer classification, which has additional imaging criteria (apart from pseudocysts) for the diagnosis of CP: enlargement of the Wirsung duct, pancreatic calcifications, pancreatic atrophy or hypertrophy, hypo- or hyperechogenicity of the pancreas, and irregular pancreatic outline. Using these criteria, we found that 9 out of 30 patients included in the study met other imaging criteria for chronic pancreatitis. In our group, 30% of the patients had pseudocysts as a complication of chronic pancreatitis and 70% of the cases had pancreatic pseudocysts as sequelae of an acute pancreatitis episode.

Pancreatic ascites may occur in 10-20% of the cases. It is an exudative, amylase-rich ascites. It can be located in different recesses or in the greater peritoneal cavity. Ascites developed in a patient with CP is considered to be part of the clinical presentation of the disease. In order to demonstrate it, exploratory paracentesis should be performed and the amylase content in the fluid will be measured (increased values for pancreatic etiology). Ultrasound guided paracentesis should be performed if the amount of fluid is small. The ultrasound aspect of pancreatic ascites is mostly of dense ascites (the anechoic image includes small moving echoic particles or the appearance is slightly hypoechoic, not completely anechoic).

The ultrasound differential diagnosis of CP is made with acute pancreatitis (where the pancreas is enlarged and hypoechoic), with Vater's ampulloma (enlargement of the Wirsung duct, usually accompanied by dilation of the MBD), retroperitoneal tumors situated in the upper abdomen, or pancreatic tumors - intraductal papillary mucinous tumors (IPMT). Differential diagnosis between chronic hypertrophic cephalic pancreatitis and pancreatic head tumor is difficult (the latter is mostly hypoechoic); CEUS, endoscopic ultrasound (EUS) or EUS elastography are used for distinction. Also, it is difficult to distinguish a pancreatic pseudocyst with septa from a pancreatic cystadenoma or cystadenocarcinoma or from a mucinous pancreatic tumor (Figs. 3.24, 3.25).

Computed tomography is useful for the evaluation of the pancreas and chronic pancreatitis. The presence of calcifications and their extension, the pancreatic outline, hypodense areas suspected of malignancy are best assessed by CT. Pseudocysts are easy to distinguish and evaluate.

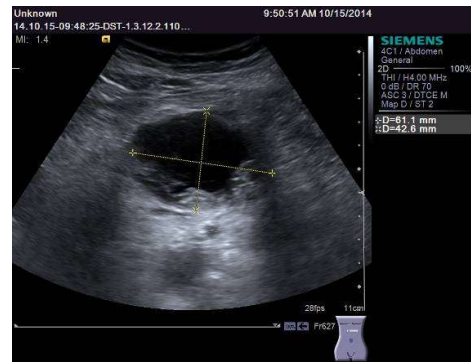
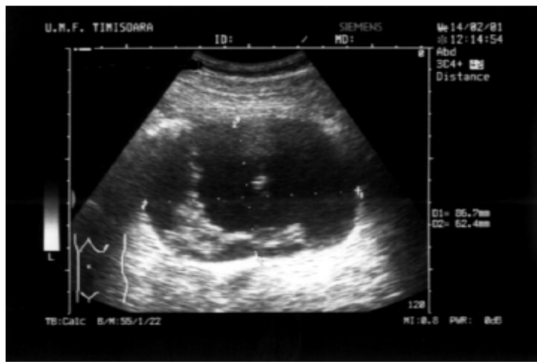

Fig. 3.24 Pancreatic cystadenocarcinoma

Fig3.25 Pancreatic cystadenocarcinoma

Endoscopic ultrasound (EUS) is a sensitive method for assessing pancreatic changes such as chronic pancreatitis or pancreatic tumors. Upper digestive endoscopy is used to approach the pancreas from a small distance (the body and tail of the pancreas will be seen from the stomach, while the head of the pancreas and the MBD will be reached from the duodenum). Thus, fine details such as local changes in the pancreatic echotexture or discrete enlargement of the Wirsung duct can be assessed, allowing an early imaging diagnosis of CP. At the same time, due to current facilities of endoscopic ultrasound, ultrasound guided biopsy will be possible for any lesion suspected of malignancy. Pancreatic cysts are also easy to evaluate revealing potential malignant lesions (endocystic protrusions).

ERCP (endoscopic retrograde cholangio-pancreatography) is mainly a therapeutic method and less a diagnostic method. It will reveal the finest changes in the Wirsung duct and its branches.

The ideal diagnostic method for CP, particularly in its early stages, is endoscopic ultrasound (it evaluates the parenchyma, the Wirsung duct and potential tumor areas including biopsy). In an advanced form of CP, transabdominal ultrasound will probably provide sufficient information.

Before concluding the chapter on imaging changes in CP, we must emphasize that an experienced ultrasonographer, using a high performance ultrasound machine with a 3.5 MHz convex transducer and a 5 MHz linear transducer, is able to diagnose most typical CP cases (with results similar to those of CT). For an early diagnosis of CP, endoscopic ultrasound is required.

In clinical practice, ultrasound remains the most frequently used method for the diagnosis and monitoring of chronic pancreatitis, accompanied by other imaging methods whenever they're necessary.

3. PANCREATIC CANCER

Definition: a neoplasm with the starting point in pancreatic tissue. Pancreatic cancers include pancreatic carcinoma, endocrine pancreatic tumors, cystic pancreatic tumors, ampullary tumor (ampulloma).

Pancreatic carcinoma is a relatively common tumor, which is slightly more frequent in men than in women. It usually develops after 60 years of age.

The clinical presentation depend on location. Obstructive jaundice is usually the first sign that leads to the diagnosis of a pancreatic head tumor. For tumors located in the pancreatic body and tail and sometimes in the pancreatic head, the most common clinical signs are rapid weight loss, epigastric or band-like pain, loss of appetite, carcinomatous ascites or metastatic liver. Migratory thrombophlebitis or acute obstructive pancreatitis episodes may occur.

The *ultrasound appearance* of pancreatic carcinoma is quite typical and consists of a hypoechoic mass in the pancreas, 1-5 cm in size (Figs. 3.26, 3.27, 3.28, 3.29). Pancreatic tumors are generally poorly delimited (Figs. 3.30, 3.31), sometimes inhomogeneous (large tumors in particular), and frequently invading adjacent vessels. Vessels invasion can be demonstrated using power Doppler or contrast enhanced ultrasound, and is useful for preoperative evaluation (Fig. 3.32). If pancreatic carcinoma develops on the background of chronic pancreatitis (a 5-30-fold increased risk), the diagnosis is difficult, particularly for the head of the pancreas. Increased levels of CA 19-9, CEUS, CT, endoscopic ultrasound or MRI should be used for differential diagnosis. If these have failed, ultrasound-guided fine needle (23-22 gauge) biopsy will be performed in the suspect area. Well delimited carcinomas are easier to diagnose by ultrasound (Fig. 3.33) than carcinomas with a diffuse outline or with infiltrative appearance.

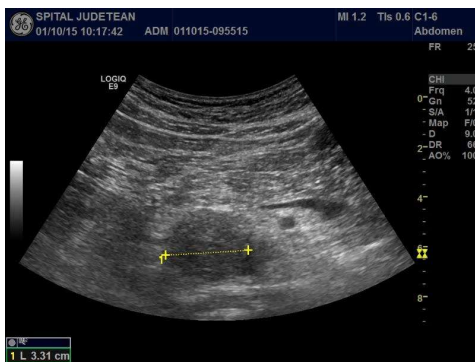

Fig. 3.26 Pancreatic carcinoma - hypoechoic , inhomogeneous mass

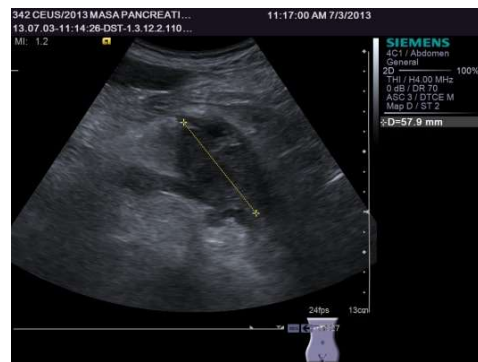

Fig. 3.27 Pancreatic carcinoma - hypoechoic , inhomogeneous mass

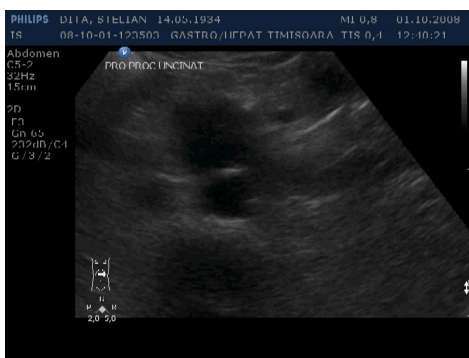


Fig. 3.28 Pancreatic carcinoma - hypoechoic mass

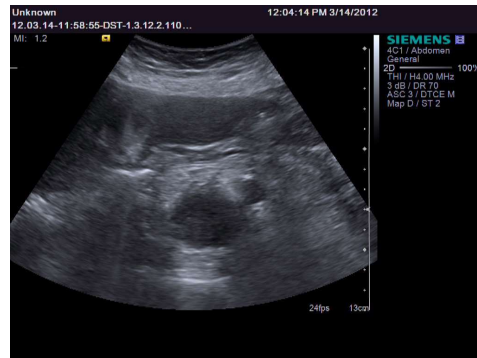


Fig. 3.29 Pancreatic carcinoma - hypoechoic mass

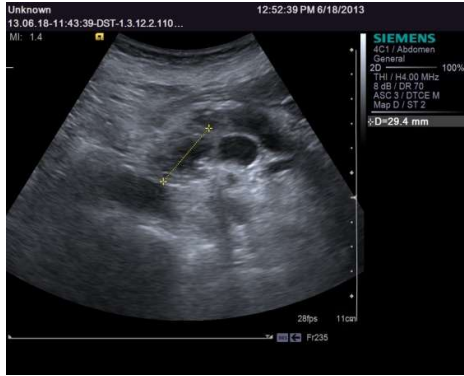


Fig. 3.30 Pancreatic carcinoma - poorly delineated hypoechoic mass

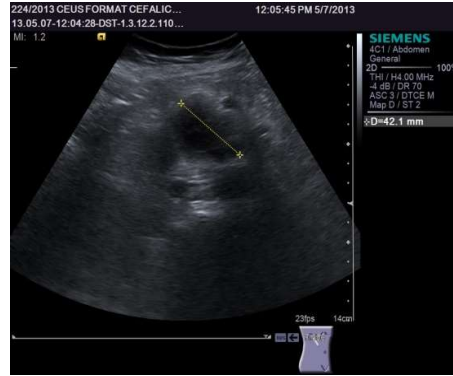

Fig. 3.31 Pancreatic carcinoma - poorly delineated hypoechoic mass

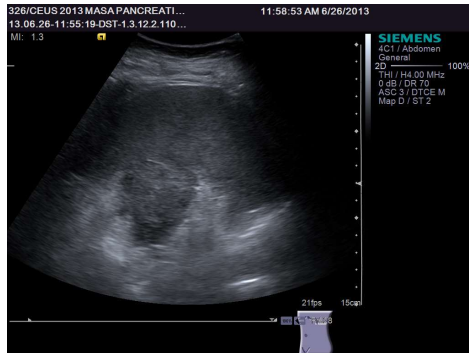


Fig. 3.32 Pancreatic tumor- poorly delineated mass, invasion of adjacent vessels

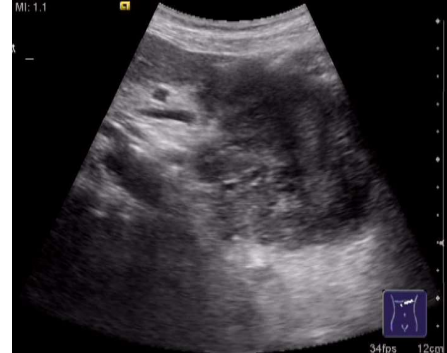

Fig. 3.33 Well delineated pancreatic carcinoma

A frequent clinical situation is that of an elderly patient with a jaundice syndrome. Ultrasound will easily establish the diagnosis of obstructive jaundice, sensitivity higher than 90%, by highlighting enlarged intrahepatic bile ducts and a MBD bigger than eight mm. Establishing the cause of obstructive jaundice by ultrasound is more difficult. In pancreatic tumors a hypoechoic pancreatic head mass that obstructs the MBD can be seen (Fig. 3.34). The ultrasound assessment of the MBD starts in the hilum, subsequently descending towards its retropancreatic section, where the obstruction can be detected as a more or less delimited hypoechoic mass.

Other methods to facilitate the diagnosis of pancreatic carcinoma are the use of harmonic ultrasound in order to improve the tumor delimitation, 3D ultrasound, the use of ultrasound contrast agents (for diagnosis and for the assessment of adjacent vascular invasion, especially in the spleno-portal axis or in the superior mesenteric vein).

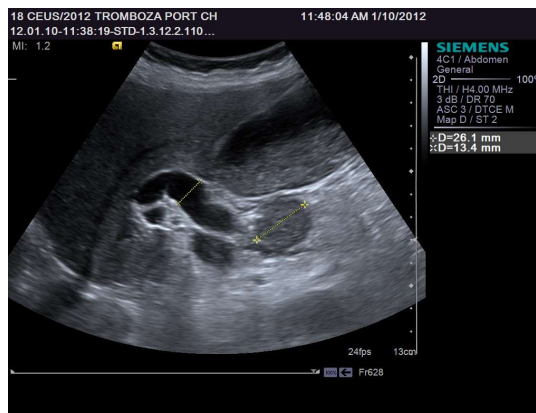


Fig. 3.34 Pancreatic carcinoma -
obstructive jaundice

Other imaging methods used for pancreatic cancer diagnostic are contrast enhanced spiral CT, MRI, endoscopic ultrasound, ERCP. Endoscopic ultrasound can see very small tumors and accurately assess vascular invasion (by endoscopic Doppler ultrasound). It also allows to collect a sample from the suspected lesion using endoscopic ultrasound guided biopsy. The preoperative assessment of pancreatic carcinoma is indispensable for assessing tumor extension and vascular invasion (it establishes the operability or non-operability of a case).

Endocrine pancreatic tumors are relatively rare. The main endocrine pancreatic tumors are gastrinoma, insulinoma, glucagonoma, somatostatinoma, VIPoma. One of their characteristics is the high hepatic metastasis rate, even when they are small.

The *clinical presentation* of endocrine pancreatic tumors depends on the type of hormone secreted. Thus, the following may occur: Zollinger-Ellison syndrome in gastrinoma (with multiple gastroduodenal ulcers and diarrhea), hypoglycemia developing into hypoglycemic coma in insulinoma, hyperglycemia in glucagonoma, or "pancreatic cholera" in VIPoma.

The **ultrasound appearance** of endocrine tumors is that of generally small, well delimited pancreatic masses (5-20 mm), hyper- or hypoechoic. An endocrine tumor is diagnosed quite rarely by ultrasound; it is most frequently diagnosed by CT and particularly, by endoscopic ultrasound, which is the method of choice. In the presence of clinical symptoms suggestive of an endocrine tumor, digestive hormones (gastrin, insulin, glucagon or somatostatin) should be evaluated, after which, if no pancreatic masses have been detected by ultrasound or CT, endoscopic ultrasound is performed. Due to the proximity to the examined organ, as well as to the sensitivity and specificity of the method, endoscopic ultrasound enables detection of tumors millimeters in sizes. Subsequently, ultrasound guided biopsy will certify diagnosis. In general, the ultrasound or echoendoscopic appearance will not allow differentiation of a pancreatic carcinoma from an endocrine tumor. Only biopsy (most frequently echoendoscopic) can make this differentiation. The use of CEUS can demonstrate a hypervascular tumor, unlike adenocarcinoma, which is usually hypovascular.

Another diagnostic techniques useful for endocrine tumors are MRI and MRCP.

Cystic pancreatic tumors are relatively rare. Most pancreatic tumors (carcinomas) are solid tumors. An anechoic pancreatic image detected by ultrasound is in most cases a pancreatic pseudocyst. If there is no history of acute pancreatitis and no imaging signs of chronic pancreatitis, a cystic pancreatic tumor should be suspected.

Cystic pancreatic tumors can be: microcystic adenoma or mucinous cystadenoma.

a) **(Benign) microcystic adenoma** is a benign entity and consists of multiple small cysts, less than 2 cm in diameter, and is most frequently found in the head of the pancreas. It may include calcifications best seen by CT. On ultrasound, the head of the pancreas appears as inhomogeneous, poorly delimited. Microcysts are usually so small that they cannot be individualized.

b) **Mucinous cystadenoma** (which can sometimes be malignant: **cystadenocarcinoma**) is a larger cystic structure, more than 2 cm in diameter, and may have a calcified peripheral ring. Usually, a single cavity is present; multilocular lesions are less common. In approximately 60% of the cases, mucinous cystadenoma or cystadenocarcinoma develops in the tail of the pancreas (Fig. 3.35). If surgery is performed in time, prognosis is relatively good.

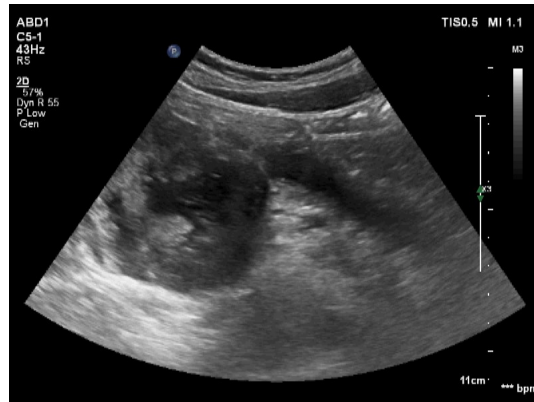


Fig. 3.35 Pancreatic mucinous cystadenoma

On ultrasound, mucinous cystadenoma will appear as a single or multilocular anechoic lesion, most frequently located in the tail of the pancreas, quite large in size (sometimes exceeding 3-5 cm). A hypoechoic rather than hyperechoic appearance or of inner excrescences suggests the diagnosis of carcinoma (Figs. 3.36, 3.37). Ultrasound guided percutaneous or echoendoscopic biopsy from the cyst is useful; it will evidence a free-running mucinous fluid.

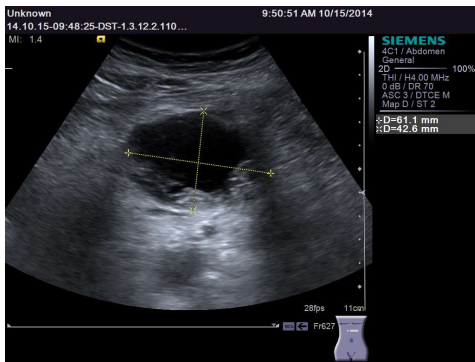


Fig. 3.36 Pancreatic cystadenocarcinoma

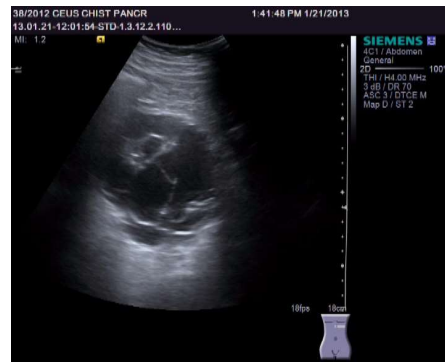


Fig. 3.37 Pancreatic cystadenocarcinoma

Other imaging techniques that help diagnosis in cystic pancreatic tumors are CT, MRI, ERCP and particularly, endoscopic ultrasound. The last will easily visualize microcysts in microcystic adenoma or will reveal excrescences inside the cyst in pancreatic cystadenocarcinoma.

Vater's ampulloma is a relatively rare tumor developing in Vater's papilla.

It clinically manifests through a progressive, painless jaundice syndrome, sometimes accompanied by anemia (exulceration of the papilla with occult digestive bleeding).

On ultrasound, the patient will show obstructive jaundice (dilatation of intrahepatic bile ducts, the Courvoisier-Terrier sign, and dilated MBD). By following the MBD from the hylum to the pancreas, no obstruction will be seen. In very good ultrasound examination conditions, a small hypoechoic juxtaduodenal mass obstructing the MBD may be seen (Fig. 3.38). Usually, a variable dilatation of the Wirsung's duct can also be seen in Vater's ampulloma.

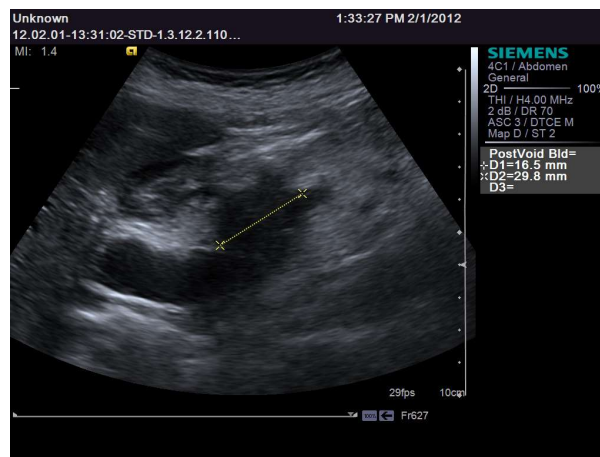


Fig. 3.38 Vater's ampulloma - dilated choledochus

If an ampulloma is suspected base on clinical and ultrasound signs, upper digestive endoscopy (duodenoscopy with a lateral view endoscope and subsequently, endoscopic ultrasound) should be

performed. Duodenoscopy with a lateral view endoscope allows to visualize the papilla and diagnostic biopsy. During ERCP, prostheses can be placed to drain the MBD.

In conclusion, although diagnosing pancreatic pathology is one of the most difficult tasks for the ultrasonographer, we must emphasize that the value of ultrasound in pancreatic diseases depends to a large extent on the experience, the competence and the ambition of the examiner. Continuous training, solid theoretical knowledge along with high performance equipment will lead to very good diagnostic results that will frequently compete with other much more sophisticated (and expensive) diagnostic methods.

4. JAUNDICE SYNDROME

Definition: clinically, it represents the yellow coloring of skin and mucosae, with a bilirubin value higher than 2.5-3 mg%. The clinical examination of such a patient requires adequate, preferably natural light. Initially, jaundice becomes visible in the conjunctiva, then on the skin (with the increase of bilirubin values).

Clinical examination: in a jaundice patient it is very important to determine the etiology. Medical history and objective examination sometimes reveal the diagnosis, but ultrasound or other diagnostic methods should establish the causes of the jaundice syndrome.

The patient's age is important. In general, jaundice in a teenager or in a young adult most frequently indicates acute viral hepatitis. Jaundice in an adult 30-40 years of age may have any etiology, such as the onset of acute viral hepatitis, decompensated liver cirrhosis, gallstones in the MBD are the most common ones. Jaundice in an elderly patient is most frequently caused by a pancreatic or bile duct cancer or by parenchymal decompensated liver cirrhosis.

The onset of the jaundice can be established by anamnesis and can be of assistance in clinical thinking. An onset associated with dyspeptic syndrome and sub fever may suggest acute viral hepatitis. A history of chronic hepatitis suggests parenchymal decompensation in chronic liver disease. A jaundice syndrome preceded by biliary colic may suggest MBD lithiasis. Progressive and painless jaundice syndrome accompanied by progressive weight loss in an elderly person may suggest a pancreatic head or bile duct tumor. Anamnesis should be conducted having in mind the possible types of jaundice and their onset.

Objective examination can provide valuable data for the etiology of jaundice. The presence of an increased abdominal volume suggests ascites and mixed decompensation in liver cirrhosis. The presence of spider naevi on the anterior or posterior thorax is also suggestive for cirrhosis. Chronic scratching lesions support the presence of chronic cholestasis (primary biliary cirrhosis, ampulloma, cholangiocarcinoma, etc.).

Palpation of the abdomen also helps in the diagnosis: the nature of hepatomegaly, the presence of splenomegaly or ascites. The liver will have a normal consistency in acute viral hepatitis; a significantly increased consistency in cirrhosis. Hepatomegaly will be hard on palpation in neoplastic jaundice (primitive or secondary). In case of a pancreatic head neoplasm or ampulloma, the fundus of the gallbladder will be distended (the Courvoisier-Terrier sign). The palpation of the spleen will usually reveal splenomegaly in liver cirrhosis.

The diagnostic approach in the presence of a jaundice syndrome will include the following stages:

- confirmation of jaundice;
- type of jaundice;
- cause of jaundice.

For the **confirmation of mild jaundice** bilirubin levels will be measured. At values higher than 2.5 mg%, jaundice becomes visible. The type of increased bilirubin, conjugated or unconjugated, is important, the increase of unconjugated bilirubin being relevant for Gilbert's syndrome or hemolysis. In current practice, an increase in both bilirubin types is found in both hepatocellular and obstructive jaundice (perhaps with a slight predominance of conjugated bilirubin in obstructive jaundice).

The increase of unconjugated bilirubin levels may occur in two situations:

- Gilbert's syndrome, a quite frequent condition (affecting up to 3% of the general population), consists of the intermittent increase of unconjugated bilirubin, through a transient bilirubin conjugation disorder. Intermittent subjaundice or jaundice episodes, related to physical exercise, prolonged fasting, may occur.

- hemolytic jaundice, regardless of its cause, will involve, along with increased unconjugated bilirubin levels, anemia (due to hemolysis), posthemolytic reticulocytosis, and in the case of chronic hemolysis, splenomegaly. After the diagnosis of hemolytic anemia is made, its etiology will be investigated.

The type of jaundice will be established by paraclinical investigations. Jaundice is usually classified as *hepatocellular* and *obstructive*. Hepatocellular jaundice is generated by hepatocyte disorder and is characterized by absence of dilated bile ducts. Obstructive jaundice is characterized by the presence of dilated bile ducts. Hepatocellular jaundice is differentiated from obstructive jaundice using hepatobiliary ultrasound as a first line imaging method.

The ultrasound appearance of hepatocellular jaundice depends on the underlying disease (acute viral hepatitis, liver cirrhosis, drug-induced cholestatic hepatitis, etc.). Regardless of the cause, the absence of dilatation of the intrahepatic bile ducts and MBD is characteristic. Undilated intrahepatic bile ducts cannot be visualized by ultrasound (so, when they are seen, it is a sign of dilatation). The common bile duct will be examined along its entire length, using an ultrasound section perpendicular to the right costal margin. Thus, the hepatic hilum will be visualized, where the portal vein is found posteriorly and the MBD anteriorly. We prefer the term MBD instead of common bile duct, because it is extremely difficult to establish by ultrasound the site where the common hepatic duct becomes the common bile duct (after the union with the cystic duct). The normal size of the portal vein is up to 12-13 mm, and of the MBD up to 6-7 mm.

The size of the MBD slightly increases (8 mm) after cholecystectomy or with age (studies have demonstrated that in the absence of MBD pathology, the diameter of the common bile duct may increase from 3-4 mm in young subjects to 7-8 mm in the elderly). The ultrasound examination of the MBD along its entire length is laborious and requires a long experience. In a good visualization, a real ultrasound "cholangiography" can be performed. The factors that can make the

exploration difficult are digestive air (air in the colon, stomach or duodenal bulb) and postoperative scars. In addition to a good ultrasound experience, a lot of patience, sufficient examination time and a compliant patient are required. The patient is most frequently examined in left lateral decubitus, but sometimes the position will be changed to procubitus or dorsal decubitus (to displace the digestive air).

If the intrahepatic bile ducts and MBD are not dilated, the diagnosis of hepatocellular jaundice will be made and its cause will be investigated. In hepatocellular jaundice, ultrasound can assist in establishing the etiology by visualizing a doubled gallbladder wall in acute hepatitis; a splenomegaly in chronic hepatitis (along with adenopathies in the hepatoduodenal ligament, particularly in chronic C virus hepatitis and in autoimmune or cholestatic hepatitis); and by revealing signs of liver cirrhosis (ascites, splenomegaly, thickening and doubling of the gallbladder wall, caudate lobe hypertrophy, hepatic heterogeneity, nodular hepatic surface and signs of portal hypertension).

The ultrasound appearance of obstructive jaundice is typical. It depends on the site of obstruction. Ultrasound will detect dilatation of intrahepatic bile ducts (Fig. 3.39), which become well visible. They accompany the portal branches, conferring a typical "double duct" appearance. Dilatation of intrahepatic bile ducts may occur in one or both lobes, depending on the site of obstruction. The severity of bile ducts dilatation (mild, moderate or severe) can be subjectively evaluated, depending on how large they are and on how easily they can be followed up to the periphery of the liver.

Dilated intrahepatic bile ducts provide a "spider" appearance (Fig. 3.40), located in the central part of the liver. In difficult cases, particularly the confusion with a dilated portal system, color Doppler or power Doppler can be used, which will demonstrate a color signal in portal branches and its absence in the dilated biliary system.

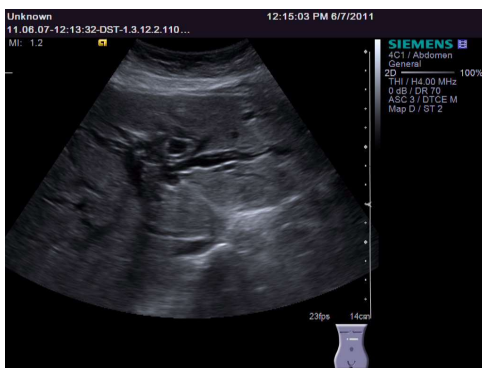


Fig. 3.39 Obstructive jaundice

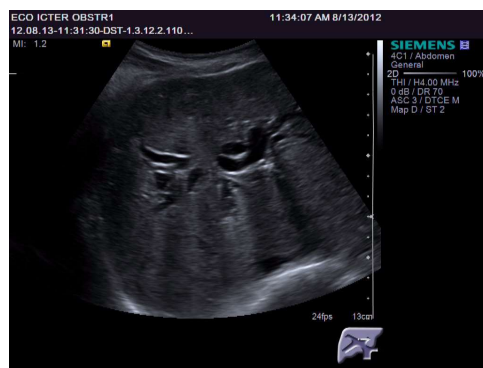

Fig. 3.40 Obstructive jaundice

The MBD will be examined by ultrasound in an oblique section perpendicular to the costal margin. The high portion continuing the intrahepatic bile ducts, then the hilar portion, and finally, the retropancreatic common bile duct segment will be assessed. Thus, it can be established whether the dilatation occurs along its entire length and a potential obstacle can be seen. Then, the

gallbladder will be examined, which may appear significantly distended, with biliary sludge, in a pancreatic head carcinoma or in an ampulloma (the ultrasound Courvoisier-Terrier sign), or on the contrary, it may be thin, sometimes almost without bile, in tumors located at the convergence of the hepatic ducts into the common hepatic duct (Klatskin tumor). Sometimes, stones are detected in the gallbladder, which may be the cause of obstructive jaundice if they migrated in the common bile duct.

Abdominal ultrasound is a sensitive diagnostic method in obstructive jaundice, with a 90-95% sensitivity for an experienced examiner. The method is sensitive for determining the site of obstruction (high or low). The most difficult problems occur when attempting to establish the etiology of obstructive jaundice.

The cause of obstructive jaundice is much more difficult to establish by ultrasound.

The main causes of obstructive jaundice are:

– *central cholangiocarcinoma or Klatskin tumor*, which develops in the common hepatic duct, in the right or the left hepatic duct, or at their confluence. It causes the dilatation of intrahepatic bile ducts, but with a small MBD and gallbladder. The tumor is rarely seen by ultrasound due to its small size. Diagnosis is confirmed by MRCP or ERCP.

– *intrahepatic lithiasis* is relatively rare in Europe; more frequent in Asia (hemolysis), it generates the upstream dilatation of the bile ducts. On ultrasound, it appears as a hyperechoic image with a "posterior shadow", situated along the intrahepatic bile ducts, with their upstream dilatation.

– *primitive or secondary intrahepatic tumors* (hepatocellular carcinoma, peripheral cholangiocarcinoma, liver metastasis) may cause obstructions of the intrahepatic bile ducts with their upstream dilatation. Ultrasound will show a tumor mass of variable echogenicity (hypoechoic, hyperechoic or rosette-like), and the upstream dilatation of the bile ducts.

– *Mirizzi syndrome* is an obstructive jaundice generated by the compression of the MBD by a large gallstone impacted in the infundibulum. It is an extremely rare cause of obstructive jaundice; ultrasound diagnosis is based on the presence of dilated intrahepatic bile ducts, a large common hepatic duct, and the visualization of a large infundibular gallstone. The size of the MBD is normal.

– *extrinsic compression of the MBD*, most frequently through hilar enlarged lymph nodes, most frequently malignant (lymphoma or lymph node metastases from an adjacent cancer: stomach, pancreas, colon, etc.). Ultrasound shows dilated intrahepatic bile ducts, dilated MBD up to the obstruction level. Hilar adenopathies in the form of oval hypoechoic masses of variable sizes (2-5 cm) are seen. Sometimes, the primary (pancreatic, gastric or colonic) tumor can be revealed by ultrasound.

– *common bile duct stones* are a common cause of obstructive jaundice. They may be residual (having migrated from the gallbladder, left after surgery) or may form in the MBD after cholecystectomy. They manifest through obstructive jaundice or chronic cholestasis syndrome. They can be completely asymptomatic for a long period. Obstructive jaundice through MBD lithiasis is usually preceded by a biliary colic. In some cases, a *cholestasis syndrome* (increased gamma-glutamyl transpeptidase, alkaline phosphatase levels, but also increased GOT and GPT through secondary hepatic disease) is detected in a cholecystectomized patient. Cholestasis may be

icteric (increased bilirubin) or anicteric (normal bilirubin). Ultrasound will show dilated intrahepatic bile ducts and a dilated MBD upstream of the calculus. Stones will appear as hyperechoic images situated in the common bile duct lumen, which most frequently generate a "posterior shadow" (Figs. 3.41, 3.42, 3.43). The stone(s) cannot always be visualized by ultrasound, due to the presence of digestive air that prevents an adequate examination of the MBD or because the stone is positioned in the papilla, which makes visualization extremely difficult due to the contact with the aerated duodenum.

Sometimes, ultrasound shows the presence of many conglomerated stones in the distal MBD, which are difficult to individualize (Fig. 3.44).

In the presence of aerobilia, after a biliodigestive derivation, the evaluation of the common bile duct for gallstones becomes almost impossible, because both the air and the calculi are hyperechoic (MRCP is the method of choice for diagnosis). In the case of uncertain ultrasound diagnosis or in a suspicion of MBD lithiasis, diagnostic endoscopic ultrasound will be performed. If positive, ERCP will be initiated. This will confirm the diagnosis and will proceed with the therapeutic extraction of the stone, after sphincterotomy, using a balloon catheter or a Dormia basket.

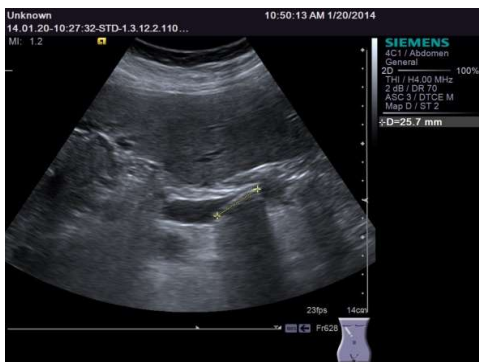

Fig. 3.41 Choledocholithiasis

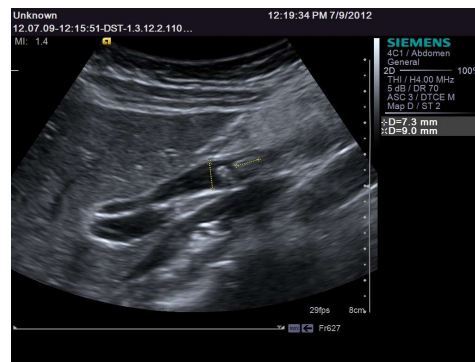


Fig. 3.42 Choledocholithiasis

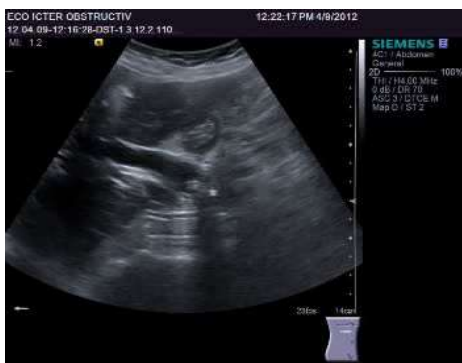

Fig. 3.43 Choledocholithiasis

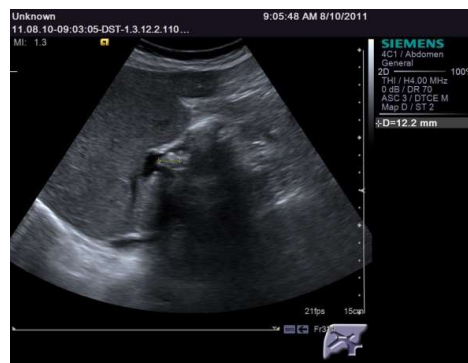

Fig. 3.44 Choledocholithiasis

In case of chronic cholestasis, even if the common bile duct is normal, it is recommended to perform endoscopic ultrasound, because there may be calculi that do not generate obstructive jaundice, but only chronic cholestasis.

– *malignant common bile duct tumor (cholangiocarcinoma) or benign common bile duct tumor (papilloma)* can generate obstructive jaundice. Ultrasound will show dilatation of the intrahepatic bile ducts, a distended gallbladder (subcystic obstruction) and a dilated MBD up to the obstruction level. The tumor will appear as a hypoechoic mass in the common bile duct lumen, without a posterior shadow, of variable size (usually 2-3/1-1.5 cm). Ultrasound differentiation will be made with common bile duct stones without a posterior shadow or with biliary sludge formed upstream of an obstruction. Confirmation will be obtained using endoscopic ultrasound or ERCP.

– *ascarids in the common bile duct* are an extremely rare cause of obstructive jaundice. In some regions, such as India, this is a common cause of biliary obstruction. An echogenic linear structure can be visualized by ultrasound in the dilated common bile duct.

– *pancreatic head cancer* is a frequent cause of obstructive jaundice. It is a progressive painless jaundice that occurs in elderly persons, accompanied by important weight loss. On ultrasound, the intrahepatic bile ducts are dilated, the common bile duct is significantly enlarged (15-25 mm), and the ultrasound Courvoisier-Terrier sign is present (Figs. 3.45, 3.46). In the head of the pancreas, a hypoechoic mass will be seen (Figs. 3.47, 3.48), of variable size (mostly 2-5 cm), compressing the MBD. (Fig. 3.49). Diagnosis will be confirmed by endoscopic ultrasound, CA 19-9 (tumor marker), ERCP or CT. Ultrasound guided fine needle aspiration biopsy from the tumor will only be performed in non-operable cases (because of the risk of dissemination along the needle's tract).

– *Vater's ampulloma* is a tumor of Vater's papilla. It generates progressive painless obstructive jaundice that frequently shows few symptoms. It may be accompanied by moderate anemia (the tumor can ulcerate into the duodenum, with occult bleeding). Ultrasound shows dilated intrahepatic bile ducts, an enlarged common bile duct along its entire length, a distended gallbladder. As the ampullary tumor is small (Fig. 3.50) and growing towards the duodenum, it cannot be evidenced by transabdominal ultrasound. A mild or moderate dilatation of the duct of Wirsung (through a Wirsung obstruction) is also common. The diagnosis of ampulloma is confirmed by duodenoscopy with a lateral view endoscope, by ERCP and endoscopic ultrasound. Ampulloma can be benign or malignant and its differentiation is made by histological biopsy. Therapy includes endoscopic or surgical ampullectomy or endoscopic prosthesis placement.

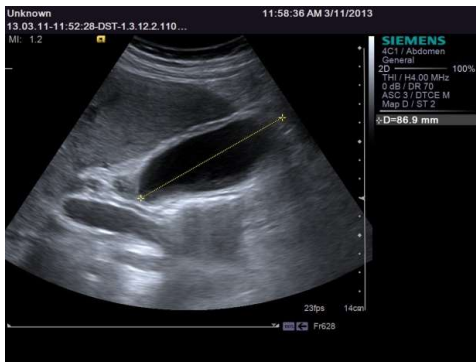

Fig. 3.45 Courvoisier-Terrier sign

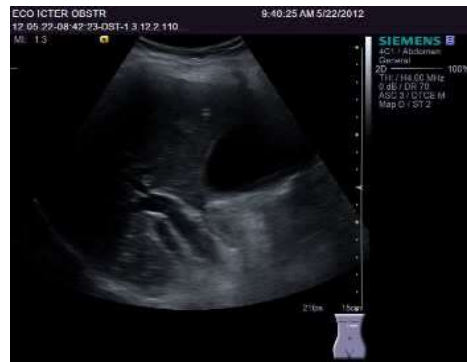

Fig. 3.46 Courvoisier-Terrier sign

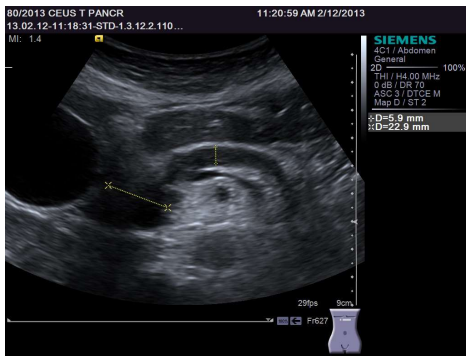


Fig. 3.47 Pancreatic head neoplasm

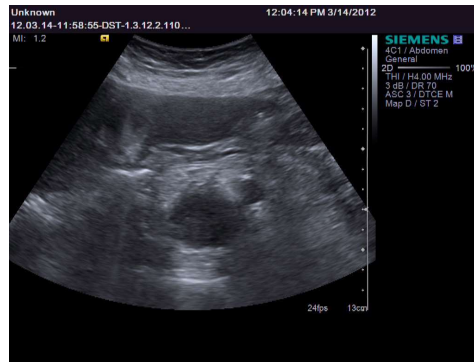


Fig. 3.48 Pancreatic head neoplasm

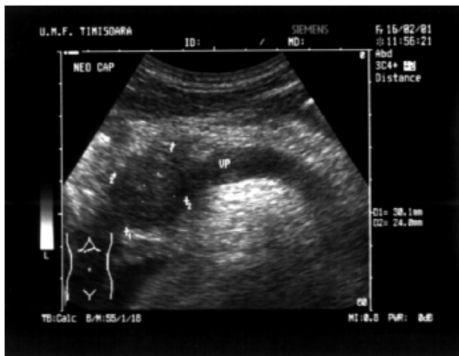

Fig. 3.49 Pancreatic head neoplasm

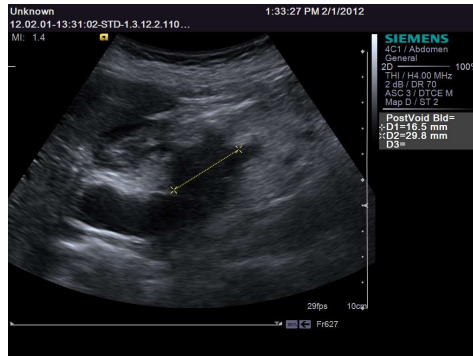


Fig. 3.50 Vater's ampulloma
obstructive jaundice

– *chronic pancreatitis* can generate obstructive jaundice in pancreatic head hypertrophy or in pancreatic head pseudocyst. Ultrasound will show signs of chronic pancreatitis (pancreatic calcifications, dilatation of the Wirsung's duct, Wirsung stones) and a large pancreatic head. The ultrasound examination of the common bile duct will reveal its compression by a large, frequently inhomogeneous cephalic pancreas, with calcifications, or by a pancreatic head pseudocyst (anechoic

hesion with hyperechoic walls). The diagnosis of chronic pancreatitis is confirmed by endoscopic ultrasound or CT.

For the evaluation of obstructive jaundice that has not been clarified by ultrasound, MR cholangio-pancreatography (MRCP) can be used. This visualizes the intra- and extrahepatic bile ducts and at the same time, it evaluates the pancreas and the liver.

In this chapter, we presented the clinical and imaging approach to a jaundice syndrome. The type of jaundice, hepatocellular or obstructive, can be established by ultrasound. In hepatocellular jaundice, ultrasound can provide some diagnostic but not very relevant elements. In obstructive jaundice, the diagnosis of obstruction site can be made. The etiology of obstructive jaundice is more difficult to establish.

In a *retrospective study*, performed in the Ultrasound Department of the Timișoara County Hospital several years ago, by analyzing 77 obstructive jaundice cases, the etiology of obstructive jaundice could be clearly established by transabdominal ultrasound in 57.1% (44/77) of the cases. Subsequently, the same *study* was conducted *prospectively* in a group of 46 obstructive jaundice cases and etiologic diagnosis by ultrasound was made in 73.9% of the cases (34/46). These data are in accordance with most published data that indicate a 60-80% sensitivity of ultrasound in the etiologic diagnosis of obstructive jaundice.

Regarding the frequency of different causes of obstructive jaundice, in the above mentioned study we found that 44.1% of the cases had pancreatic head cancer, 35.2% MBD stones, 4.3% Klatskin tumor, 6.5% chronic pancreatitis + pancreatic head pseudocyst, 2.1% compressive hydatid cyst, 2.1% invasive gastric cancer, etc.

In conclusion, we must mention that the experience, the theoretical and practical skills of the examiner, the type of ultrasound machine used, as well as the commitment to the task of clarifying the etiology of jaundice are extremely important.

CHAPTER 4

THE SPLEEN

Ultrasound is the easiest way to detect spleen pathology. Situated in the splenic loge, the spleen is an organ with a parenchymal structure, with similar echogenicity to that of the liver. The spleen is evaluated by ultrasound either through left intercostal sections or through sections below the left costal margin. The normal spleen is crescent shaped and is less than 12/6 cm in size. For inexperienced ultrasonographers it is relatively difficult to include the entire spleen in a single section, particularly in splenomegaly cases. The beginner tends to include only a portion of the spleen in the ultrasound section, which makes its accurate measurement impossible.

The examination of the spleen will be conducted in such a manner as to include both splenic poles in the ultrasound plane, allowing accurate measurement. This way, the presence of splenomegaly can be assessed. Both the long axis (the most important) and the short axis should be measured. Sometimes, a more globulous spleen (more than 6 cm thick) can be detected. Under pathological conditions, the spleen echogenicity may be modified, but it is almost impossible to speculate regarding the hematological or hepatic cause based only on the spleen structural and echogenicity changes.

From a clinical point of view, the spleen assessment is valuable in hematologic or liver diseases, in some infectious diseases, after abdominal trauma or surgery, as well as in prolonged fever.

1. Splenomegaly

Definition: an enlargement of the spleen exceeding 12 cm in its long axis. Some authors consider a normal spleen size up to 11 cm, others, up to 13 or even 14 cm, but most ultrasonographers consider the value of 12 cm as being the upper limit of normal. Due to the overlapping of the Gaussian curves, a 12 cm spleen will be rarely normal. In these cases, liver or hematologic pathology should be excluded before a 12 cm spleen can be considered normal.

In current clinical practice, splenomegaly is classified as *hepatic* or *hematologic*. Splenomegaly in infectious or parasitic diseases is exceptional in Romania.

The clinical presentation is most frequently absent. In most cases, splenomegaly is discovered incidentally. In other cases there are signs of the underlying hepatic or hematologic disease. In cirrhosis, the following may be present along with splenomegaly: jaundice, ascites, collateral abdominal circulation, bleeding gums or epistaxis. In a hematologic disease, anemia, asthenia, fever, etc. may occur. Moderate splenomegaly but mostly, important enlargement of the spleen may cause pain, discomfort or a sensation of weight in the left hypochondrium.

The ultrasound appearance is of an increase in the spleen's volume. There may be mild splenomegaly (up to 13-14 cm), moderate splenomegaly (15-16 cm), and important splenomegaly (more than 16 cm). Generally, the enlargement affects all axes of the spleen (Figs. 4.1, 4.2).

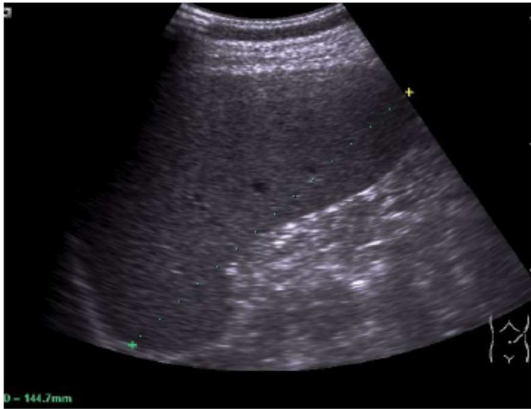

Fig. 4.1 Splenomegaly (14.4 cm)

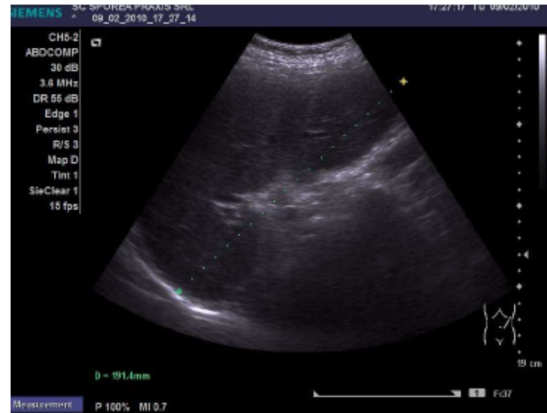


Fig. 4.2 Splenomegaly (19 cm)

Regarding changes in echogenicity, we consider that no etiological speculation can be made based on this characteristic. Ultrasound will evaluate possible signs of portal hypertension (PHT), e.g. splenic varices. The liver will be examined for signs of liver cirrhosis (hepatic heterogeneity, nodular liver surface, signs of PHT, double-layered thickened gallbladder wall and ascites). If any of these signs of cirrhosis are found, it is a clear sign that splenomegaly is caused by a chronic liver disease. Otherwise, possible abdominal enlarged lymph nodes will be searched for (suggestive for lymphoma), by exploring the celiac and aorto-caval lymph nodes (in sagittal and transverse sections). In lymphoma, their size will be between 2-5 cm.

In chronic hepatitis (particularly hepatitis C, but sometimes also hepatitis B or autoimmune hepatitis), one or more oval lymph nodes 15-25/10 mm in size can be found in the hepatoduodenal ligament, of inflammatory origin.

The power Doppler ultrasound examination of the spleno-portal axis is useful for highlighting a possible thrombosis with secondary splenomegaly.

The diagnostic assessment of splenomegaly without signs of cirrhosis on ultrasound will start with the exclusion of a liver disease (much more frequent compared to hematologic diseases associated with splenomegaly). The liver should be carefully palpated to find hepatomegaly, followed by assessment of liver consistency. First-line biological tests include: complete blood count (CBC), thrombocyte count (for possible hematologic hypersplenism), GOT, GPT, HBs Ag and anti HCV antibodies, so that an active or inactive chronic hepatic disease is discovered. More recently, the use of FibroScan (transient elastography) or other types of elastography allows detection of elasticity changes corresponding to chronic liver disease (chronic hepatitis and especially cirrhosis). The advantage of real-time elastography (VTQ-AKFI method, Siemens) is that this ultrasound machine can perform both standard ultrasound and liver elasticity assessment. If hepatomegaly is not detected by clinical exam and both biological tests and elastographic evaluation (if available) are normal, splenomegaly will be referred to a hematologist for further investigation.

Usually, chronic hepatitis is associated with mild splenomegaly, liver cirrhosis is associated with mild or moderate splenomegaly, while hematologic diseases are associated with variable spleen sizes, sometimes with giant splenomegaly (in chronic myeloid leukemia or myeloid metaplasia with myelosclerosis). Ultrasound is useful and sufficient for monitoring splenomegaly, the exception being giant splenomegaly, where the visualization of whole organ is difficult. In these cases, if available, the Siemens SieScape system can be used - panoramic imaging.

2. Accessory spleen

Definition: splenic tissue situated outside the splenic capsule. Usually, there is a single accessory spleen. Rare cases of multiple accessory spleens are found. They are completely asymptomatic, without any clinical significance. They occur in 5-10% of the patients examined by ultrasound.

The ultrasound appearance of an accessory spleen is that of a well circumscribed round-oval structure with an identical echogenicity to that of the spleen, situated in the hylum or one of the splenic poles. The size of an accessory spleen varies between 10-25 mm. Power Doppler assessment may reveal a vascular connection with the splenic hilum.

The ultrasound recognition of accessory spleens is easy, the landmark being a similar echogenicity of the structure and the spleen (Fig. 4.3). Accessory spleens are more frequently located next to the distal splenic pole.

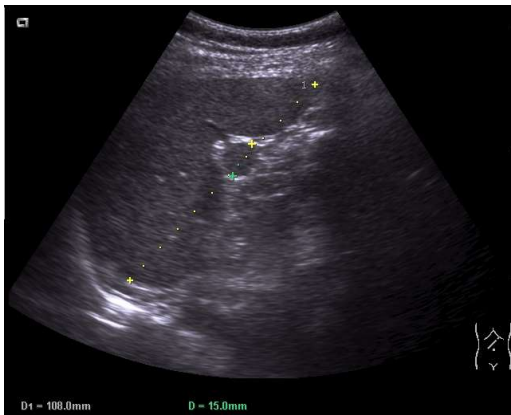


Fig. 4.3 Accessory spleen

The ultrasound differential diagnosis is made with: adenopathies in the splenic hilum (in lymphoma) - they are hypoechoic compared to the spleen; pancreatic tail tumor - hypoechoic area in the pancreas tail; aneurysmal thrombosis of the splenic vein. The use of CEUS may add to the differential diagnosis because the accessory spleens' enhancement pattern following contrast is similar to that of the adjacent spleen.

3. Spleen trauma

Over the past years, as a result of the increasing number of road traffic accidents, the number of splenic traumas has also increased. Thus, spleen ruptures or intrasplenic or subcapsular hematomas have become more frequent.

The physician responsible of the patient's examination has a high responsibility because undiagnosed splenic ruptures or subcapsular hematomas may lead to a rupture in two phases that can endanger the patient's life. Moreover we are talking about a critical patient, who sometimes cannot cooperate during the ultrasound examination (deep inspiration or stopping breathing).

The ultrasound examination of a patient following road traffic trauma, a fall or an explosion starts by assessing the peritoneal cavity in order to assess if fluid is present. It may be detected in the Douglas space, with a hypoechoic rather than anechoic appearance. In case of uncertainty, exploratory paracentesis should be performed.

The evaluation of the splenic lobe may reveal a completely normal spleen or pathological changes. Each region of the spleen will be visualized and the integrity of the capsule will be assessed. Failing to scan either poles of the spleen may lead to missing a pathological change.

Spleen rupture involves, in addition to hemoperitoneum, a discontinuity in the splenic capsule, with the presence of a poorly circumscribed hypoechoic perisplenic hematoma (Figs. 4.4, 4.5).

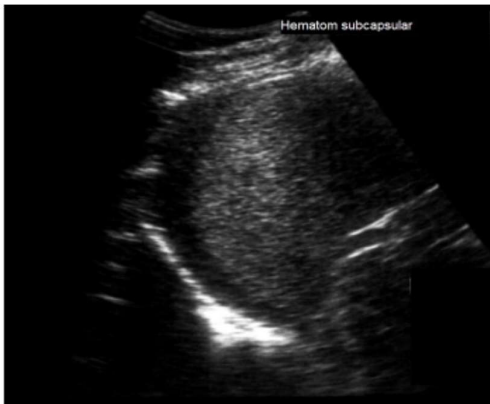
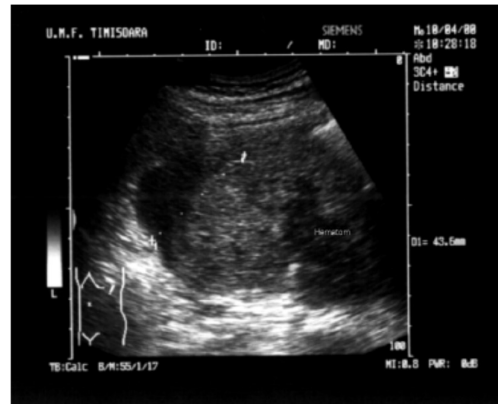
Fig. 4.4 Perisplenic hematoma



Figs. 4.5 Perisplenic and intrasplenic hematoma

An intrasplenic hematoma will appear as a poorly circumscribed hypoechoic area, located inside the parenchyma (Figs. 4.6, 4.7, 4.8). A subcapsular hematoma varies in size and appears as a hypoechoic crescent that surrounds the spleen. There is a risk of a two phase rupture of the subcapsular hematoma, with severe secondary hemorrhage.

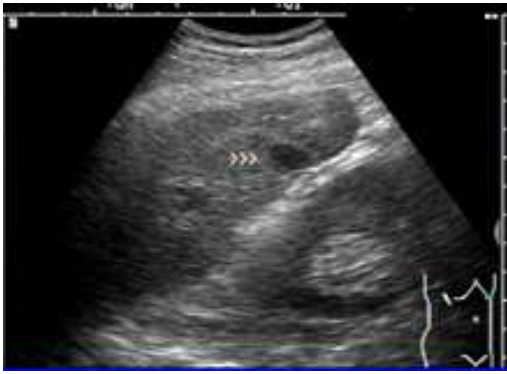

Fig. 4.6 Intrasplenic hematoma

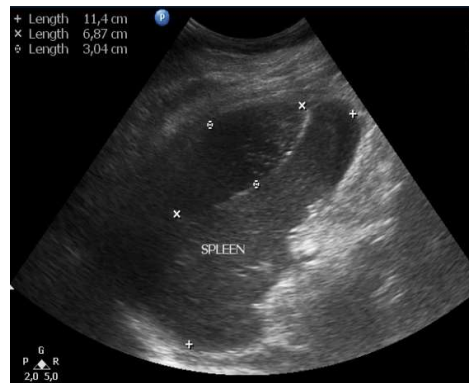

Fig. 4.7 Subcapsular splenic hematoma

Detection of a splenic lesion by ultrasound is a great responsibility. The therapeutic decision depends on the lesion's extension and on the clinical state of the patient. The use of power Doppler for the assessment of splenic vascularization and of vessels proximal to the hematoma can be helpful for the therapeutic approach. The examination will include contrast enhanced ultrasound (CEUS) with SonoVue, which is particularly useful, demonstrating the absence of the contrast agent in the hematoma area. CEUS will correctly delineate the hematoma (no contrast enhancement) and will subsequently allow monitoring if surgery is not performed. CEUS is extremely useful in splenic trauma in children since it avoids CT radiation.

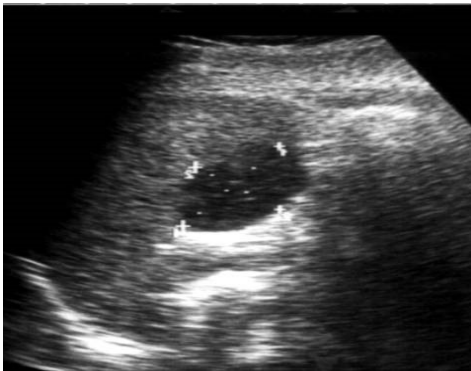

Fig. 4.8 Splenic hematoma

In other situations, particularly in polytrauma, emergency contrast enhanced spiral CT is helpful for the global evaluation of the trauma patient, as well as for spleen evaluation.

The difficulties encountered during ultrasound evaluation in splenic trauma are related to the fact that the patient is frequently in a critical state, in pain, having multiple fractures, and cannot cooperate. The result of the ultrasound exam is extremely important treatment decision especially to refer or not the patient for surgery, thus all unclear cases (if not all severe trauma cases) should be assessed by CT.

4. Splenic tumors

In clinical practice, splenic tumors are relatively rare. They can be sarcomas or lymphomas. The latter are more frequent.

The ultrasound appearance of lymphomas is of hypoechoic, frequently inhomogeneous and poorly circumscribed areas inside the spleen. This ultrasound aspect can be found when the disease is diagnosed or it can be detected in a patient with known Hodgkin or non-Hodgkin lymphoma. Detection of splenic lesions will be followed by the assessment of potential abdominal adenopathies. Other splenic tumors may include splenic sarcomas and metastases (Figs. 4.9, 4.10, 4.11).

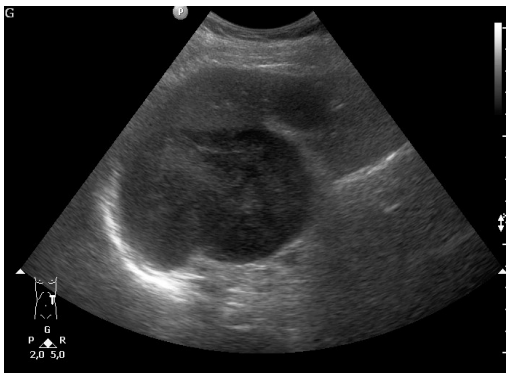


Fig. 4.9 Splenic tumor (sarcoma)

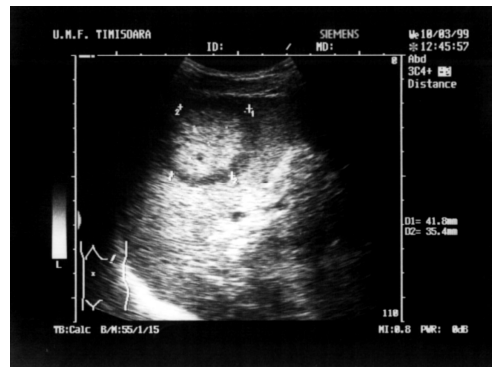


Fig. 4.10 Splenic metastasis

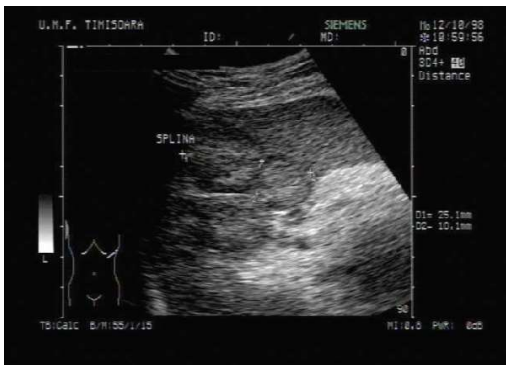

Fig. 4.11 Splenic metastases

Ultrasound differential diagnosis should be made with splenic abscess (Fig. 4.12), splenic hematoma (Figs. 4.6, 4.8) or splenic infarction.

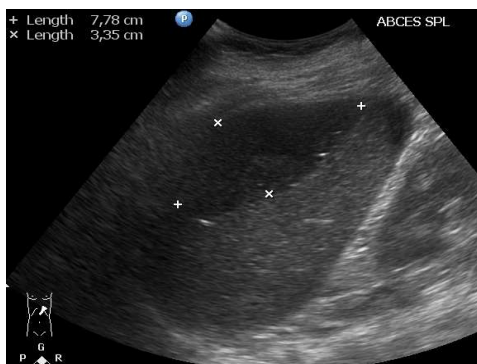

Fig. 4.12 Splenic abscess

In the clinical practice, detection of a splenic mass raises serious differential diagnosis problems. This is frequently a malignant lesion, and other diagnostic methods (CT, MRI) provide no additional information. Contrast enhanced ultrasound (CEUS) can be useful. If imaging fails to clarify a splenic mass, ultrasound guided biopsy may be an option. Ultrasound guided fine needle biopsy is rejected by most of the ultrasonographers due to the risk of bleeding. Over the last years, Italian authors have changed this myth, demonstrating that hemorrhagic accidents after fine needle splenic biopsy are relatively rare (approximately 1%).

5. Splenic abscess

Definition: a pus collection in the spleen. It can be secondary to surgery or splenic trauma (superinfected hematoma), or it may develop on the background of bacterial endocarditis.

The clinical presentation is frequently septic, with fever, chills, and altered general state. A history of surgery or trauma can be present.

The ultrasound appearance is that of a poorly delimited, hypoechoic splenic mass. Splenic abscesses can be inhomogeneous or, more rarely, hyperechoic. Clinical information is very important for diagnosis. Further evaluation by CEUS or CT is extremely useful.

The ultrasound differential diagnosis is made with splenic tumors, splenic hemangioma, splenic hematoma (Fig. 4.13), splenic infarction, less frequently with splenic cysts (Fig. 4.14).

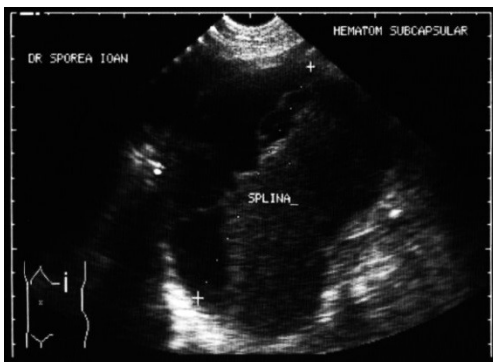


Fig. 4.13 Splenic hematoma

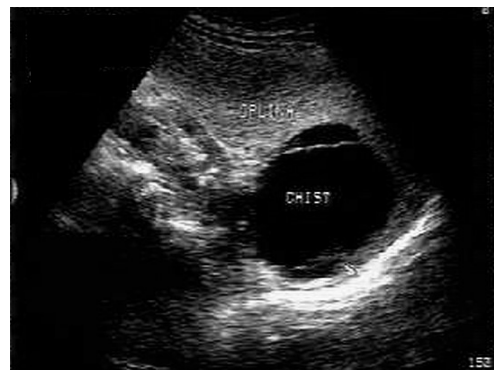

Fig. 4.14 Splenic cyst

Splenic cysts can be rarely hydatid (*Echinococcus granulosus*) or non-parasitic.

Splenic hydatid cysts have a thick wall and daughter vesicles (inner septa) can be frequently seen on ultrasound. The serological test for echinococcosis is usually positive.

Non-parasitic cysts have a fine wall, anechoic content (Figs. 4.14, 4.15), rarely fine inner septa (Fig. 4.14, 4.16). Posterior enhancement behind the cysts is present. They are not symptomatic and can rarely be complicated by intracystic hemorrhage.

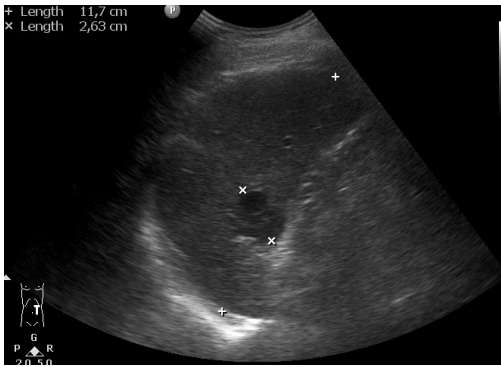


Fig. 4.15 Non-parasitic splenic cyst

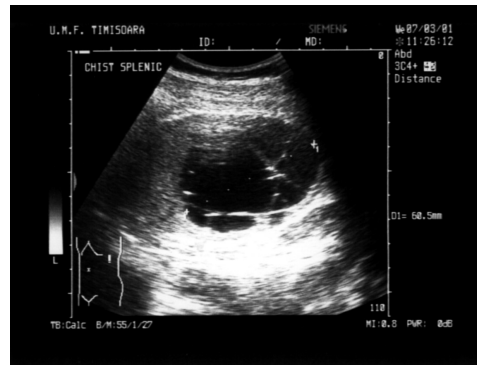

Fig. 4.16 Splenic cyst with fine inner septa

Over the past years, CEUS has been widely used for the differential diagnosis of splenic masses. Contrast enhancement inside the tumor is different from the enhancement of the normal splenic parenchyma, and cysts, even superinfected or hemorrhagic, do not enhance following contrast. Splenic hemangiomas have a typical pattern on CEUS, and the CEUS appearance of splenic infarction is also typical (a triangular area without contrast enhancement).

As a conclusion to the chapter on the ultrasound pathology of the spleen, we will emphasize that splenomegaly is most frequently associated with hepatic or hematologic disorders (ultrasound may provide diagnostic elements for one group or another, and if it fails to do so, the severity of hepatic fibrosis will be assessed using elastographic techniques: FibroScan or real-time elastography).

Chapter 5

THE DIGESTIVE TRACT

The medical evaluation of the digestive tract by ultrasound is relatively recent. For a long time considered to be an impediment in the investigation of abdominal organs, because of air, digestive ultrasound has recently been used more and more often. The results of the ultrasound examination allow establishing difficult diagnoses.

The ultrasound evaluation of the digestive tract represents a “refinement”, as it is addressed to experienced ultrasonographers, usually specialists in this imaging domain. We should bear in mind that inexperienced physicians may not be able to visualize the alterations of the digestive tract described in this chapter. After gaining a solid experience in ultrasound exploration (generally over at least 1000 abdominal examinations), the passionate specialist may start examining the organs of the digestive tract, normal or pathological, in order to acquire the necessary skills. The confrontation of ultrasound images with endoscopy or other imaging methods (or even surgery) will eventually lead to an easier identification of digestive tract diseases.

The ultrasonography of the digestive tract requires not only a trained specialist, but also quality equipment. Besides the classical convex multifrequency transducer (3.5 MHz usually), it is also useful to perform the examination with a linear multifrequency transducer (5-10 MHz) (depending on the digestive segment examined). The time dedicated to the examination of the digestive tract should be long enough to evaluate its different segments and also to notice possible complications of organ disease.

Obtaining *clinical information* prior to the examination is extremely useful, influencing the accuracy of imaging. The presence of low dysphagia will prompt a focus on the gastroesophageal junction (GEJ). Epigastric pain will prompt to look for US alterations in the stomach. In the presence of chronic diarrhea, the examination will be focused on the left and recto-sigmoid colon. After seeing US changes in a digestive segment, we shall try to obtain as many ultrasound data as possible, to be described and recorded. A follow up by endoscopy is recommended in order to explain the ultrasound changes. If the patient undergoes surgery, the surgical sample should be examined, in order to study the alterations of the digestive wall layers, thus explaining the ultrasound changes and possible false images.

Another situation is when the clinician knows the endoscopic diagnosis and US assessment is recommended to search for US changes corresponding to the endoscopic ones or for their consequences in other organs. Thus, if endoscopy revealed a gastric tumor, the ultrasound examination should assess its extent (liver metastases, local lymph nodes), but also the alterations of the gastric wall. The patient will be examined both in fasting conditions and after drinking still water. The size of the affected gastric wall should be assessed, as well as its thickness, the extension of the tumor, and possible neighboring lymph nodes. All recorded data will be subsequently

compared to the surgical piece, which will facilitate understanding the results and add to the operator's experience in digestive tract exploration.

We will describe in the next pages the pathologic alterations in the main digestive diseases, the usefulness of transabdominal ultrasound and other complementary assessment methods.

1. THE GASTROESOPHAGEAL JUNCTION (GEJ)

Faced with a patient complaining of low dysphagia for solid food or for both solids and liquids, the assessment can begin with a transabdominal US. This is more readily at hand than upper digestive endoscopy and may be performed immediately, if we have an ultrasound machine.

In most cases, ultrasound will normally visualize the gastroesophageal junction (fig. 5.1). The transducer is placed in the epigastrium, in sagittal section, while the left hepatic lobe is used to obtain a good ultrasound window (a small left lobe might render the examination of the gastroesophageal junction impossible). The walls of the lower thoracic esophagus, its infradiaphragmatic and abdominal segments can be seen, with hypoechoic aspect. Inside the esophagus walls a hyperechoic structure is seen - the air, or rather the airy saliva swallowed. Normal esophageal walls are thin (2-3 mm) (fig. 5.2). For the examination of the gastroesophageal junction the transducer will be angled so that it superimposes the esophageal trajectory when crossing the diaphragm. When the GEJ is localized, its alterations should not be too difficult to see for an experienced ultrasonographer. We recommend that the GEJ should be visualized on a daily basis, in order to gain the ability to tackle a patient with dysphagia.

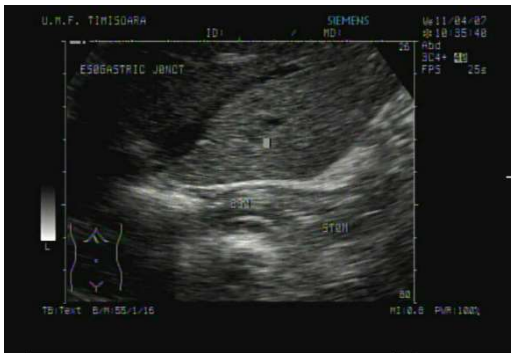

Fig. 5.1 Normal gastroesophageal junction

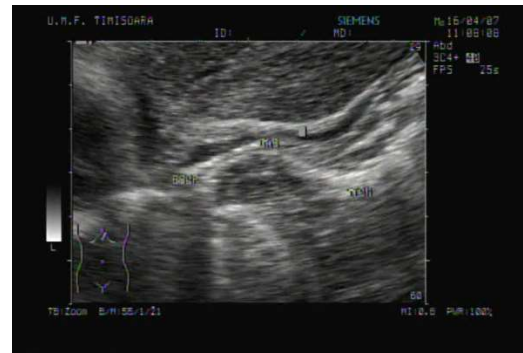

Fig. 5.2 Normal gastroesophageal junction

In some situations we may examine the patient in sitting position, which makes the junction easier to visualize; if the patient drinks water, its passage will look like an hyperechoic bolus due to mixed air. Thus a possible passage difficulty may be evidenced and monitored, or the junction may be visualized more clearly.

The cancer of the gastroesophageal junction appears as a hypoechoic mass varying in size, located in the junction area. The tumor contains air, like any digestive structure, and water swallowing will allow to obtain additional ultrasound information. The exploration of the area surrounding the tumor usually detects adenopathies (round or oval hypoechoic structures), 1-3 cm

in diameter, which prompts the TNM stage. Confirmation of the ultrasound suspicion of a gastroesophageal junction tumor is made by upper endoscopy with biopsy, by endoscopic ultrasound (for mediastinal involvement and lymph nodes), as well as by CT (extension and lymph nodes).

Highly located esophageal tumors (superior third of esophagus) may sometimes be visualized through left lateral cervical sections (with a linear transducer, using the left thyroid lobe as window). In this case, drinking water during the examination may be useful for the diagnosis. The middle esophagus is impossible to examine by ultrasound, because of its deep location in the mediastinum.

Achalasia may sometimes be diagnosed by ultrasound. The patient often presents paradoxical dysphagia (rather for liquids than for solids), with long-term evolution of swallowing disturbances. Achalasia is caused by absence of or incomplete relaxation of the lower esophageal sphincter when the alimentary bolus reaches this level. The esophagus above the narrow segment will consequently dilate.

Transabdominal ultrasound shows normal gastroesophageal junction walls, as well as hyperechoic matter above (food, aired saliva). The ultrasound aspect above the junction resembles a radish with a thin tail. Water ingestion will show the water reaching the junction, while relaxation disturbances and the replacement of primary peristalsis with tertiary aperistaltic contractions will make the passage of water through the junction impossible. Differential diagnosis of the GEJ cancer should be made firstly with achalasia, in which the junction walls are normal. Diagnostic endoscopy with biopsy and/or barium swallow, or esophageal manometry are mandatory for the diagnosis.

Hiatal hernia may sometimes be diagnosed by ultrasound, by seeing an airy structure near the gastroesophageal junction. Water administered during the examination will pass inside the herniated sack. Hiatal hernias can be diagnosed by endoscopy and barium swallow in Trendelenburg's position.

2. THE STOMACH

From the point of view of medical sonography, the stomach is the digestive tract segment most easy to examine by transabdominal ultrasound. The high incidence of gastric diseases (cancer, lymphoma, gastric emptying disturbances etc.) makes gastric transcutaneous ultrasound an interesting part of this area in medicine.

The stomach may be examined in fasting conditions, through epigastric transverse or sagittal sections (fig. 5.3). The gastric antrum is often visualized, with its barbell shape in epigastric transversal section. This aspect is already familiar from the chapter of pancreas examination (the antrum delimits anteriorly the pancreatic body). Antral walls are 3-4 mm thick; using linear high frequency transducers we may evidence 5 layers, as follows, from the most inner to the most outer layer: hyper-hypo-hyper-hypo-hyperechoic. The most visible layer is usually the last hypoechoic one, corresponding to the muscularis propria.

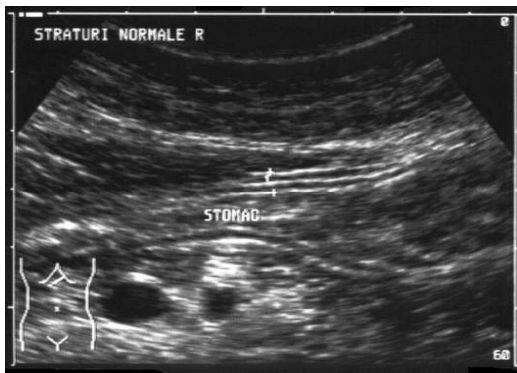


Fig. 5.3 Stomach antrum with normal layers

The ultrasound examination of the vertical gastric segment and the fornix is more difficult, first of all because of the presence of air. In case of incomplete or difficult visualization, 500-700 ml still water will be orally administered to the patient. When the water reaches the stomach, it will appear as hyperechoic due to its mixture with air. 10-15 minutes after the water administration it will become anechoic and thus facilitates the stomach examination. In these conditions the antrum may be almost always visualized. Trendelenburg's position will help the water reach the fornix, making it more visible. The anterior and posterior faces of the stomach also become visible, with the exception of the small and great curvatures.

Gastric cancer is a frequent malignancy both in men and women. In the developed world the prevalence of distal gastric cancer tends to decrease, while that of gastroesophageal neoplasms increases. This tendency seems to be related to *Helicobacter pylori* (HP) eradication campaign, a 1st rank oncogen according to WHO. In developing countries, where HP infection is more frequent and eradication less systematic, the prevalence of distal cancer remains high.

Gastric cancer may be: protruding type (ulcero-vegetative) or infiltrative one. Unfortunately, far too often we diagnose gastric cancers in advanced stages, with large, invasive tumors and with metastases.

The *clinical presentation* of gastric cancer has changed since the description of classical symptoms (meat anorexia and palpable Virchow-Troisier lymph node). Thus, to diagnose gastric cancers in an operable stage, with long-term survival rates, upper GI endoscopy should be performed in case of any suspicious dyspepsia (weight loss, anemia etc.).

However, abdominal ultrasound is much more frequently performed than endoscopy. On routine ultrasound examination suspicious changes of the gastric wall can be found. An accurate assessment of these changes is required, with or without water ingestion. A presumed ultrasound diagnosis is made, to be confirmed by endoscopy and endoscopic ultrasound (EUS).

The ***transabdominal ultrasound aspect*** of an antral cancer is that of a hypoechoic thickening of the gastric wall, with obliterated layers (fig. 5.4, fig. 5.5). The wall may be 10-15 mm or even 20 mm thick. The thickening might be even or uneven. Assessment of gastric walls thickness (especially of the antrum) will be performed through sagittal sections. By this approach the neoplastic antrum looks like a "target" lesion. Because of tumoral invasion the gastric lumen appears narrowed, revealing the ultrasound aspect of a malignant stenosis (Fig. 5.5), with absent

peristalsis. Pyloric stenosis leads to delayed gastric emptying - stomach full of large amounts of liquids and solids, that will appear as anechoic and hypoechoic on ultrasound (fig. 5.6, 5.7). During a careful examination, 1-3 cm peritumoral lymph nodes can be seen around the stomach, which should be described in detail, in order to assist surgery. The attentive evaluation of the liver may reveal possible liver metastases. Liver metastasis detection can be increased using CEUS. In cases of difficult visualization of gastric suspicious areas, water administration and re-examination may help.

The gastroenterologist performing the ultrasound examination has the advantage of being able to confirm the diagnosis by endoscopy. If a protrusive lesion cannot be visualized during endoscopy, but the ultrasound showed a thickening in the gastric wall, a biopsy from that area should be performed, as it might evidence a gastric lymphoma (with special colorations), linitis plastica or leiomyoma (all of them requiring diagnostic EUS).

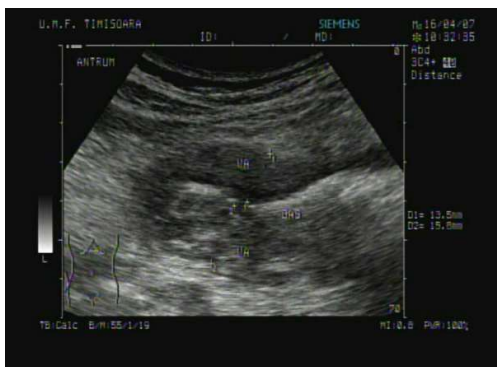

Fig. 5.4 Ultrasound aspect of antral cancer

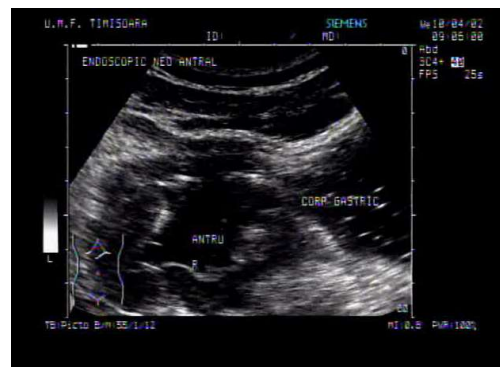

Fig. 5.5 Ultrasound aspect of antral cancer

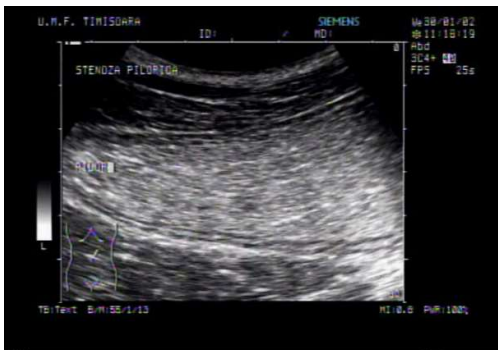

Fig. 5.6 Pyloric stenosis - delayed gastric emptying

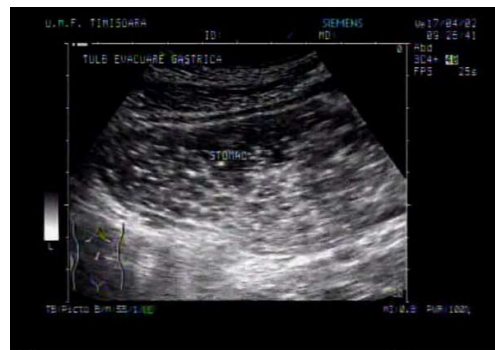

Fig. 5.7 Delayed gastric emptying

Leiomyoma is a benign muscular tumor that originates from the muscularis mucosa or the muscularis propria. It is a tumor localized in the submucosa, usually discovered during endoscopy. It appears as a protrusion into the lumen, but with a normal mucosal aspect. The endoscopic sign of the “tent” may be used, which consists of pulling up the mucosa with the biopsy pincers (the

mucosa detaches from the tumor). Generally, endoscopic biopsy cannot establish the histological diagnosis of leiomyoma. Ideally an EUS examination should be performed.

Gastric lymphoma (or other digestive lymphomas) are relatively frequent conditions. It is a non-Hodgkin lymphoma and it can be either a primary disease of the stomach, or secondary to another location.

The transabdominal ultrasound aspect of gastric lymphomas is that of an even thickening of the gastric wall, often affecting the entire wall. An image of gastric “target” is obtained by transversal section, the wall being hypoechoic, and the air hyperechoic. In discovering such a lesion, ultrasound cannot tell whether it is a lymphoma, linitis plastica or a gastric carcinoma. If splenomegaly and multiple lymph nodes are associated, we may consider a systemic lymphoma.

In order to clearly explain gastric alterations, endoscopy with biopsy, EUS for the assessment of wall layers and CT for assessment of thoracic and abdominal lymph nodes involvement are needed.

Gastric emptying insufficiency (delayed gastric emptying) by pyloric stenosis is one of the easiest ultrasound diagnoses. The patient complains of vomiting (several hours after meals), or vomiting in the morning the contents of the last dinner. The patient usually has a history of duodenal ulcer, as it is a known fact that pyloric stenosis can be a complication of duodenal ulcer. Other causes of pyloric stenosis are malignancies (antral cancer), or rarely large antral polyps obstructing the pylorus.

Ultrasound characteristics of a benign pyloric stenosis are thin antral walls, with normal layers. Malignant pyloric stenosis is associated with thick antral walls, anfractuous and hypoechoic. Endoscopic confirmation is often difficult because the stomach is full of alimentary debris.

From the ultrasonographic point of view, pyloric stenosis is characterized by an enlarged stomach, full of mixed liquid and solid content (fig. 5.8, fig. 5.9). The solid hyperechoic component is situated at the bottom, with anechoic content of liquid stasis above. The stomach may be hyperkinetic, trying to overcome the pyloric barrier. In other cases, the peristalsis is weak. After diagnosing the stenosis, the next step is to differentiate between a benign vs. a malignant cause.

Gastric emptying disturbances (gastroparesis) may also be diagnosed by ultrasound. Sometimes the ultrasound aspect of pyloric stenosis is found in a diabetic patient (diabetic gastroparesis), or in a patient with no medical history (idiopathic gastroparesis). Endoscopy will reveal the stomach full of alimentary debris, but, strangely, the pylorus will be open, easily passable with the endoscope. It is a gastric motility disturbance, entailing gastric emptying difficulties, despite the fact that the pylorus is open.

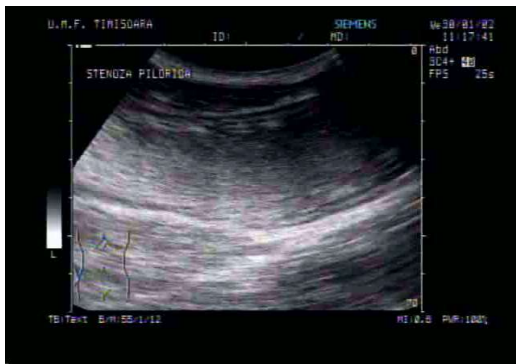

Fig. 5.8 Pyloric stenosis

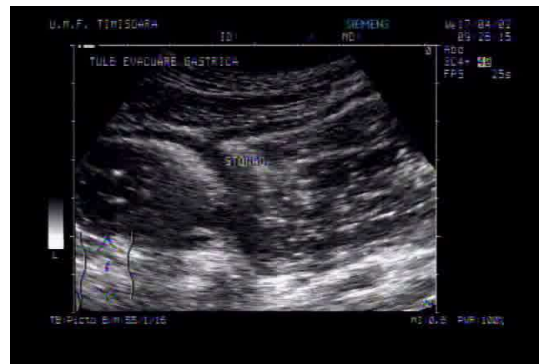

Fig. 5.9 Gastric emptying disturbance

In patients with diabetes mellitus, ultrasonography is used to assess gastric emptying or early gastroparesis. After a standard meal, the ultrasound examination will focus on an antral sagittal section, at the level of the upper mesenteric vein (or aorta). The length and width of the area are measured in fasting conditions, then every 30 minutes for a total time of 180 minutes. The meal may be liquid (tea, soup), 600 ml, or liquid and solid (tea, bread and butter). Generally the antral area restores to fasting dimensions within 90 minutes, while in gastroparesis this process takes longer (depending on the severity).

This technique may also be used to assess the effects of prokinetic medication on the stomach (domperidon, erythromycin).

Other pathological gastric conditions that may be diagnosed by ultrasound in some cases are: ulcers, polyps, phytobezoar, Menetriere's gastritis, portal hypertension gastropathy (by routine ultrasound, this being an incidental diagnosis as ultrasonography is not part of the diagnostic algorithm in these diseases).

Gastric ulcer may sometimes be diagnosed by ultrasound. Incidentally, an ulcer might be visualized during ultrasound examination, but the location will be pointed by endoscopy. The ulcer will appear as hyperechoic (because the air is present in the ulcer), situated in an area of hypoechoic thickening of the gastric wall.

Large *gastric polyps* (more than 1 cm), previously described by endoscopy, may be seen by US after administering water orally to the patient (especially antral polyps). Very rarely one can find large gastric polyps by chance, appearing as hypoechoic, well delimited masses inside the stomach. Upper endoscopy confirms the diagnosis.

Gastric phytobezoar is a structure consisting of vegetal debris and hair, which forms in the stomach in conditions of emptying disturbances. It may be totally asymptomatic. If the examination starts with an ultrasound, a structure resembling gallstones is seen in the gastric area (hyperechoic structure with posterior shadow, usually 3-5 cm in size). After water ingestion, the gastric phytobezoar becomes more visible and mobile. The only diagnosis problem is to be aware of this condition and take it into consideration. Endoscopy confirms the diagnosis.

Menetriere's gastritis or giant folds gastritis is a rare entity, which may be seen by ultrasound. Large gastric folds along the great curvature are seen by transabdominal ultrasound. Confirmation is made by endoscopy with biopsy.

Portal hypertension gastropathy (PHG) in liver cirrhosis may sometimes be seen by transabdominal ultrasound, as a slight thickening of the antral wall. Ultrasound signs of portal hypertension are also present.

In conclusion to the section regarding the US assessment of the stomach we can state that the ultrasonographer should take the time to examine this organ, in a patient with gastric complaints. Moreover, ingestion of still water will provide more diagnostic elements. Any ultrasound changes of the stomach must be confirmed by endoscopy. Also, if the clinician has an endoscopic diagnosis it should be followed up by transabdominal ultrasound, this way enriching his or her ultrasound experience.

3. THE DUODENUM

Duodenal diseases that can be diagnosed by using ultrasound are few, such as duodenal stenosis or duodenal ulcer.

Duodenal stenosis may be diagnosed by ultrasound. It may be caused by acute or chronic pancreatitis, by a duodenal tumor, a villous adenoma, an aorto-mesenteric clamp, a retroperitoneal tumor invading the duodenum etc.

Ultrasound will reveal liquid dilatation of the various duodenal segments (according to the obstruction site). Sometimes the peristaltic is vigorous, in the attempt to overcome the obstacle. The cause of stenosis should be looked for. It can be chronic pancreatitis (large pancreatic head, with calcifications, or pancreatic pseudocyst), or a duodenal tumor (benign or malignant). In chronic or acute pancreatitis the duodenal wall may be thick, due to edema. Duodenal stenosis by aorto-mesenteric clamp is much rarer. We may also found a retroperitoneal tumor invading the duodenum.

Duodenal ulcer may sometimes be diagnosed by ultrasound. We talk about large callous ulcers, with duodenal edema. Ultrasound will reveal a thick bulbar wall, hypoechoic due to edema, in which the ulcer niche will appear as a hyperechoic area due to the air in the niche. Endoscopy confirms the diagnosis.

We are against establishing the diagnosis of bulbar ulcer by ultrasonography, even in obvious cases, in order to avoid the misunderstanding by beginners regarding what can and cannot be seen. Visualizing such pathology by chance does not mean that ultrasonography is a diagnostic method in duodenal ulcer.

4. THE SMALL BOWEL

The small bowel is a segment of the digestive tract subject to difficult paraclinic evaluation. Plain abdominal X-ray in occlusive (or subocclusive) syndrome and evaluation using barium examination (enteroclysis) are classical means for the exploration of the small bowel. Endoscopic

examination (enteroscopy) is rarely used in Romania. The enteric capsule is used for situations in which a non-obstructive enteric disease is suspected. MRI enterography or CT enterography are used in suspicion of an enteric tumor or lymphoma. The examination of the terminal ileum is possible through colonoscopy, reaching beyond the ileocecal valve.

Under these circumstances, ultrasound examination in enteric pathology is a tempting alternative. It requires an experienced examiner, a high-performance ultrasound machine, with 3.5 MHz, 5 MHz and possibly 10 MHz (curved or linear) transducers.

Intestinal obstruction generates a clinical presentation characterized by abdominal pain, bloating, and no passage of stool or gas. Vomiting (sometimes fecal) occurs during evolution. The cause of intestinal obstruction can be in the small bowel (bridles, tumors, inflammatory stenosis) or in the colon (colon tumors, bridles, inflammatory stenosis). Plain abdominal X-ray performed in emergency reveals the presence of hydroaeric levels. Depending on the appearance of the dilated loops, the site of obstruction (small bowel or colon) can be located. However, it cannot be determined whether dynamic or paralytic ileus is present.

The ultrasound appearance of an intestinal obstruction consists of dilated intestinal loops upstream of the obstruction, filled with liquid (Figs. 5.10, 5.11). The "hydric level" can be very well visualized by ultrasound, the air being situated above the liquid level. A very intense peristaltic activity of the intestinal loops can be visualized in obstructive ileus. Inside the dilated loop, an anechoic fluid or, more frequently, intestinal chyme (a semi-solid structure containing particles in brownian motion) will be seen. If an ultrasound picture of intestinal obstruction is seen, the ultrasonographer must try to establish the site of obstruction. The dilated loop will be explored until the obstruction site is discovered. This is often very difficult, particularly in the case of bridle obstruction.

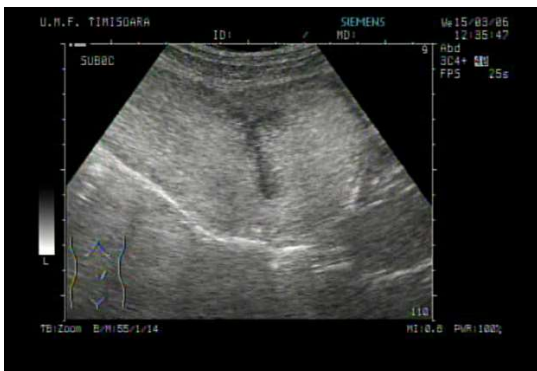


Fig. 5.10 Intestinal obstruction

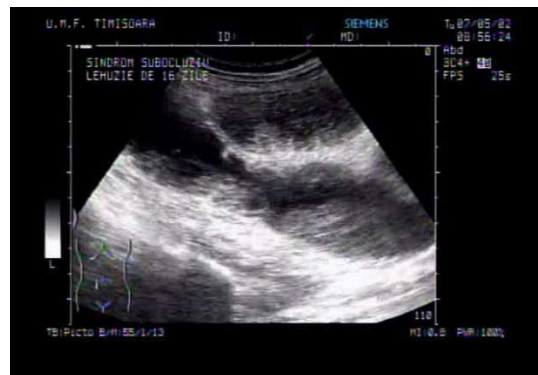

Fig. 5.11 Intestinal obstruction

In tumor obstructions, the dilatation of the loops stops at the level of the tumor. If the obstruction is caused by Crohn's disease, intestinal lymphoma or intestinal tuberculosis, a bowel area with a significantly thickened wall, indistinct layers and an obvious narrowing lumen will be found. However, it is almost impossible to establish the etiology by ultrasound.

Crohn's disease is an inflammatory disease of unknown origin that can affect any part of the digestive tract. It is most frequently located in the terminal ileum (hence the name of terminal ileitis), followed by the colon, and rarely by other segments of the digestive tract.

The clinical presentation of Crohn's disease is characterized by diarrhea, fever, weight loss, and diffuse abdominal pain, as well as the palpation of an abdominal mass or the development of complications such as fistula or stenosis. The clinical presentation of Crohn's disease is not always very suggestive, in some cases atypical symptoms can occur. It is a relatively common disease in Western Europe and USA, but until recently, quite rare in Romania. Over the past years, we have been confronted with an increase of Crohn's disease prevalence, possibly because of the westernization of our lifestyle, hence the need for an early diagnosis, before complications occur.

In a clinical suspicion of Crohn's disease, the following paraclinic investigations should be performed:

- colonoscopy with terminal ileoscopy;
- transabdominal ultrasound for intestinal evaluation;
- radiologic examination of the small bowel (enteroclysis);
- enteric capsule;
- possibly MRI enterography or CT enterography.

The choice of the diagnostic methods depends on their availability of the on the team's experience.

The ultrasound appearance in terminal ileitis is characterized by an obvious thickening of the terminal ileum wall, up to 10-15 mm (normal thickness is 3-4 mm), without a clear delimitation between the wall layers (Figs. 5.12, 5.13, 5.14, 5.15, 5.16). A segmental narrowing of the lumen over several centimeters, with upstream dilatation can be also seen (5.17). An anechoic inflammatory exudate in the proximity of the pathological loop can sometimes be seen. For an experienced ultrasonographer, the diagnosis of a severe complication such as stenosis or fistula (e.g. in the urinary bladder) is possible.

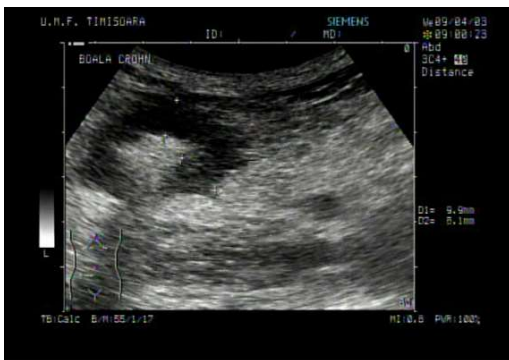

Fig. 5.12 Crohn's disease

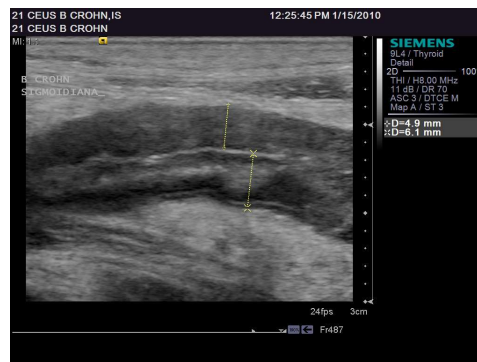


Fig. 5.13 Crohn's disease

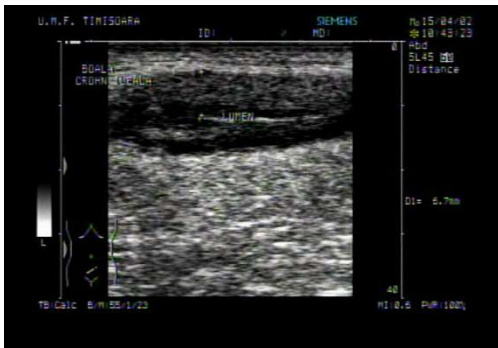


Fig. 5.14 Crohn's disease

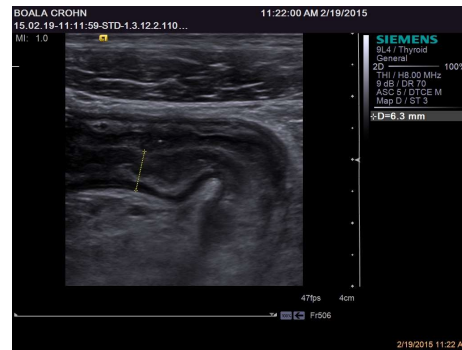


Fig. 5.15 Crohn's disease

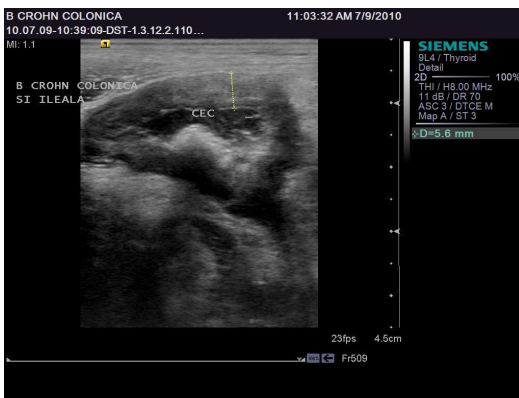
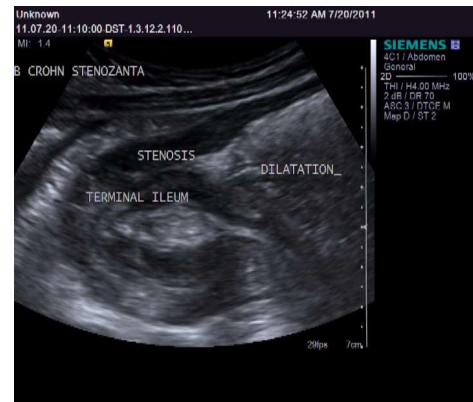

Fig. 5.16 Cecal and ileal Crohn's disease



5.17. Stenotic ileal Crohn disease

Treatment of Crohn's disease will lead to clinical improvement. It is possible to assess evolution by monitoring the ultrasound changes in the intestinal wall. In efficient treatment, the size of the intestinal wall will decrease, close to normal, obstructive phenomena as well as upstream dilatation will decrease.

Ultrasound will also assess potential colonic lesions, considering the possible involvement Crohn's disease.

In general, in the presence of chronic febrile diarrhea, it is important to carefully palpate the colon and the ileocecal region. If a mass is palpated, it will be assessed by ultrasound, usually with a 5-10 MHz transducer, in order to detect potential changes suggestive of Crohn's disease. Abdominal examination in chronic diarrhea starts with the right iliac fossa to reveal possible ultrasound changes in the terminal ileum.

The sensitivity and specificity of transabdominal ultrasound for the diagnosis of Crohn's disease are shown in the table below (Maconi paper):

Sensitivity and specificity of transabdominal US in the diagnosis of ileal Crohn's disease				
Ref	First author,year	Sensitivity %	Specificity%	Nr.p CD/ total nr p
1	Schwerk et al. 1992	96	85	128/267
2	Hata et al. 1992	86	97	36/104
3	Sheridan et al. 1993	78	91	24/96
4	Limberg et al. 1994	71	-	40/404
5	Bozkurt et al 1994	90	94	90/204
6	Solving et al 1995	95	93	20/59
7	Maconi et al. 1996	98	-	115/115
8	Hollerbach et al. 1998	84	-	69/175
9	Reimund et al. 1999	96	-	48/118

Maconi – Rom J Gastro 2003

The ultrasound appearance of intestinal Crohn's disease is almost impossible to differentiate from the one of intestinal lymphoma or intestinal tuberculosis. This is why, even if an appearance suggesting Crohn's disease is detected by ultrasound in the terminal ileum, total colonoscopy with ileoscopy and biopsy are required to certify diagnosis. The presence of a colonic lesion is evaluated by colonoscopy. Upper digestive endoscopy should follow for the detection of concomitant esogastro-duodenal lesions.

Intestinal lymphoma represents the intestinal location of this disease. Sometimes, intestinal involvement occurs in a patient with a known lymphoma. Diagnosis is easier in this situation. Much more difficult and rare is the primary intestinal location of lymphoma.

The ultrasound appearance is similar to that of Crohn's disease, with a marked thickening of the intestinal wall, which is hypoechoic, and with disappearance of the differences between layers. In the affected area, an obvious narrowing of the lumen can be seen, sometimes with upstream dilatation. Other signs of lymphoma may be detected: lymph nodes in various locations or splenomegaly.

Ultrasound monitoring under treatment is useful for the evaluation of the therapeutic response.

5. THE APPENDIX

In current clinical practice, the diagnosis of acute appendicitis is quite easy, starting from a suggestive clinical presentation, along with leukocytosis. In about 30% of the cases, acute pain has an atypical location or radiation, symptoms can be mild, and leukocytosis can be at the limit. In these situations, a correct diagnosis is imperative: is it or is it not an acute appendicitis?

Ultrasound may be a useful diagnostic method for an experienced examiner. Experience in appendicular ultrasound is achieved by clinical, imaging, surgical correlations.

To detect the appendix by ultrasound, the right flank is scanned downwards, while sliding the probe along the ascending colon and cecum (hyperechoic structures due to the air they contain), using a 5-10 MHz multi-frequency linear transducer. At the end of the cecum, the appendix will be seen. The appendix is easier to see in pathological situations. A normal appendix has an outer diameter of up to 6 mm and walls up to 2 mm thick. Operators trained for the ultrasound visualization of the appendix will be able to see it in up to 50-70% of cases, under normal conditions.

The ultrasound appearance in acute appendicitis is characterized by an appendicular diameter larger than 6 mm or by visualization of an appendicolith. The inflamed appendicular wall is thickened due to edema and stratification will disappear, in transverse section the appendix appearing as a “target” lesion. Inflammatory fluid reaction around it may also be seen.

For the ultrasound diagnosis of acute appendicitis, Goudet proposed major and minor diagnostic criteria.

Major diagnostic criteria include:

- an appendicular diameter greater than 7 mm;
- a “target” appearance of the appendix in transverse section;
- appendicoliths visible inside the appendix;
- visualization of an appendicular abscess.

Minor criteria include:

- visualization of the layers of the appendicular wall in longitudinal section;
- presence of intraluminal fluid in the appendix;
- presence of periappendicular effusion.

A positive diagnosis of acute appendicitis is considered when at least one major and two minor ultrasound criteria are met. Based on these criteria, Goudet found a 62.7% sensitivity of ultrasound in the diagnosis of acute appendicitis and a 88% specificity, but more recent German studies using modern equipment provide a sensitivity higher than 90% (but an experienced examiner, who sees many such cases daily, is required).

The ultrasound differential diagnosis of acute appendicitis should be made with terminal ileitis, cecum cancer, mesenteric adenitis and right adnexal pathology in women.

In conclusion, the ultrasound of the appendix is an adjuvant method for clinical diagnosis, particularly in atypical cases of acute appendicitis. In a typical clinical presentation with pain in the right iliac fossa and leukocytosis, no ultrasound confirmation is needed. In atypical cases, training will enable the use of ultrasound for supporting the positive diagnosis of acute appendicitis.

6. THE COLON

The last portion of the digestive tract, the colon, can benefit from the diagnostic contribution of transabdominal ultrasound.

The clinical presentation of a patient with colonic disease is extremely polymorphic, from diarrhea to constipation, rectal bleeding, weight loss, iron deficiency anemia or subocclusive syndrome. In the presence of such a clinical presentation, the ideal investigation is colonoscopy. On the other hand, the most digestive patients are initially subjected to abdominal ultrasound examination, aimed at providing additional diagnostic elements.

Careful abdominal palpation may reveal a mass situated along the colon that should subsequently be evaluated by ultrasound. The most important contribution of ultrasound is in the diagnosis of colon tumors, but ultrasound may also help diagnosis in ulcerative colitis (UC), Crohn's disease located in the colon or colonic diverticulitis.

Colon tumors are most frequently adenocarcinomas. They are among the most frequent malignant tumors both in men and in women. They are often detected in a late stage, due to complications (most frequently intestinal obstruction) or after the diagnosis of liver metastases.

It is recommended to scan the colic frame during an US examination, which sometimes leads to finding a “target” lesion along the colon tract, suggesting a colon tumor. In a palpable abdominal tumor, ultrasound examination may also detect an aerated tumor, belonging to the colon. In an iron deficiency anemia, the possibility of a colon tumor should be considered; if accompanied by rectal bleeding, it will be probably situated in the left colon, if not it will be probably situated in the right colon.

The ultrasound appearance of a colon tumor is of a “target-like” or “kidney-like” lesion (Figs. 5.18, 5.19). It is a hypoechoic mass with a central hyperechoic content. The air in the colon generates the central hyperechoic area. The colon wall changed by the tumor appears as hypoechoic, with variable thickness (10-30 mm), with a symmetrical or eccentric appearance. Generally, any tumor detected by ultrasound that contains air belongs to the digestive tract.

Lymph nodes (round or oval hypoechoic images) can be seen in the vicinity of the tumor. Liver ultrasound examination is compulsory in order to confirm or exclude liver metastases. Liver CEUS can improve liver metastasis detection.

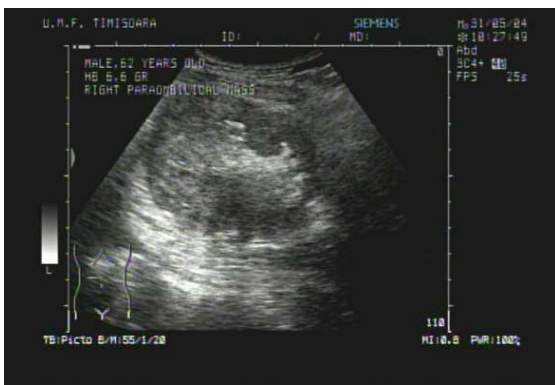

Fig. 5.18 Colon tumor – kidney like lesion

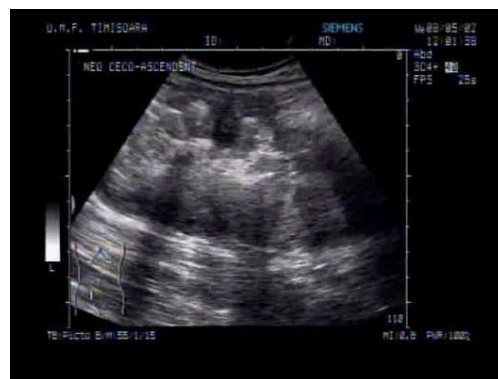

Fig. 5.19 Colon tumor – “target” lesion

For an inexperienced ultrasonographer, ultrasound examination of a tumor diagnosed by colonoscopy is recommended in order to get used to colon tumor images, as well as to assess the extraluminal tumor extension and the presence of locoregional lymph nodes.

A transabdominal ultrasound technique for the evaluation of the colon is *hydrocolonic sonography*. After the colon is prepared the same way as for endoscopic examination, an enema with 1500 ml water is performed, possibly preceded by injection of Buscopan. The water in the enema allows for a good visualization of the colonic lumen that will become anechoic. Thus, endoluminal excrescences as well as colon wall changes can be assessed. Thus, an experienced examiner will be able to see polyps larger than 5-10 mm, as well as possible colon tumors.

Hydrocolonic sonography has limitations due to the patients' difficulty to retaining the enema long enough to allow the examination of the entire colon. Also, in elderly patients, sphincter incontinence is often present, which makes the examination impossible (an inflatable rectal balloon catheter can be used for occlusion during examination). This method is probably outdated as the colon can be investigated by colonoscopy (or CT colonography).

The ultrasound differential diagnosis of colon tumors is made with Crohn's disease located in the colon, ischemic colitis, or retroperitoneal tumors (which are non-aerated tumors).

Ulcerative colitis (UC), an inflammatory colorectal disease, is characterized by chronic diarrhea with mucus, blood and pus. It is a relatively frequent disease in Romania and should be taken into consideration whenever there is an association of these symptoms.

The diagnosis is endoscopic. The endoscopic appearance is typical, rectal involvement is always present in the form of blood seeping mucosa. After the diagnosis, the extension of the disease should be assessed, which can be done by endoscopy or by ultrasound. Pan-colonic endoscopic examination during the active phase of UC has a high risk of complications (perforation, toxic megacolon). This is why recto-sigmoidoscopy with biopsy is preferred for positive diagnosis, while the extension can be evaluated by transabdominal colonic ultrasound.

The normal colon wall is 3-4 mm thick. When affected by UC, the colon wall reaches a thickness of up to 6-10 mm. A hyperchoic thickening of the inner layer (mucosa and submucosa) can be seen (Figs. 5.20, 5.21, 5.22, 5.23), usually with preserved stratification of the colon. The normal haustra of the colon (better visualized by hydrocolonic sonography) also disappear.

In the diagnosis of ulcerative colitis, transabdominal ultrasound examination will start from the rectum upwards, noting the place up to which there are pathological changes in the colon. This way, the UC can be classified as proctosigmoiditis, left colitis or pancolitis.

In ulcerative colitis lesions are continuous, while in Crohn's disease lesions are segmental. In Crohn's disease, there is a transmural involvement of the wall, with the disappearance of stratification while in UC the wall stratification is preserved for a long time.

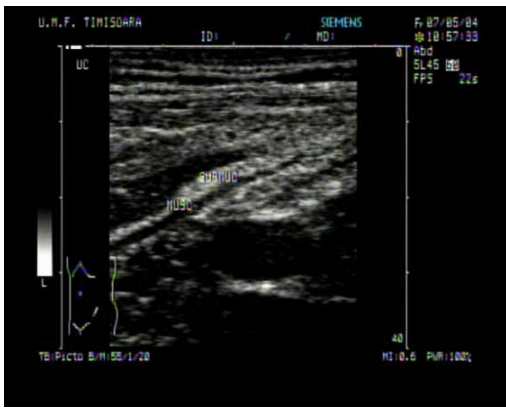


Fig. 5.20 Ulcerative colitis

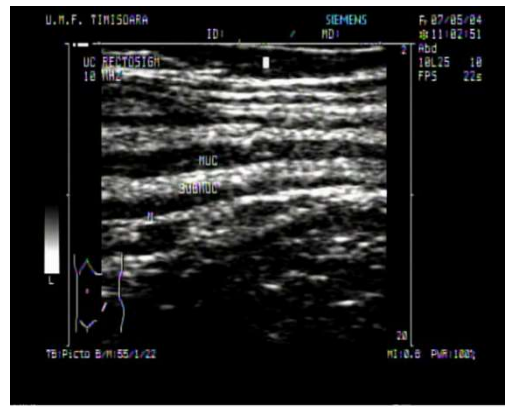


Fig. 5.21 Sigmoidian ulcerative colitis

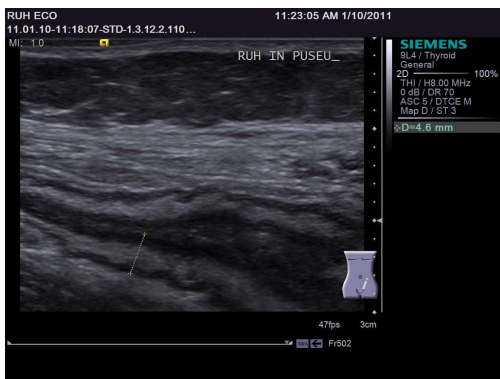


Fig.5.22 Ulcerative colitis

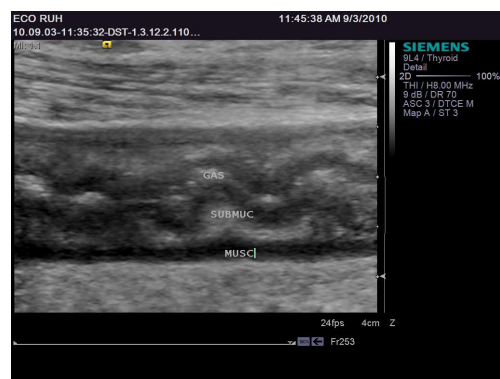


Fig. 5.23 Wall stratification in UC

The use of power Doppler allows assessing hypervascularization of the wall in an acute episode (more obvious in Crohn's disease).

The ultrasound differential diagnosis of ulcerative colitis should be made with Crohn's disease, ischemic colitis, and pseudomembranous colitis.

Diverticulitis is the inflammation of a colon diverticulum. Diverticulosis is a common disorder, but its complications such as diverticulitis or diverticular bleeding are rare.

The clinical presentation of diverticulitis is similar to that of acute appendicitis (pain, leukocytosis, possibly fever) most frequently the pain being located in the left iliac fossa since diverticula occur mostly in the sigmoid colon. In a clinical suspicion of diverticulitis, ultrasound can be the first line imaging method to use. It will demonstrate a hypoechoic area (the inflamed diverticulum) in contact with the colon (Fig. 5.24, 5.25), which usually contains air. The size of the hypoechoic area is usually 1-4 cm, but in abscesses, it can be even larger. The pressure of the ultrasound probe on that particular area induces intense pain.

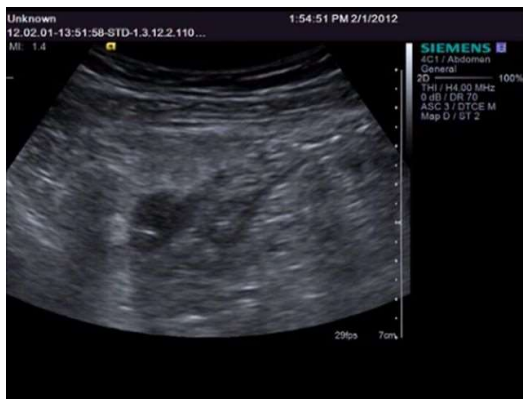

Fig. 5. 24 Acute diverticulitis

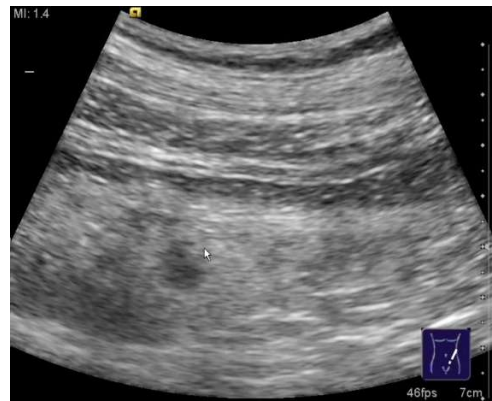

Fig. 5. 25 Sigmoid acute diverticulitis

In an unclear ultrasound diagnosis or in suspicion of diverticular abscess, CT with contrast is necessary. In suspicion of a diverticular abscess, CEUS can reveal inflammation or collection.

In conclusion, we must mention that the chapter on ultrasound of the digestive tract has an informative purpose for beginners, but can become part of clinical practice for experienced ultrasonographers.

Recently, the European Federation of Societies for Ultrasound in Medicine and Biology (EFSUMB) issued Guidelines and practical recommendations for the use of gastrointestinal ultrasound (GIUS). The first part deals with how to examine the digestive tube using transabdominal ultrasound. The second part is about the use of GIUS for the diagnosis of inflammatory bowel disease. The next Guidelines will be about the use of GIUS for inflammatory conditions (diverticulitis and appendicitis). All EFSUMB guidelines are available free of charge on the EFSUMB site: www.efsumb.org.

EFSUMB as well as SRUMB (Romanian Society for Ultrasound in Medicine and Biology) propose classification of ultrasonographers based on their experience and competence. Within this stratification, both organizations propose a beginner ultrasonographer level (ultrasound practice level I), then an advanced level, and finally, an expert level. We consider this classification very useful, as the beginner will have to differentiate between normal and pathological in ultrasound, the advanced ultrasonographer will be able to elucidate most of pathological aspects, while the expert will diagnose difficult cases.

CHAPTER 6

THE KIDNEYS

Ultrasound is currently the most frequent imaging technique used to diagnose kidney diseases. Intravenous urography is mainly used for the functional aspect of the kidney, while CT and MRI are mostly used for the differential diagnosis of tumor masses.

The kidneys are retroperitoneal organs, with sizes of 10-12/5-6/3 cm. Starting from the average size of these organs, the differential diagnosis of acute vs. chronic renal failure (large or small kidneys) can be solved by US. Kidney ultrasound examination is performed with standard 3.5 MHz, preferably convex transducers. The kidney ultrasound approach can be through the loins (the patient in ventral decubitus), by lateral approach (right lateral decubitus for the examination of the left kidney and scanning is performed through the left lateral abdominal region), or through sagittal sections in a patient in dorsal decubitus. The right kidney is easier to visualize in lateral sections or while the patient is in dorsal decubitus, using the liver as a sonographic window. For the left kidney, examination is easier in lateral or dorsal sections. Additional intercostal sections are also often used.

The normal ultrasound anatomy of the kidney includes the evaluation of the pyelum and the evaluation of the parenchyma (cortex). The normal pyelum is hyperechoic and the cortex is hypoechoic (Fig 6.1). The ultrasound distinction between the cortex and the medulla is possible only in children and thin persons. In current practice, this distinction is not possible, so the pyelum and the parenchyma will be discussed in relationship to the kidney.

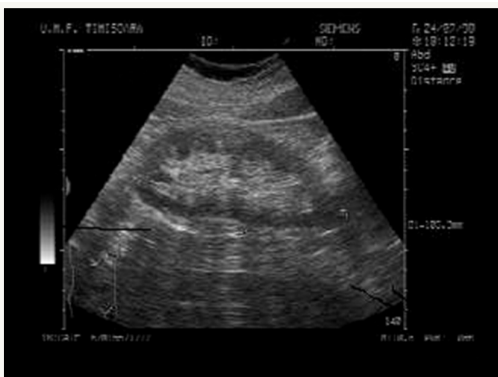

Fig. 6.1 Normal kidney

The kidneys have a slightly oblique axis, so that their scanning plane should adjust to this axis in order to obtain a complete image along the longitudinal kidney axis. In transverse section, approximately in the middle of the kidney, the renal hilum with the renal artery and vein can be

seen. The operator should know the anatomy of this region in order to be able to assess the vascular structures, if a venous (tumor) thrombosis or a renal artery stenosis are suspected.

Measurement of the kidney size is useful in some kidney disorders. Thus, the size of the kidneys decreases with age (renal senescence) or in chronic kidney failure; the kidneys can be enlarged in acute renal failure, in some diseases such as amyloidosis or diabetes mellitus, etc. Measurement of the three renal axes (length, width and thickness) will allow estimation of the kidney volume, which is much more reliable than measurement of the long renal axis alone. To calculate the renal volume, the ellipsoid formula is used ($V=0.5 \times \text{length} \times \text{width} \times \text{thickness}$).

Kidney ultrasound examination is part of the routine of every abdominal ultrasound examination. We consider that every abdominal ultrasound must be complete and examine all visible abdominal organs (gallbladder, common bile duct, intrahepatic bile ducts, liver, pancreas, spleen, kidneys, urinary bladder and pelvis, retroperitoneum), not just one organ (e.g. gallbladder or liver). This will allow to detect anomalies which often have important clinical significance.

The symptoms leading to kidney ultrasound examination are: colicky or dull pain in the lumbar region, hematuria, polakiuria, dysuria, signs of kidney failure, palpation of a tumor mass in the renal areas.

Kidney ultrasound examination will have to answer the following questions:

- are the kidneys present bilaterally (single congenital kidney)?
- do the kidneys have a normal size, shape and location?
- are there any changes in renal echogenicity (like in CKF)?
- are there kidney stones, and if so, are these obstructive (hydronephrosis)?
- are there tumor or cyst formations in the kidney? In case of a tumor, locoregional invasion will be established, and for cysts, it will be determined whether they are isolated or part of a polycystic disorder: renal, or hepato-renal, or hepato-renal-pancreatic.

When discussing kidney ultrasound examination, some normal entities that can pose difficult differential diagnosis problems should be described.

Fetal renal lobulation may persist in adults and will generate a bosselated renal outline on ultrasound. It should be differentiated from Kidney tumors or cysts. A renal anomaly termed mediorenal bulge or "dromedary hump" is frequently found in ultrasound practice, appearing as an outgrowth in the mid-kidney, with similar echogenicity as the renal parenchyma. Differential diagnosis should be made with a renal tumor (which usually is a circumscribed lesion with a different echogenicity from that of the kidney). In these cases, CEUS is extremely useful, because renal anomalies will behave like the renal parenchyma, while a renal tumor will have a completely different CEUS enhancement pattern (hyperenhancing or hypoenhancing).

Bertin's column hypertrophy may generate a renal mass effect. It is a hypoechoic mass that protrudes from the cortex towards the renal pelvis (Figs. 6.2, 6.3), with identical echogenicity to that of the cortex. It continues the renal cortex, is well delimited towards the pyelum and usually less than 3 cm in size. Ultrasound differentiation should be made with a renal tumor, which is poorly delimited and has a different echogenicity from that of the cortex.

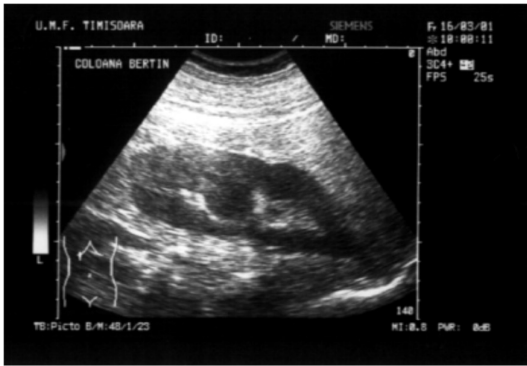

Fig. 6.2 Bertin's column hypertrophy

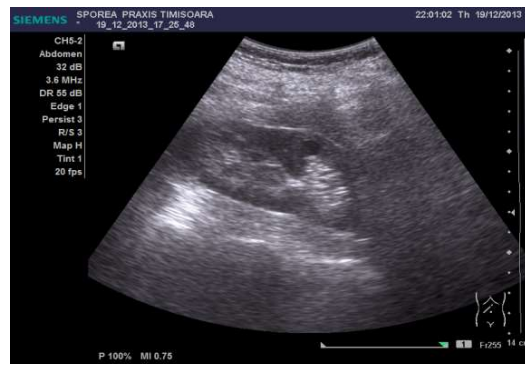

Fig. 6.3 Bertin's column hypertrophy

These two ultrasound entities (renal bulge and Bertin's column hypertrophy) are relatively common in ultrasound practice and an experienced ultrasonographer is needed to make a firm decision regarding the etiology of these entities. In uncertain cases, CEUS can conclude the diagnosis.

SIMPLE RENAL CYSTS

Definition: an entity with an unknown etiology and a high prevalence that increases with age. It occurs as a serous collection, with its origin in the renal cortex. Renal cysts can be single or multiple (rarely more than 5 cysts in a kidney) and have variable sizes (between 1 and 10 cm). Cysts are mostly unilocular, but sometimes may have inner septa.

On ultrasound, they appear as anechoic images, with fine walls (Figs. 6.4, 6.5, 6.6, 6.7), with variable locations in the kidney (they can be located in the cortex or around the renal pelvis). Very rarely, cysts may cause obstructive phenomena (hydronephrosis). Intracystic hemorrhage is rarely possible and the cyst will change from anechoic to partially or completely hypoechoic.

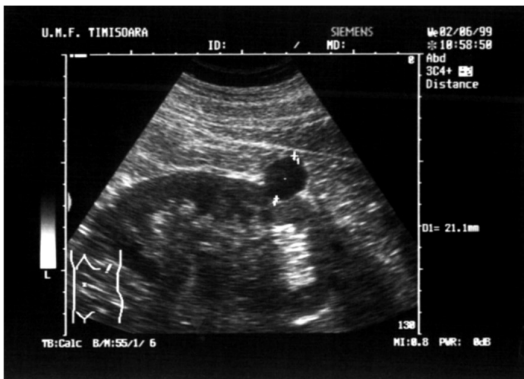

Fig. 6.4 Simple renal cyst

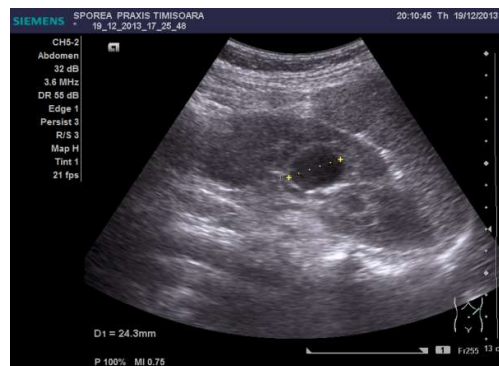

Fig. 6.5 Simple renal cyst

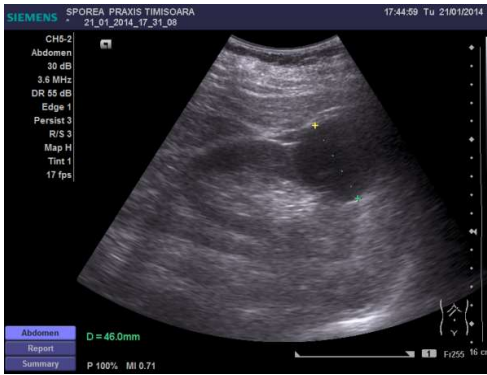

Fig. 6.6 Simple renal cyst

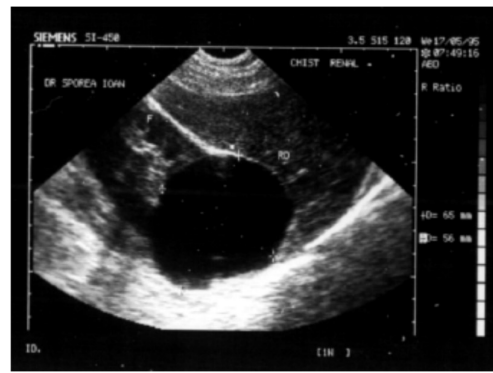


Fig. 6.7 Simple renal cyst

The ultrasound differential diagnosis of the simple cyst is made with a kidney hydatid cyst (thick wall, inner septa), necrotizing renal tumors, polycystic kidney, the oligocystic form and hydronephrosis. In uncertain cases (complex cysts, according to Bosniak classification), CEUS can clarify the diagnosis, because tumors and tumor septa enhance following contrast bolus, while cysts, even complex ones, will not.

In clinical practice, the patient with a simple renal cyst must be assured is not a dangerous condition, of the fact that this disorder is benign, that it does not require medical or surgical treatment and that ultrasound monitoring (once or twice per year) is sufficient, also that they are not a cause for lumbar pain.

POLYCYSTIC KIDNEY DISEASE

Definition: a disease with genetic autosomal inheritance, characterized by the presence of multiple bilateral renal cysts that significantly enlarge the kidneys and generate an unclear ultrasonographic delimitation of the organ.

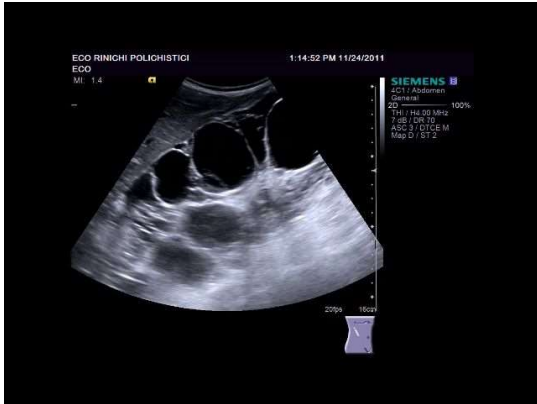
Polycystic kidney is sometimes associated with polycystic liver, and much more rarely, with pancreatic or splenic polycystosis.

In most cases, it is a congenital autosomal dominant disease, which is incidentally detected at the age of 30-50 years, following a hematuria episode, during the work-up of arterial hypertension or after the palpation of abdominal tumor masses. As a rule, this disease evolves into chronic renal failure, requiring hemodialysis.

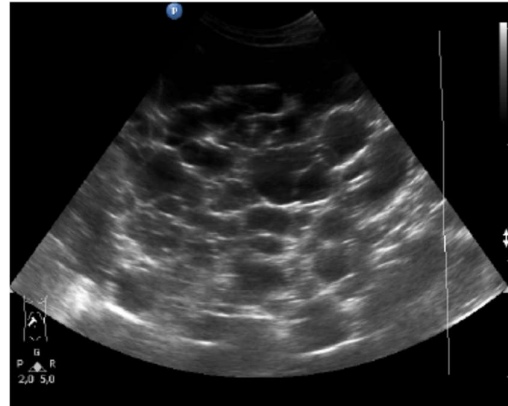
If a person with polycystic kidney is detected, all his/hers offspring should be examined by ultrasound to search for the disease. It is considered that if until the age of 20 years no renal cysts have developed in an offspring, he/she has not inherited the disease.

The ultrasound appearance of polycystic kidneys is specific: bilateral involvement, large, poorly circumscribed kidneys, with the presence of tens of renal cysts of variable sizes (generally 1-8 cm). The ultrasound appearance suggests grape clusters (Figs. 6.8, 6.9). The renal pelvis is not visible the whole kidney is changed into a cystic mass.

Polycystic kidneys are frequently complicated by kidney stones (sometimes difficult to diagnose by ultrasound), by intracystic hemorrhage (one or several cysts change from anechoic to hypoechoic), or by renal abscess (appearance similar to that of intracystic hemorrhage, but in a feverish patient, with a septic state).



Figs. 6.8 Polycystic kidney



Figs. 6.9 Polycystic kidney

The ultrasound differential diagnosis does not pose particular problems, because the imaging aspect is typical. Differential diagnosis can be made with multiple simple renal cysts (usually maximum 5-10 in a kidney), hydronephrosis, or with renal hydatid cysts with daughter vesicles (single cyst image with thick inner septa). Very rarely, the above mentioned renal disorders are bilateral.

The incidental ultrasound detection of renal polycystosis will be followed by the assessment of renal functional (urea, creatinine, creatinine clearance), to search for a potential renal failure. Also, the offspring of a patient with polycystic kidney disease will undergo ultrasound screening. It is recommended to refer the patient with renal polycystosis (or hepato-renal polycystosis) to the nephrologist, who will establish the monitoring strategy, given that in 5-10% of chronic hemodialysis cases, patients have a diagnosis of polycystic kidney disease.

MEDULLARY CYSTIC KIDNEY DISEASE

Definition: multiple cyst dilations of the medullary collecting ducts. The cause of this disease is unknown; it develops in adults, usually bilaterally. In general, it is an incidental finding. Renal function is usually normal.

The ultrasound appearance is not typical, because cysts are extremely small and difficult to see by ultrasound.

KIDNEY STONES

Definition: concretions in the collecting part of the renal system. It is a frequent condition. Kidney stones can be formed by calcium oxalate, calcium phosphate, ammonium-magnesium phosphate, uric acid or cysteine. Their formation depends on the family or personal predisposition, urinary salt concentration, change of urinary pH, presence of urinary infections, urinary tract anomalies.

The clinical presentation of kidney stones is most often of a common renal colic (intense pain in the lumbar region radiating to the pelvis, in the presence of pollakiuria, dysuria), hematuria, recurrent urinary infections. In some cases, kidney stones can be completely asymptomatic and are incidentally detected on ultrasound. Quite rarely they may generate anuria (bilateral uropathic kidney stones).

The ultrasound appearance of kidney stones is of hyperechoic images with a posterior shadow (Figs. 6.10, 6.11). Unlike radiology that will reveal only radiopaque calculi, in ultrasound kidney stones appear as hyperechoic regardless of their chemical structure, since they are obstacles that reflect ultrasounds.

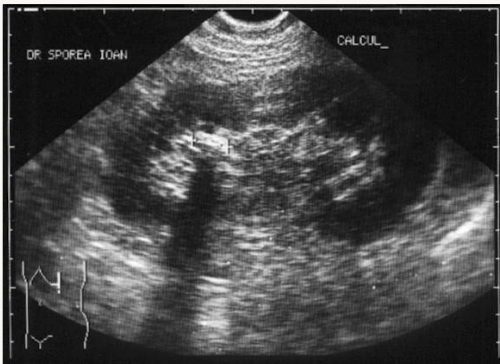


Fig. 6.10 Kidney stone

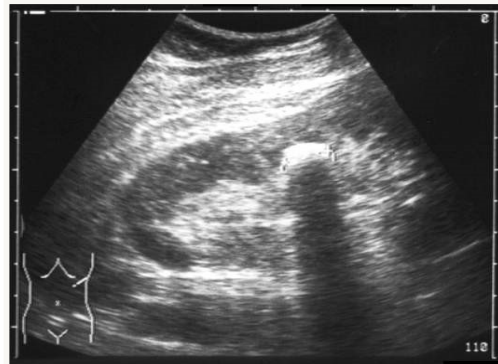

Fig. 6.11 Kidney stone

The diagnosis of kidney stones is somewhat difficult compared to gallstones. For gallstones, there is the benefit of the surrounding anechoic bile, with an obvious contrast between the bile and the calculus. In kidney stones, the hyperechoic calculus is situated in the renal pelvis - also hyperechoic. The presence of a posterior shadow behind the calculus certifies the diagnosis of kidney stone (Fig. 6.12). When a hyperechoic image is seen in the renal pelvis, without a posterior shadow, kidney stone diagnosis is doubtful since fibrous tissue, collagen or renal calcifications have the same appearance and are much more frequent.

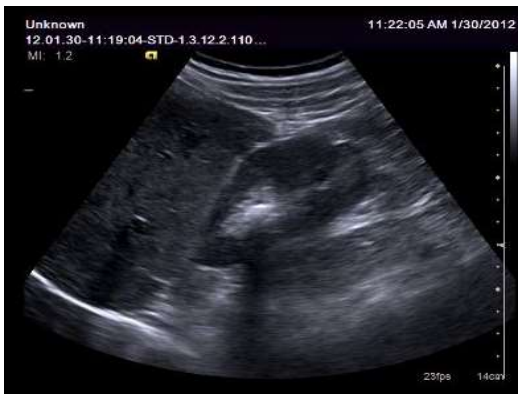

Fig. 6.12 Kidney stone – obvious posterior shadow

We wish to clarify an extremely widely circulated entity – the "renal microcalculi". It is a urine rich in urinary salts (which is normal if the patient is dehydrated). Many ultrasonographers yield to the temptation to describe it as "renal microcalculi" - a non-existing ultrasound entity. If ultrasound is performed for uni- or bilateral lumbar pain and no hyperechoic images with a posterior shadow are detected, the rheumatic etiology of pain is most common. The description of "renal microcalculi" will lead to inadequate therapy.

Detection of a kidney stone by ultrasound (hyperechoic image with a posterior shadow) will be followed by assessing its size for therapy: calculi smaller than 5-7 mm can be eliminated by natural routes, larger ones will need treatment – usually extracorporeal lithotripsy. The stone's location should also be assessed (in the renal pelvis or in the calyces) and whether it is obstructive or not (generating or not hydronephrosis).

The ultrasound diagnosis of a coral form kidney stone is often difficult because echogenic images with a posterior shadow are easy to visualize, but coral form extensions are difficult to assess (Fig. 6.13).

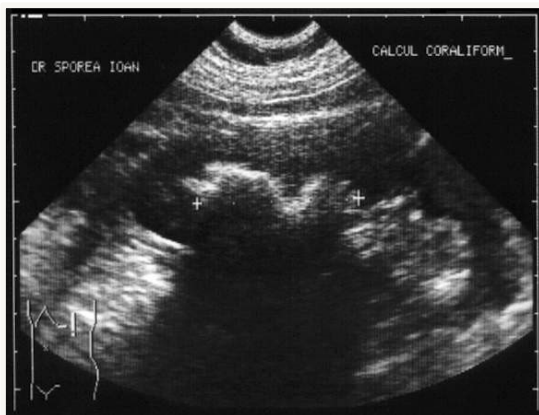

Fig. 6.13. Coral form kidney stone

In conclusion, the diagnosis of kidney stones is not always easy. They can be visualized as hyperechoic images with a posterior shadow larger than 2-3 mm (evaluation is performed through multiple longitudinal and transverse sections, which must demonstrate the presence of a hyperechoic image with a posterior shadow).

HYDRONEPHROSIS

Definition: expansion of the urinary tracts (calyx, renal pelvis and pyelo-ureteral junction) generated by an obstructive cause. The main cause of hydronephrosis are kidney stones, renal tumors, retroperitoneal tumors, genital tumors, prostate adenoma, blood clot, obstructive renal cyst.

The ultrasound appearance is quite specific: a triangular anechoic ultrasound image situated in the renal pelvis (Fig. 6.14). Hydronephrosis can be compared to a "palm" or a "goose foot". There are situations in which only hydropelvis is initially present, but hydrocalycosis will subsequently develop. The dilation of the pyelo-ureteral junction and of the ureter depends on the obstruction site.

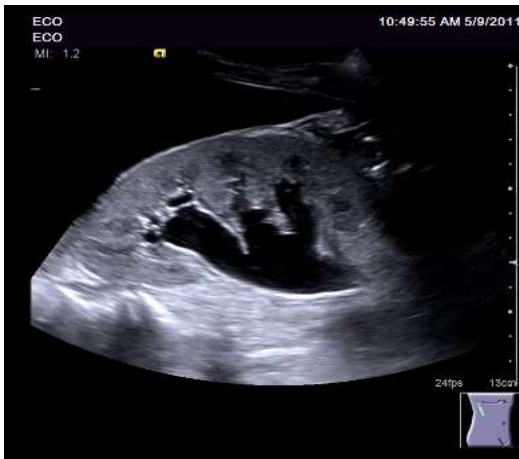

Fig. 6.14 – Hydronephrosis in a patient with ascites

The ultrasound diagnosis of hydronephrosis should be followed the evaluation of its severity: mild hydronephrosis - expansion of the renal pelvis, with a normal size cortex; moderate hydronephrosis - important enlargement of the renal pelvis with the narrowing of the cortex; severe hydronephrosis - severe enlargement of the renal pelvis, with significantly thinned cortex.

Subsequently, the cause of hydronephrosis will be searched for. Most frequently it is a calculus impacted at the pyelo-ureteral junction (Fig. 6.15) or a calculus that has migrated to the ureter. The ultrasound diagnosis of ureteral calculus is often difficult. The transducer will be moved along the dilated ureter (visible as a duct with anechoic appearance) until the hyperechoic calculus that blocks the lumen is seen. Visualization of a calculus impacted at the vesico-ureteral junction can be extremely difficult. Rarely, hydronephrosis is generated by a retroperitoneal tumor (Fig.6.16).

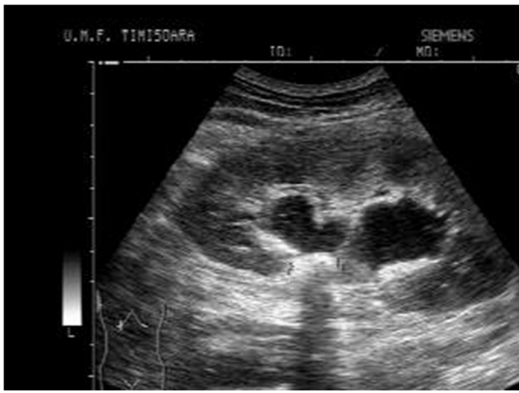

Fig. 6.15 Obstructive kidney stone – hydronephrosis

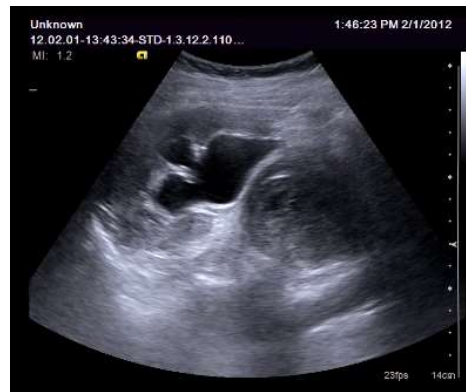

Fig. 6.16. Hydronephrosis generated by a retroperitoneal tumor

In bilateral hydronephrosis, a low obstruction should be considered: pelvic tumors, urinary bladder tumors, urethral stenosis, obstructive prostate adenoma, etc.

The ultrasound differential diagnosis of hydronephrosis should be made with simple juxtapyelic cysts; renal vascular ectasia - differentiation is made using power Doppler; renal sinus lipomatosis; papillary necrosis; bladder overloading - the patient drinks too much liquid before examination and is asked not to urinate, dilation is bilateral, after the patient urinates, bilateral "hydronephrosis" disappears; urothelial tumors - usually hypoechoic; acute pyelonephritis.

In cases in which the US diagnosis of hydronephrosis is not clear, urography can be used - the kidney will show no excretion in severe hydronephrosis. Other diagnostic techniques should be used for differential diagnosis: CT (for tumors, papillary necrosis, renal sinus lipomatosis), power Doppler ultrasound (for renal vascular ectasia).

KIDNEY CANCER

Definition: kidney carcinoma originates in renal tubular epithelium. It represents 1-3% of visceral cancers, with a male to female ratio of 3:1. It is more frequent in persons aged between 50-70 years.

The clinical presentation that leads to the diagnosis of kidney cancer includes capricious hematuria, unilateral lumbar pain and/or palpation of a tumor mass. The tumor has a tendency to vascular invasion (renal vein thrombosis) or lymphatic invasion. Metastases occur in the regional lymph nodes, in the lungs, bone, liver. A renal tumor can be an incidental finding, discovered during a routine ultrasound examination.

The ultrasound appearance of a renal tumor is mostly that of a hypoechoic (Fig. 6.17), rarely isoechoic (Fig. 6.18), or even hyperechoic mass (Fig. 6.19). The tumor size at the time of detection varies from 1-2 cm to giant sizes -10 cm or more. Large tumors are mostly inhomogeneous, due to necrosis and intratumoral hemorrhage. Renal tumors are generally hypervascularized and this can be seen by power Doppler.

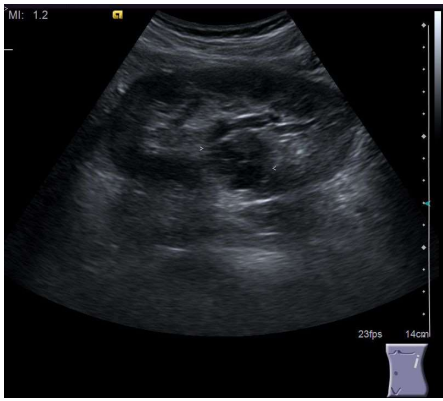


Fig. 6.17 Hypoechoic kidney tumor

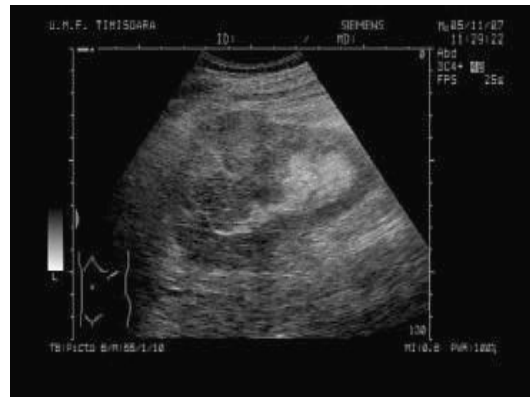

Fig. 6.18 Isoechoic kidney tumor

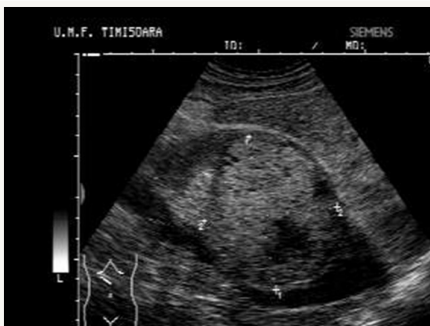

Fig. 6.19 Hyperechoic kidney tumor

Careful kidney ultrasound examination can also establish the stage of the kidney cancer: in stage I, the tumor is strictly intrarenal, in stage II it has spread to the capsule, and in stage III, vascular invasion, most frequently into the renal vein, is already present. Assessing renal motility (sliding) along the psoas during breathing is an important element for the evaluation of tumor invasion in the surrounding area (fixed tumor).

Detection of a kidney tumor by ultrasound should be followed by assessing its invasion into the renal vein, into the inferior vena cava and the search for potential liver metastases. The diagnosis is confirmed by intravenous urography, CEUS, CT, MRI and possibly by ultrasound-guided fine needle biopsy.

Other types of malignant renal tumors are urothelial carcinoma of the renal pelvis, Wilms tumor (pediatric nephroblastoma), renal lymphoma.

The contribution of contrast enhanced ultrasound (CEUS) is valuable, demonstrating a tumor with arterial hyperenhancement or sometimes hypoenhancement following contrast (there is no pathognomonic pattern). Distinction from other benign lesions such as complex renal cysts or Bertin's columns is quite easy.

The ultrasound differential diagnosis of kidney cancer can be made with renal or perirenal hematoma, hemorrhagic renal cysts, renal metastases, congenital renal bulges, Bertin's column hypertrophy, renal angioliipoma.

KIDNEY ANGIOLIPOMA

A particular ultrasound appearance is that of **kidney angioliipoma (angiomyolipoma)**. It is a benign renal tumor, composed of fat tissue, smooth muscle fibers and vascular structures. It appears as a well circumscribed hyperechoic mass (Fig. 6.20), 1-3 cm in size, situated in the cortex. From an ultrasound point of view, angioliipoma is very similar to hepatic hemangioma. Differentiation using CEUS is possible.

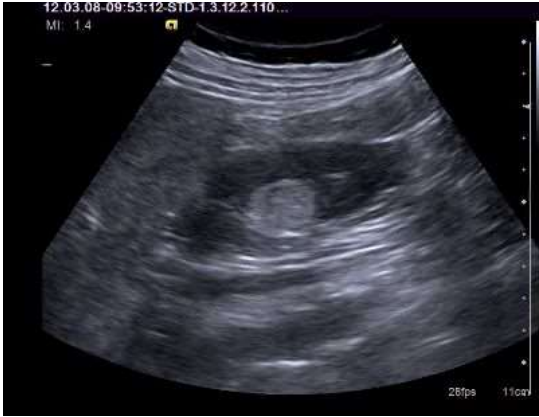

Fig. 6.20 Kidney angioliipoma

KIDNEY FAILURE

Definition: the incapacity of the kidneys to eliminate toxic metabolites from the blood. Kidney failure can be acute (AKF) or chronic (CKF).

When biological signs of renal failure are present (increased urea and creatinine), ultrasound is a particularly useful method for distinguishing AKF from CKF. In acute renal failure, the kidneys are large, while in chronic renal failure, they are mainly small.

Acute renal failure (AKF) is characterized by large kidneys - more than 12 cm along the long axis, and hypoechoic cortex due to edema (Fig. 6.21). In postrenal kidney failure ultrasound will reveal an obstructive appearance with bilateral hydronephrosis or single kidney hydronephrosis (congenital or surgical).

Chronic renal failure (CKF) is generally characterized by small kidneys (Fig. 6.22), with increased echogenicity of the cortex with the exception of amyloidosis and diabetic nephropathy.

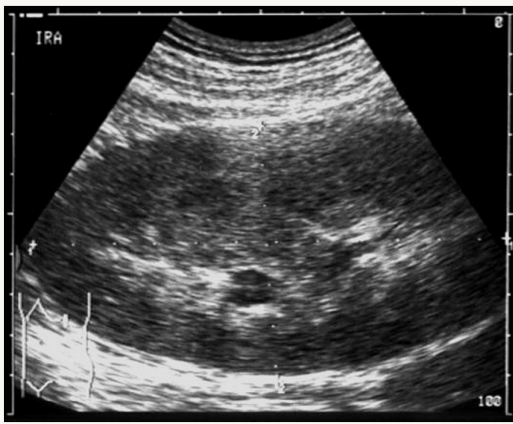

Fig. 6.21 Acute kidney failure

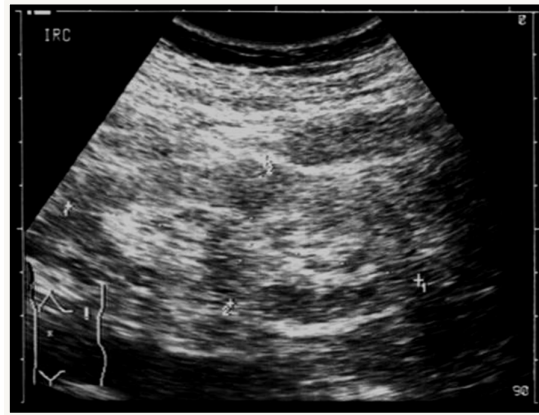

Fig. 6.22 Chronic kidney failure

In clinical practice, ultrasound may incidentally detect small kidneys, with diminished cortex-renal pelvis differentiation due to an increased echogenicity of the cortex, which suggests a CKF appearance. Nitrogen retention (serum creatinine and urea) and renal function (creatinine clearance) should be evaluated, which will confirm CKF and it will also assess its severity.

In advanced CKF, the kidneys are difficult to distinguish from the adjacent structures. They are echoic, with almost completely absent pyelum-cortex differences; renal retention cysts (1-2 cm) may also be observed. If an uropathic factor that exacerbates CKF is associated, hydronephrosis can be seen, requiring intervention for obstruction clearance. In advanced stages, the kidneys are 5-6 cm long and there are no significant size differences between the two kidneys, which are difficult to visualize by ultrasound. In contrast, if large kidneys are seen in CKF, old diabetes mellitus (even if unknown) or primary or secondary amyloidosis should be suspected and kidney biopsy for diagnosis should be taken into consideration.

In some situations, the kidney size is only moderately smaller (8-10 cm), but the kidney failure is severe. In these cases, CKF might have evolved into acute renal failure (dehydration, nephrotoxic drugs, etc.).

The role of ultrasound in other renal diseases is different. Thus, in the case of a **horseshoe kidney**, ultrasound can suggest diagnosis through a change of the renal axis, the absence of a clear landmark of the lower renal pole and particularly, through the visualization of the isthmus that joins the two kidneys (Fig. 6.23). In unclear cases, urography and computed tomography will help.

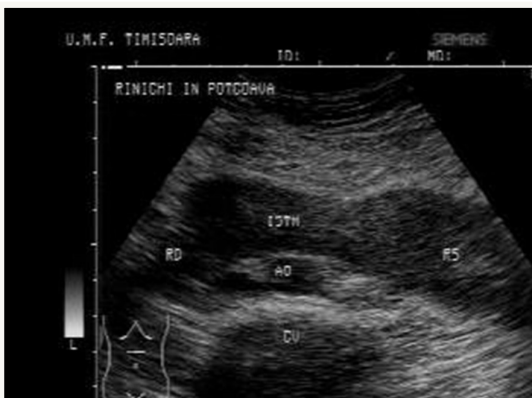

Fig. 6.23 Horse-shoe kidney: RS - left kidney; RD - right kidney; Ao - aorta; CV - spine; ISTM - connection between the two kidneys

Congenital single kidney is a very rare entity. Diagnosis is made by ultrasound when one of the kidneys cannot be seen by US. The single kidney is usually larger (more than 12 cm along the long axis), but is morphologically normal. The absence of a kidney will also be confirmed using intravenous urography (possibly abdominal CT), because there are cases in which a small congenital or pyelonephritic kidney cannot be seen by ultrasound (its echogenicity is similar to that of adjacent tissues). The presence of even reduced excretion on urography will identify the small kidney.

Single small kidney can be congenital or secondary. Ultrasound can accurately assess the kidneys size; a difference of more than 2 cm is considered to be pathological. The smaller kidney may be congenital or secondary to unilateral pyelonephritis, renal artery stenosis, etc.

Unequal kidney size may be a cause of secondary arterial hypertension, hence the need for a careful measurement of the long renal axis, in order to detect potential kidney size differences. Urography can be useful for assessing the functional secretory aspect.

Pyelocalyceal duplication can be evaluated by ultrasound: two separate central echoic complexes. This appearance should be confirmed by several section planes. Ureteral duplication cannot be examined by ultrasound. The exploration of choice for the diagnosis of pyelocalyceal duplication +/- ureteral duplication is urography.

THE ADRENAL GLANDS

The adrenal glands are pyramid shaped retroperitoneal organs, situated in the adipose tissue adjacent to the upper kidney pole. The right adrenal gland is situated between the right kidney pole, the right hepatic lobe, the right diaphragmatic crus and the inferior vena cava. The left adrenal gland lies between the left upper kidney pole, the aorta and the left diaphragmatic crus.

The ultrasound visualization of the normal adrenal glands is generally difficult, particularly for beginners in ultrasound. The right adrenal gland is easier to visualize because the liver plays the role of an ultrasound window. The area between the right hepatic lobe and the inferior vena cava, at the level of the upper kidney pole should be scanned to see the right adrenal gland. The examination of the left adrenal gland is more difficult (except in the presence of splenomegaly). Ventral decubitus facilitates the examination. The left adrenal gland is located between the upper kidney pole and the aorta.

We must emphasize that it is extremely difficult to visualize the normal adrenal glands due to their small size and deep location. They can be seen in thin patients. The method of choice for the evaluation of the adrenal glands is CT or endoscopic ultrasound for the left adrenal gland.

Adrenal tumors can be primitive or metastatic. They appear most frequently as hypoechoic masses situated in the adrenal region (Fig. 6.24). Sometimes, the tumor can appear as inhomogeneous, because of tumor degeneration and necrosis. Tumor sizes are variable (2-6 cm), but sizes up to 10 cm can also be found (Fig. 6.25). The ultrasound differential diagnosis of a primitive or metastatic adrenal tumor is extremely difficult. Adrenal tumors are generally well circumscribed and they can be seen by a competent ultrasound examination when they are quite small.

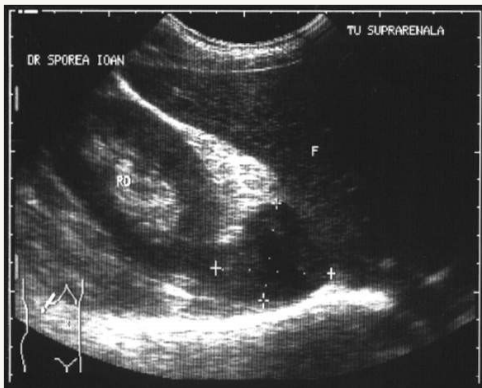


Fig. 6.24 Adrenal tumor

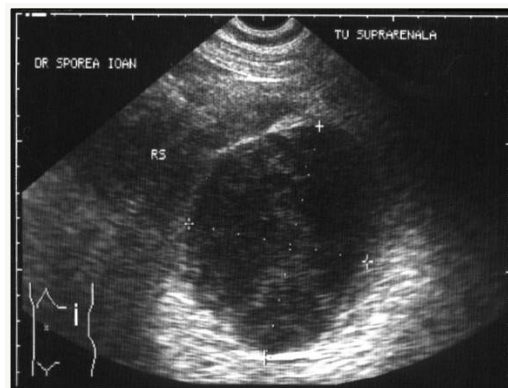


Fig. 6.25 Large adrenal tumor

The ultrasound differential diagnosis of adrenal tumors is made with other retroperitoneal tumors, periaortic or pericaval adenopathies, renal tumors, upper pole kidney cysts.

If an adrenal gland tumor is suspected by ultrasound CT is recommended, which assesses the gland size quite easily. In a clinical suspicion of pheochromocytoma, ultrasound is a good screening method. When ultrasound is inconclusive, computed tomography will be performed.

CHAPTER 7

THE RETROPERITONEUM

This chapter will deal with the pathology of retroperitoneal organs.

Retroperitoneal organs include the kidneys, adrenal glands, pancreas, aorta, inferior vena cava and the lymphatic system. As the first three were discussed in the previous chapters, we will focus on the abdominal aorta, inferior vena cava and the lymph nodes.

The abdominal aorta is located before the spine. It is examined by ultrasound in a sagittal section situated approximately on the median line. The aorta size, its content and its walls should be assessed. The normal aorta is up to 20 mm in diameter, with well visible, hyperechoic walls. It pulsates together with the heart beatings. In transverse section, the aorta is located before the spine, with the inferior vena cava to its right.

In transverse section, depending on the site of the section, the emergence of the celiac trunk can be seen, followed by the superior mesenteric artery at a lower level. The pancreas and the spleno-portal axis are seen anteriorly to the superior mesenteric artery.

Abdominal aorta aneurysm is the main aortic disorder that can be detected by ultrasound, appearing as a fusiform or saccular dilatation of the aorta, best seen in sagittal section (Fig. 7.1). In fusiform aneurysms, the transverse diameter is generally 3-5 cm with variable length.

Saccular aneurysms are rarer. In transverse section, they appear as a second anechoic image near the aorta (Fig 7.2).

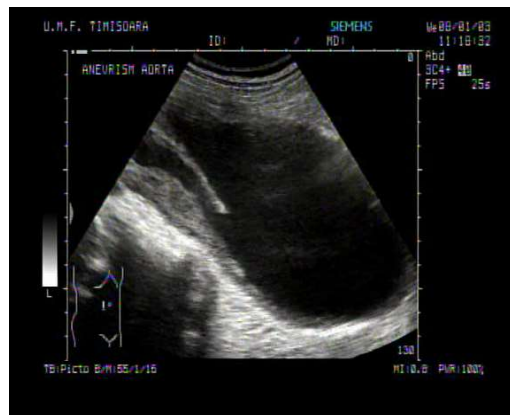
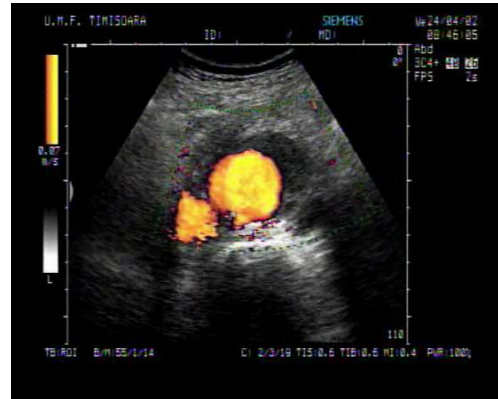
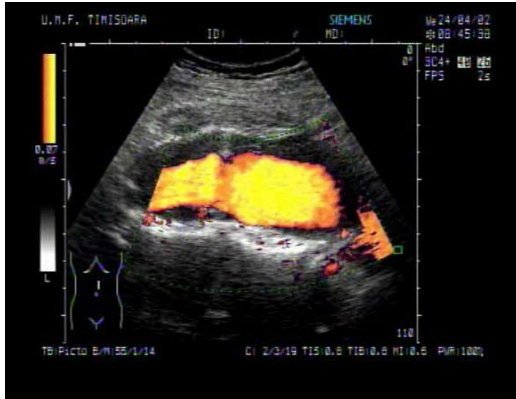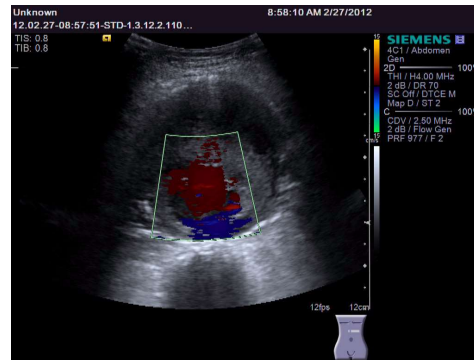

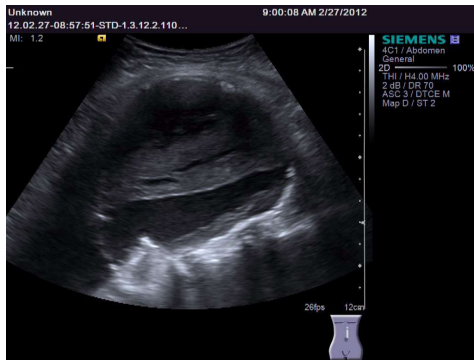
Fig 7.2 Aortic saccular aneurysm

Ultrasound can easily establish the presence of a **thrombus** in the **aneurysmal** lumen (Fig 7.3). This is a solid-like structure inside the aneurysm. The complementary use of power Doppler demonstrates a lack of vascular signal in the thrombosis area (Figs. 7.4, 7.5, 7.6, 7.7). Contrast enhanced ultrasound (CEUS) is an extremely useful method for demonstrating the complete or partial thrombosis of an aortic aneurysm. After the injection of the contrast agent, this will rapidly reach the permeable portion, but will not penetrate the thrombus.



Figs. 7.4, 7.5 Aortic aneurysm - absence of vascular signal in the thrombosed area
Power Doppler examination



Figs. 7.4 Aortic aneurysm with thrombosis 7.5 Aortic aneurysm - absence of vascular signal in the thrombosed area
Color Doppler examination

Ultrasound allows the assessment of a possible **dissecting aortic aneurysm** in which wall splitting is detected with blood flow at this level. The finding is an emergency that should be immediately referred to a vascular surgery service. CEUS is very useful, because it shows blood flow in the dissection area.

When ultrasound examination of the abdominal aorta cannot be performed because of intestinal gas, progressive pressure with the transducer is applied. The abdominal aorta can be also

visualized through the flank, avoiding the intestinal loops. Visualization of a normal aortic lumen will exclude aortic aneurysmal pathology.

Aortic aneurysms are detected by ultrasound in two situations: 1. the palpation of a pulsatile abdominal mass suspected to be an aortic aneurysm; 2. an incidental finding on routine abdominal examination.

Patients are frequently referred for ultrasound examination for a suspicion of abdominal aortic aneurysm because of the easy palpation of aortic pulsations. This usually occurs in thin persons, in which the aorta is surprisingly found 1.5-2 cm from the skin surface.

Ultrasound can detect **atheromatous plaques** of the abdominal aorta. They appear as hyperechoic plaques in the aortic wall, which also generate a posterior shadow if calcified. Extensive aortic atheromatosis is frequently found during the examination of the abdominal aorta in elderly subjects.

The inferior vena cava is the other major vascular structure in the lower abdomen. It is situated parallel to the aorta and is best examined by ultrasound in sagittal sections.

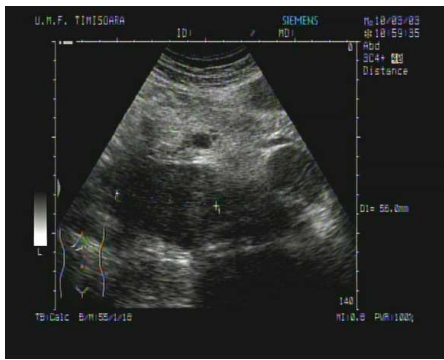
To examine the inferior vena cava, the transducer will be positioned in a sagittal section, slightly to the right of the median line. The inferior vena cava has great inspiration-expiration variability, changing its diameter in relation to the respiratory cycle. The diminution or disappearance of this variability is a sign of high pressure in the right atrium (right or global heart failure). In this case a dilatation of the inferior vena cava of more than 2 cm and a dilatation of hepatic veins (generating an ultrasound appearance of cardiac liver) will occur.

Another pathology of the inferior vena cava is **inferior vena cava thrombosis**. A thrombus in the inferior vena cava mainly occurs in malignant diseases, particularly kidney cancer (it usually develops concomitantly with renal vein thrombosis) or with hepatocellular carcinoma.

On ultrasound, the inferior vena cava thrombus appears as a solid-like structure inside the vascular lumen. Its size can vary. Detection of a malignant thrombus signifies loco-regional invasion and a worse prognosis. CEUS is useful for confirming the diagnosis of inferior vena cava thrombosis, as well as for assessing its extension.

Normal **abdominal lymph nodes** are not visualized by ultrasound. Lymph nodes should be searched for by US in specific conditions such as neoplastic disorders, in order to assess extension using the TNM system, or if a lymphoma is suspected.

Adenopathies appear on ultrasound as single or multiple round-oval hypoechoic masses, 1-4 cm in size (Figs. 7.8, 7.9, 7.10, 7.11, 7.12). They can be detected in the celiac lymph node group (around the celiac trunk), in the hepatic hilum or in the peri aorto-caval space.



Figs. 7.8 Adenopathies

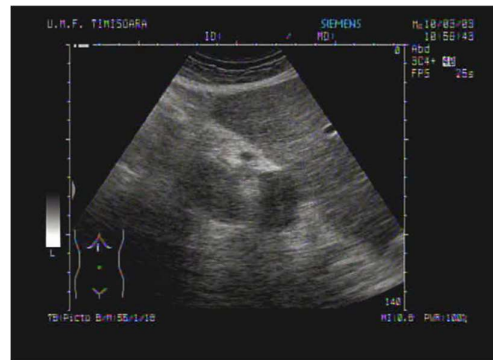
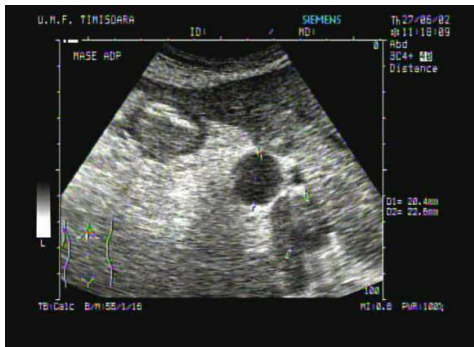
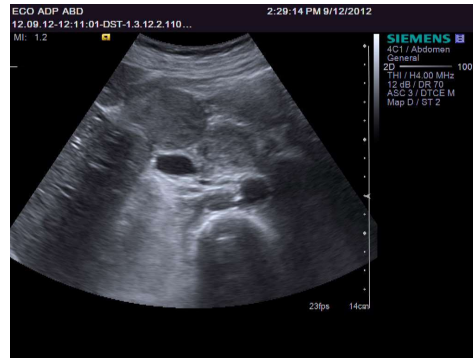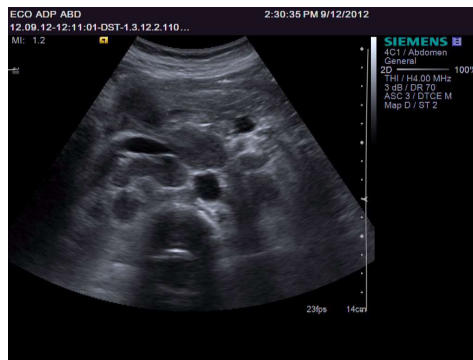Fig. 7.9 Adenopathies



Figs. 7.10 Adenopathies



Figs. 7.11 Adenopathies



Figs. 7.12 Adenopathies

In a known neoplastic disease (lower esophagus, gastroesophageal junction, stomach, colon, pancreas, etc.), ultrasound or CT will search for loco-regional or distant lymph nodes for staging the disease using the TNM system. The ultrasound evaluation of lymph nodes is difficult, requiring extensive experience. Known lymph node areas should be attentively scanned and vascular structures in transverse section should be differentiated from enlarged lymph nodes (in unclear situations, Doppler is useful). If the abdominal ultrasound window is not good enough, lymph nodes should be evaluated by CT or endoscopic ultrasound.

In lymphoma, assessment of abdominal lymph nodes contributes to disease staging, to make a therapeutic decision, and to monitor treatment efficacy. This is why ultrasound (and CT) for abdominal lymph nodes is of particular importance.

Another clinical situation is detection of enlarged lymph nodes on routine abdominal ultrasound. In these cases, it is mandatory to determine whether this is indeed a lymph node mass and to establish its etiology.

Most times, computed tomography is also required, which will accurately assess the location and number pathological lymph nodes and which may also assess mediastinal lymph nodes.

The ultrasound differential diagnosis of adenopathies is made with tumor masses (pancreatic, retroperitoneal), cystic lesions (anechoic), vascular structures in transverse section or aneurysmal vascular structures (differentiation is made using Doppler).

Retroperitoneal tumors are relatively rare (0.1-0.2% of all malignancies). This chapter will not include renal, adrenal or pancreatic tumors. Through a careful and competent examination, ultrasound may detect retroperitoneal tumors (Figs. 7.14) which will subsequently be evaluated by other imaging methods (CT, MRI).

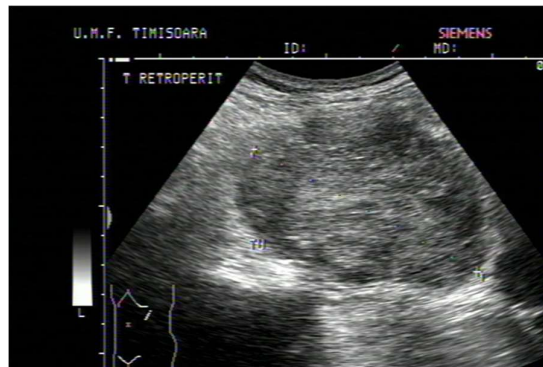


Fig. 7.14 Retroperitoneal tumor

The most frequent retroperitoneal tumors are *leiomyosarcoma* and *liposarcoma*. The latter is characterized by the size that can be impressive and by the fact that it infiltrates adjacent tissues. Leiomyosarcoma has a heterogeneous ultrasound appearance due to necrosis and intratumoral hemorrhage.

Detection of retroperitoneal tumors occurs relatively late, when they become symptomatic due to invasion of neighboring organs. Invasion of the digestive tract is responsible for vomiting, diarrhea, anorexia. Renal or ureteral invasion will result in hydronephrosis and urinary infections.

Ultrasound examination of the abdominal organs as well as of the retroperitoneum will sometimes allow detection of completely asymptomatic abdominal masses, frequently in early stages, with a favorable prognosis, hence the need to allocate sufficient time for each examination, i.e. 10-20 minutes. It might seem as too much time for an abdominal ultrasound, but it is justified if the examination of the retroperitoneal space and of the digestive tract organs is considered, in addition to the organs that are classically explored by ultrasound. The clinical examination preceding ultrasound, with the palpation of an abdominal mass, will help during the ultrasound examination, in establishing the location of the mass. If the tumor mass contains air, most probably

it is located in the digestive tract (stomach, colon), and if it does not contain air and does not belong to the known abdominal structures, it is a retroperitoneal tumor which should be subsequently evaluated by CT, MRI, and sometimes by ultrasound guided fine needle biopsy.

*

* *

This book was intended to be an insight into the clinical ultrasound of abdominal pathology. Knowledge of clinical findings and palpation of the abdomen will allow for a high quality ultrasound examination, anchored in the clinical reality. After describing the lesions detected by ultrasound, the examiner must draw a diagnostic conclusion and recommend complementary diagnosis methods. Continuing standard ultrasound examination with contrast enhanced ultrasound (CEUS) using SonoVue is valuable in some diseases and may frequently replace CT or MRI (much more expensive), particularly but not only in hepatic pathology. Monitoring the investigations' results and surgery outcome will allow to assess the thoroughness of ultrasound examination and to avoid errors in the future.