

PLASTIC SURGERY & CORRECTIVE DERMATOLOGY CONFERENCE

3RD Edition

21-23 OCTOBER 2022

Hotel Timișoara, Timișoara

Organizatori



Clinica Casa Austria



Asociația de Dermatologie Corectivă,
Chirurgie Dermatologică
și Dermatologie-Cosmetologie




Universitatea de Medicină
și Farmacie „Victor Babeș”
din Timișoara



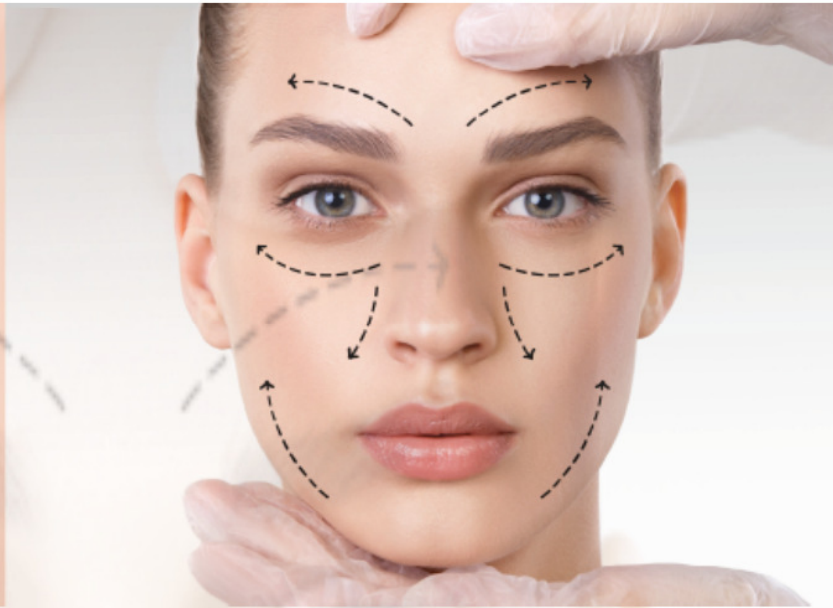Asociația Chirurgilor
Plasticieni din România

correctivedermatology.ro • office@correctivedermatology.ro

Management conferință



tel: 0730 565 430



Plastic Surgery & Corrective Dermatology Conference-3rd edition

October 21-23, 2022, Convention Center Timisoara

AESTHETIC AND RECONSTRUCTIVE APPROACHES OF THE FACE

Conference Presidents:

Prof.Dr. Tiberiu Bratu

Prof.Dr. Zorin Crainiceanu

The Scientific committee:

Prof.Dr. Alexandru Georgescu

Prof.Dr. Radu Jecan

Prof.Dr. George Sorin Tiplica

Prof.Dr. Nicolae Antohi

Conf. Dr. Cristodor Patricia

Dr. Radu Ionescu

Dr. Bogdan Dimitrie Niculae

Conf. Dr. Bogdan Savu

S.L. Dr. Alina Helgiu

S.L. Dr. Raul Chioibas

S.L. Dr. Gheorghe Noditi

Asist.Univ.Dr. Daciana Grujic

Asist.Univ.Dr. Vlad Bloanca

ABSTRACT BOOK

Editura „Victor Babeș”

Piața Eftimie Murgu 2, cam. 316, 300041 Timișoara

Tel./ Fax 0256 495 210

e-mail: evb@umft.ro

www.umft.ro/editura

Colecția: MANIFESTĂRI ȘTIINȚIFICE

Coordonator colecție: Prof. univ. dr. Danina Muntean

Referent științific: Prof. univ. emerit dr. Dan V. Poenaru

ISBN 978-606-786-285-0

© 2022 Toate drepturile asupra acestei ediții sunt rezervate.

Reproducerea parțială sau integrală a textului, pe orice suport, fără acordul scris al autorilor este interzisă și se va sancționa conform legilor în vigoare.

TABLE OF CONTENTS

THE IMPORTANCE OF LASER IN DERMATOLOGY, COMBINED TREATMENT TECHNIQUES PROPOSED TO PATIENTS.	5
SAVU B. – PROLASER FOUNDATION	5
IMPORTANTA LASERELOR IN DERMATOLOGIE, TEHNICI TERAPEUTICE COMBINATE PROPUSE PACIENTILOR.	5
SAVU B. – FUNDATIA PROLASER	5
WAYS OF USING LASERS IN DERMATOLOGY AND PLASTIC SURGERY: CUTTING (INCISION, EXCISION), VAPORIZATION, COAGULATION.	6
SAVU B. – PROLASER FOUNDATION	6
MODURI DE UTILIZARE A LASERELOR IN DERMATOLOGIE SI CHIRURGIE PLASTICA: TAIERE (INCIZIE, EXCIZIE), VAPORIZARE, COAGULARE	6
SAVU B. – FUNDATIA PROLASER	6
ANGIOSOME AND PERFORAZOME CONCEPT – APPLICATION IN FACIAL RECONSTRUCTIVE SURGERY	7
AUTORRRRRRRRRRRRRR	7
EYEBROW RECONSTRUCTION WITH HAIR-BEARING TEMPOROPARIETAL FLAP-CASE REPORT	7
ROXANA TOTOREAN, OANA MIȘCĂ, CRISTINA TOMA, LAURA VILCU, ZORIN CRĂINICEANU	7
SURGICALLY ASSISTED RAPID PALATAL EXPANSION- AN OVERVIEW	8
PRICOP M, URECHESCU H, SAMOILA C	8
FUTURE DIRECTIONS : SVF AND NANOFAT GRAFTING	9
FABIANA SIMION, GAURAV NARAD, VIVIANA NARAD, DACIANA GRUJIC	9
FUTURE DIRECTIONS : SVF. NANOFAT GRAFTING	10
FABIANA SIMION, GAURAV NARAD, VIVIANA NARAD, DACIANA GRUJIC	10
CORRECTIVE SURGICAL MODALITIES IN EYELID PATHOLOGY. TECHNICAL CHALLENGES AND COMPARATIVE RESULTS WITH PRACTICAL RECOMMENDATIONS	12
DR DANA-PETRONIA ULITA, DR. WAEL EL AMINE, DR CRISTIAN DUMITRASIUC, DR. GHEORGHE NODITI	12
MALIGNANT CUTANEOUS MELANOMA - " DISEASE OF MEPHISTO" (GOETHE-NIAN) - BACKSTAGE DATA FROM OUR CLINIC-.....	13
DR. DANA-PETRONIA ULITA, DR. WAEL EL AMINE, DR. CRISTIAN DUMITRASIUC, DR. GHEORGHE NODITI	13
“SELF-IDENTITY” SURGERY. PSYCHOLOGICAL IMPLICATIONS IN FACIAL AESTHETICS.....	13
ICA SECOȘAN, ZORIN CRĂINICEANU	13
LIFTING THE BROW, HOW TO KEEP IT SIMPLE AND EFFICIENT	15
BY DR.RAUL CHIOIBAS	15

TIPS AND TRICKS TO STAY AWAY FROM TROUBLE IN INFERIOR EYELID SURGERY.....	16
BY DR RAUL CHIOIBAS.....	16
ROLUL SEPTOPLASTIEI IN CADRUL RINOPLASTIEI.....	16
DR. N. C. BALICA, DR. I. C. MOT, DR. D. I. HORHAT	16
THE ROLE OF SEPTOPLASTY WITHIN RHINOPLASTY	17
DR. N. C. BALICA, DR. I. C. MOT, DR. D. I. HORHAT	17
THE KEY ROLE OF FUNCTIONAL ENDOSCOPIC SINUS SURGERY (FESS) IN THE MANAGEMENT OF RHINOSINUSITIS	17
ION CRISTIAN MOȚ, DELIA HORHAT, MĂRIOARA POENARU, EUGEN RADU BOIA, KRISTINE GURAN, ALINA TISCHER, RĂZVAN ZIMBRU, NICOLAE CONSTANTIN BALICA	17
UNRAVELING THE FUNCTIONAL ENDOSCOPIC SINUS SURGERY’S SIGNIFICANCE IN SINONASAL TUMORS.....	18
DELIA HORHAT, ION CRISTIAN MOȚ, MĂRIOARA POENARU, EUGEN RADU BOIA, KRISTINE GURAN, ALINA TISCHER, RĂZVAN ZIMBRU, NICOLAE CONSTANTIN BALICA	18
DOG EARS? NO PROBLEM	19
PATRICIA CRISTODOR, IASMINA-MARIA HÂNCU, VALENTIN TUDOR POPA, LAURENȚIU ILINCA, IUSTIN HÂNCU	19
INCREDIBIL, DAR ADEVARAT - UN TRATAMENT DERMATOLOGIC PENTRU PATOLOGIA LOMBARA.....	19
PATRICIA CRISTODOR, IASMINA HANCU, LAURENȚIU ILINCA, IUSTIN HANCU	19
ESTHETIC ASPECTS IN INTERDISCIPLINARY ORTHODONTICS	20
PROF. DR. CAMELIA SZUHANEK	20
THE COMBINED APPROACH OF NON-SURGICAL AND SURGICAL TECHNIQUES IN FACIAL AESTHETICS : WHEN, WHERE AND HOW	20
DR LJUBISA GRUJIC, DR DACIANA GRUJIC.....	20

THE IMPORTANCE OF LASER IN DERMATOLOGY, COMBINED TREATMENT TECHNIQUES PROPOSED TO PATIENTS.

SAVU B. – PROLASER FOUNDATION

The aging process and exposure to environmental factors produce changes that can be corrected through different therapeutic techniques. In this sense, corrective dermatology has 3 goals: uniformity of colour and appearance, reduction of wrinkles and rejuvenation of the skin. Because the changes concern the skin in its integrity and the exposure would be too long, the presentation includes only the main techniques that can fight the changes on the face and neck: ablative and non-ablative laser treatments, chemical peelings and dermabrasion. Laser treatments have multiple advantages compared to other methods: better control of the working depth, multiple mechanisms to reach the targets of corrective dermatology, with certain differences between ablative and non-ablative techniques. In addition, more precautions must be taken in the case of laser resurfacing. The ablative lasers used in corrective dermatology are: Er:YAG, CO2 and the fractional laser. The essential parameter on which the therapeutic result depends is the amount of energy (fluency) released to the target tissue. The useful amount of energy differs from one area to be treated to another because in different areas, the thickness of the skin is different and also the density of the skin appendages. The greater the fluency, the greater the penetration. The smaller the diameter of the spot, the higher the energy density and the greater the penetrability with a lower total amount of energy released.

IMPORTANTA LASERELOR IN DERMATOLOGIE, TEHNICI TERAPEUTICE COMBinate PROPUSE PACIENTILOR.

SAVU B. – FUNDATIA PROLASER

Procesul de imbatranire si expunerea la factorii de mediu produce modificari ce pot fi corectate prin diferite tehnici terapeutice. In acest sens, dermatologia corectiva are 3 tinte: uniformizarea culorii si aspectului, micșorarea ridurilor si rejuvenarea pielii. Pentru ca modificarile intereseaza pielea in integritatea sa si expunerea ar fi prea lunga, prezentarea cuprinde doar principalele tehnici ce pot lupta cu modificarile de la nivelul fetei si gatului: tratamente laser ablative si non-ablative, peeling-uri chimice si dermabraziunea. Tratamentele laser au multiple avantaje comparativ cu celelalte metode: control mai bun al adancimii de lucru, mecanisme multiple de a atinge tintele dermatologiei corective, cu anumite diferente intre tehnicile ablative si non-ablative. In plus, trebuie luate mai multe precautii in cazul resurfacing-ului laser. Laserele ablative folosite in dermatologia corectiva sunt: Er:YAG, CO2 si laserul fractional. Parametrul esential de care depinde rezultatul therapeutic este cantitatea de energie (fluenta) eliberata catre tesutul tinta. Cantitatea utila de energie difera de la o zona de tratat la alta pentru ca in diferite zone, grosimea pielii e diferita si de asemenea densitatea anexelor pielii. Cu cat fluenta e mai mare, penetrarea e mai mare. Cu cat diametrul spotului e mai mic, densitatea de energie creste si penetrabilitatea este mai mare la o cantitate totala de energie eliberata mai mica.

WAYS OF USING LASERS IN DERMATOLOGY AND PLASTIC SURGERY: CUTTING (INCISION, EXCISION), VAPORIZATION, COAGULATION

SAVU B. – PROLASER FOUNDATION

Surgical lasers can be used to cut, vaporize or coagulate. The most versatile and relatively cheap laser is the CO₂ laser. The transmission of laser radiation to the target tissue is done through an articulated arm provided with mirrors that direct the laser radiation to the tissue. At the end of the arm is the hand piece, provided with a spacer that allows maintaining the optimal distance for cutting tissues, the maximum focus of the beam being slightly below the surface of the target tissue. By moving the handpiece away from the fabric, the beam will defocus. The more defocused the beam is (larger diameter at the level of the tissue), the amount of energy will be dissipated, producing vaporization or coagulation instead of cutting. Depending on the working mode of the laser (continuous, ultra-pulsed or super-pulsed), the amount of energy is released in variable periods of time. The shorter this period is, the smaller the amount of energy dissipated outside the target area and the smaller the (unwanted) collateral thermal effect, so the incision is finer. Laser cutting is superior to scalpel and electrocautery. Tissue vaporization and laser coagulation are more effective than electrocautery

MODURI DE UTILIZARE A LASERELOR IN DERMATOLOGIE SI CHIRURGIE PLASTICA: TAIERE (INCIZIE, EXCIZIE), VAPORIZARE, COAGULARE

SAVU B. – FUNDATIA PROLASER

Laserele chirurgicale pot fi utilizate pentru a taia, a vaporiza sau a coagula. Cel mai versatil si relative ieftin laser este cel cu CO₂. Transmiterea radiatiei laser catre tesutul tinta se face printr-un brat articulat prevazut cu oglinzi ce dirijeaza catre tesut radiatia laser. La capatul bratului se afla piesa de mana, prevazuta cu un distantier ce permite mentinerea distantei optime pentru taierea tesuturilor, focalizarea maxima a razei fiind putin sub suprafata tesutului tinta. Prin departarea piesei de mana de tesut raza se va defocaliza. Cu cat raza este mai defocalizata (diametru mai mare la nivelul tesutului) cantitatea de energie se va disipa realizand in loc de taiere vaporizare, sau coagulare. Functie de modul de lucru al laserului (continuu, pulsat ultra- sau super-pulsat), cantitatea de energie se elibereaza in perioade de timp variabile. Cu cat aceasta perioada e mai scurta cantitatea de energie disipata in afara zonei tinta e mai mica si efectul termic colateral (nedorit) e mai mic, deci incizia e mai fina. Taierea cu ajutorul laserului este superioara bisturiului si electrocauterului. Vaporizarea tesuturilor si coagularea cu ajutorul laserului sunt mai eficiente decat electrocauterul.

ANGIOSOME AND PERFORAZOME CONCEPT – APPLICATION IN FACIAL RECONSTRUCTIVE SURGERY

AUTORRRRRRRRRRRRR

Scopul acestei lucrari este acela de a prezenta informatii despre teritoriului vascular al lambourilor perforante precum și a diferitelor tipuri de vase perforante descrise de catre G.I.Taylor utilizand diferite studii anatomice și de injectare. Acesta impreuna cu echipa sa de colaboratori au delimitat teritoriile vasculare la nivelul corpului uman, numindu-le angiozomi.

Angiozomul este definit ca o unitate tridimensională de țesuturi (mușchi, nervi, țesut conjunctiv și tegumentul supraiacent), hrănită de o sursă arterială principală și venele comitante care se află între piele și țesutul osos. Angiozomii pot fi subdivizați în teritorii arteriale (arteriozomi) și teritorii venoase (venozomi).

De asemenea, in partea generala este prezentat si conceptul perforazomului, al carui autor, M.Saint-Cyr a dezvoltat o serie de studii de anatomie vasculară, combinate cu angiogramografia computerizată statică și dinamică teritoriul vascular asociat fiecărui vas perforant arterial și care prezintă un model unic, multidirecțional și complex de flux sanguin, formuland astfel cele patru principii care stau la baza construcției anatomice a tuturor perforazomilor.

Utilizand aceste principii, actuala prezentare ilustreaza cele mai des intalnite lambouri locale practicate in chirurgia reconstructiva a fetei, punand accent pe importanta unei vindecari cat mai eficiente, atat din punct de vedere estetic cat si functional si totodata radicalitatea exciziei formatiunilor tumorale de tip malign.

In urma acestui studiu am concluzionat faptul ca lamboul de tip frontal are cel mai bun rezultat atat din punct de vedere functional cat si estetic in reconstructia defectelor post excizie de la nivelul nasului, pentru defecte mari sau defecte ce implica mai mult de doua subunitati nazala; lamboul avansat al obrazului restabilește într-o singură etapă detaliul conturului nazal respectând anatomia feței pentru defecte cuprinse între 2,6× 2,6 cm până la 3,5×5 cm, iar lamboul de tip VY este utilizat in cazul defectelor de mici dimensiuni.

EYEBROW RECONSTRUCTION WITH HAIR-BEARING TEMPOROPARIETAL FLAP-CASE REPORT

ROXANA TOTOREAN¹, OANA MIȘCĂ¹, CRISTINA TOMA¹, LAURA VILCU¹, ZORIN CRĂINICEANU¹

¹ Plastic Surgery Department, Casa Austria, “Pius Brinzeu” Emergency County Hospital, Timișoara, România

Introduction:

Reconstruction of soft tissue defects in the facial region is known to be difficult due to the lack of spare local tissue in the immediate vicinity of such defects and because any scar in this region is difficult to hide

Materials and methods:

A 59-year-old male presented with a recurrent tumor just above the right eyebrow. The tumor was excised 4 times in other clinics (with no clear pathological result) and at the time of the presentation consisted of a solid nodule of about 0.5 cm without clear margins and surrounded by scar tissue. A CT and MRI were performed and a wider excision was made. The pathological exam revealed an extrapleural solitary fibrous tumor in the proximity of the resection margins thus needing further re-excision consisting of the entire brow. In order to reconstruct the eyebrow area a hair-bearing temporoparietal flap was chosen and the donor area was closed primarily.

Results:

The uneventful recovery led to a satisfactory oncological and aesthetic outcome.

Discussion:

Management of these cases is complex and challenging and choosing an approach that restores the entire anatomy of the area may be needed in order to obtain the best oncological and aesthetic result.

SURGICALLY ASSISTED RAPID PALATAL EXPANSION- AN OVERVIEW

PRICOP M*, URECHESCU H*, SAMOILA C**

*Disciplina de chirurgie oro-maxilo-facială, UMF “V. Babes” Timisoara

**Cabinet stomatologic Dr. SAMOILA CHRISTIAN

Orthopedic maxillary expansion (OME) was first described over 145 years ago by Angell in a case report. After initially falling to disrepute, it was reintroduced in the middle of the last century by Andrew Haas. Presently, OME has become a routine procedure in treating maxillary transverse deficiency (MTD).

OME can produce unwanted effects when used in a skeletally mature patient, including extrusion, buccal root resorption, fenestration of the buccal cortex, palatal tissue necrosis, pain, and instability of the expansion.

Taking these considerations into account, surgical procedures have been recommended to facilitate correction of transverse discrepancies. These procedures have conventionally been grouped into 2 categories: segmenting the maxilla during a Le Fort osteotomy to reposition the individual segments in a widened transverse dimension, and surgically assisted rapid palatal expansion (SARPE).

Surgically assisted rapid palatal expansion (SARPE) has gradually gained popularity as a treatment option to correct MTD. It allows clinicians to achieve effective maxillary expansion in a skeletally mature patient.

Our aim is to present indications, guidelines for case selection, a brief overview of the surgical techniques, complications, risks, and limitations of SARPE, and last but not least our experience in this technique.

FUTURE DIRECTIONS : SVF AND NANOFAT GRAFTING

FABIANA SIMION¹, GAURAV NARAD¹, VIVIANA NARAD¹, DACIANA GRUJIC

¹ “Pius Brnzeu” Emergency County Hospital - Casa Austria, Plastic Surgery, Timisoara, Romania

Objectives

Stromal vascular fraction (SVF) defines a heterogeneous population of adipose-derived stem cells (ADSCs), growth factors, cytokines and other signaling cells, with tissue regenerative capacity, which resides in fat. Researchers demonstrated fat has a main role in the regenerative medicine field by isolating the SVF and its adipose-derived stem cells (ADSCs). Nanofat grafting represents the method used for preparing and injecting the SVF, being regarded as a cellular therapy and antiaging treatment. SVF cells stimulate angiogenesis, increase capillary density, prevent apoptosis, restore elastin and collagen fibers, and reduce inflammation by modulating the immune response. In this paper, we describe SVF's regenerative potential addressing the structural changes of the skin, noticed both in the aging process and the scarring one, highlighting its therapeutic and aesthetic indications.

Materials

Nanofat grafting was performed in 13 cases for a variety of indications using the sharp needle intradermal fat grafting (SNIF) technique, combined in a few cases with microfat delivered by cannula. Nanofat grafting was used for a full-face rejuvenation (3 cases), hand skin rejuvenation (1 case), dark lower eyelids treatment (4 cases), acne scars (2 cases) and posttraumatic scars (3 cases) improvement. Fat was harvested by liposuction from the lower abdomen after infiltration with a modified Klein solution. The lipoaspirate was mechanically emulsified after saline rinsing. Emulsification of the fat was achieved by shifting the fat between two 10-cc syringes connected to each other by a Luer-Lock connector of 2,4 mm, 1,4mm and 1,2 mm, 30 passes with each of them. After the fragmentation process, the fatty liquid was filtered to remove the connective tissue remnants that would block the fine needles, the final product representing the the SVF isolate, also called “nanofat”. A 27-gauge needle was used for superficial intradermal injection and a cannula for additional subdermal delivering of microfat in selected cases.

Results and discussion

The clinical results were perceived as maximal 6 to 8 months after nanofat grafting: skin brightening and depigmentation, increased elasticity and smoothness, fine wrinkles removal, soft, size-decreased scars, even relief of scar-related pain in our 2 patients with posttraumatic sequelae of the hand. No significant complications were seen, such as infections, fat cysts or granulomas. At the injection sites a temporary erythema or ecchymosis have occasionally been observed but they resolved in 2-5 days. To ensure an effortless SNIF procedure (27-gauge), the fat has to be thoroughly processed to obtain nanofat as a liquid emulsion from the fibrous quasi-solid lipoaspirate. 1 ml of nanofat per 10 ml of lipoaspirate can be expected using the procedure described above. Nanofat has no filling capacity, it is a highly concentrated solution of mesenchymal stem cells and has no viable adipocytes, as seen in lipofilling. The goals pursued are tissue regeneration and remodeling, triggered by SVF cells. The regenerative mechanism by which nanofat works is still not completely understood. Research suggests the mechanical shear stress, imposed on the fat during preparation of nanofat, triggers signaling pathways that determine ADSCs' capacity to differentiate. The results of this complex intercellular “talking” range from enhanced collagen and elastin deposition to formation of new blood

vessels, tissue remodeling, thickening of the dermis, and downregulation of melanogenic activity. Thus, all these bring nanofat grafting into focus for both aesthetic and reconstructive surgery.

Conclusions

The wide availability of adipose tissue easily harvested by minimally invasive liposuction combined with the uncomplicated mechanical process for SVF and ADSCs isolation, brings regenerative medicine into real-life clinical plastic surgery practice. Furthermore, since nanofat grafting is a cellular renewal therapy, it subscribes as a promising start to understand how to alter the aging process in other organs.

Keywords

Nanofat, adipose-derived stem cells, regenerative medicine, antiaging, stromal vascular fraction

References

Tonnard P, Verpaele A, Peeters G, et al. Nanofat grafting: basic research and clinical applications. *Plast Reconstr Surg* 2013;132(4):1017–26.

Bertheuil N, Chaput B, Menard C, et al. Adipose mesenchymal stromal cells: definition, immunomodulatory properties, mechanical isolation and interest for plastic surgery. *Ann Chir Plast Esthet* 2019;64(1): 1–10.

Coleman SR, Katzel EB. Fat grafting for facial filling and regeneration. *Clin Plast Surg*. 2015;42(3):289-300.

James IB, Coleman SR, Rubin JP. Fat, Stem Cells, and Platelet-Rich Plasma. *Clin Plast Surg*. 2016 Jul;43(3):473-88. doi: 10.1016/j.cps.2016.03.017. PMID: 27363761.

Uyulmaz S, Sanchez Macedo N, Rezaeian F, et al. Nanofat grafting for scar treatment and skin quality improvement. *Aesthet Surg J* 2018;38(4):421–8.

Tonnard P, Verpaele A, Carvas M. Fat Grafting for Facial Rejuvenation with Nanofat Grafts. *Clin Plast Surg*. 2020 Jan;47(1):53-62. doi: 10.1016/j.cps.2019.08.006. Epub 2019 Oct 28. PMID: 31739897.

Verpaele A, Tonnard P, Jeganathan C, et al. Nanofat needling: a novel method for uniform delivery of adipose derived stromal vascular fraction into the skin. *Plast Reconstr Surg* 2019;143(4):1062–5.

FUTURE DIRECTIONS : SVF. NANOFAT GRAFTING

FABIANA SIMION^{1,2}, GAURAV NARAD^{1,2}, VIVIANA NARAD^{1,2}, DACIANA GRUJIC^{1,2}

¹ “Pius Brnzeu” Emergency County Hospital - Casa Austria, Plastic Surgery, Timisoara, Romania

²GALIVI Plastic Surgery Clinic, Timisoara

Objective

SVF, acronim pentru fractiunea vasculara stromala, defineste o populatie heterogena formata din celule stem, factori de crestere, citokine si alte celulele de semnalizare, toate cu proprietati de regenerare tisulara, rezidente in tesutul adipos. Nanofat grafting reprezinta metoda de prepare si

injectare a svf-ului, fiind considerata o terapie celulara, antiaging. Celulele izolate in SVF stimuleaza angiogeneza, previne apoptoza celulara, reface fibrele de elastina si collagen, reduce inflamatiile tisulare prin modularea raspunsului imun. Scopul acestei lucrari este de a prezenta potentialul regenerativ al SVF, observand in schimbarile structurale ale pielii din procesele de imbatranire, cicatrizare si patologice, insistand asupra indicatiilor terapeutice cat si estetice.

Materiale si metode

In 13 cazuri s-a optat pentru nanofat grafting prin procedura SNIF - sharp needle intradermal fat grafting (SNIF), iar in unele cazuri s-a optat si pentru microfat injectate cu ajutorul canulei. In 3 cazuri a fost vorba de o rejuvenare full face, in 4 cazuri de tratamentul cearcanelor, in 2 cazuri de cicatrice postacenicice iar in 3 de cicatrice posttraumatice. Grasimea a fost recoltata prin lipoaspiratie din regiunea infraumbilicala a abdomenului, dupa infiltrarea cu solutie Klein. Lipoaspiratul a fost spalat cu solutie salina si emulsificat mecanic, prin pasajul lipoaspiratului prin 3 filtre - 2,4 mm, 1,4mm and 1,2 mm, conectate la seringi de 10 ml, a cate 30 ori pentru fiecare filtru. In final se obtine concentratul SVF, injectat cu ajutorul unor ace 27 gauge la nivel intradermic superficial. In unele cazuri, pentru volumetrie, s-a injectat si microfat cu ajutorul canulei.

Rezultate si discutii

Dupa nanofat grafting, efectele maxime se pot observa la 6-8 luni: depigmentarea pielii, cresterea elasticitatii si tonusului, disparitia ridurilor fine si ameliorarea celor mai accentuate, diminuarea si aplatizarea cicatricilor, disparitia durerii cauzata de procesul cicatricial posttraumatic in cazul mainilor sechelare. Nicio complicatie semnificativa nu a fost observata. Nanofat nu are capacitate de filling, contine o concentratie crescuta de cellule stem mezenchimale si nu contine adipocite viabile, in comparative cu lipoaspiratul utilizat in lipofilling. Efectele urmarite sunt regenerarea si remodelarea tisulara, stimulate de celulele SVF. Mecanismul este inca incomplet elucidat. S-a sugerat ca stresul mecanic din timpul procesului de emulsificare si filtrare, determina multiple cai de semnalizare intercelulara, care determina celulele stem sa se diferentieze. Ca si rezultate ale acestei "conversatii" intercelulare se inscriu: cresterea fibrelor de collagen si elastina, formarea de noi vase de sange, remodelarea tesutului cicatricial, ingrosarea dermului, echilibrarea activitatii melanocitare. Prin urmare, nanofat grafting isi gaseste aplicabilitate atat in afectiuni dermatologice, nevoi de natura estetica cat si cazuri de chirurgie reconstructiva.

Concluzii

Disponibilitatea generoasa a tesutului adipos, recoltarea sa printr-o maniera minima invaziva de lipoaspiratie, completata de un proces mecanic de emulsificare pentru obtinerea nanofat si implicit a SVF si a celulelor stem, subscrie nanofat graftingul in cadrul terapiilor celulare de medicina regenerativa, fiind un bun inceput pentru alterarea procesului de imbatranire la nivelul tuturor organelor.

Bibliografie

Tonnard P, Verpaele A, Peeters G, et al. Nanofat grafting: basic research and clinical applications. *Plast Reconstr Surg* 2013;132(4):1017–26.

Bertheuil N, Chaput B, Menard C, et al. Adipose mesenchymal stromal cells: definition, immunomodulatory properties, mechanical isolation and interest for plastic surgery. *Ann Chir Plast Esthet* 2019;64(1): 1–10.

Coleman SR, Katzel EB. Fat grafting for facial filling and regeneration. Clin Plast Surg. 2015;42(3):289-300.

James IB, Coleman SR, Rubin JP. Fat, Stem Cells, and Platelet-Rich Plasma. Clin Plast Surg. 2016 Jul;43(3):473-88. doi: 10.1016/j.cps.2016.03.017. PMID: 27363761.

Uyulmaz S, Sanchez Macedo N, Rezaeian F, et al. Nanofat grafting for scar treatment and skin quality improvement. Aesthet Surg J 2018;38(4):421–8.

Tonnard P, Verpaele A, Carvas M. Fat Grafting for Facial Rejuvenation with Nanofat Grafts. Clin Plast Surg. 2020 Jan;47(1):53-62. doi: 10.1016/j.cps.2019.08.006. Epub 2019 Oct 28. PMID: 31739897.

Verpaele A, Tonnard P, Jeganathan C, et al. Nanofat needling: a novel method for uniform delivery of adipose derived stromal vascular fraction into the skin. Plast Reconstr Surg 2019;143(4):1062–5.

CORRECTIVE SURGICAL MODALITIES IN EYELID PATHOLOGY. TECHNICAL CHALLENGES AND COMPARATIVE RESULTS WITH PRACTICAL RECOMMENDATIONS

**DR DANA-PETRONIA ULITA, DR. WAEL EL AMINE, DR CRISTIAN DUMITRASIUC,
DR. GHEORGHE NODITI**

**SPITALUL CLINIC JUDETEAN DE URGENTA " PIUS BRNZEU" CLINICA DE CHIRURGIE
PLASTICA CASA AUSTRIA, TIMISOARA, ROMANIA**

The periorbital region is a complex anatomical region of the face with various functional and aesthetic implications. We know that in addition to the aesthetic functions they perform, the eyelids protect the anatomical structures of the eye; and the Meibomian glands produce a number of substances, specifically lipids that stabilize the tear film to prevent the cornea from drying out. But for this, the eyelids must be intact and functional. In reconstructive surgery of the periorbital area, the plastic surgeon faces a series of technical challenges ranging from anatomical, aesthetic to morpho-functional and mechanical implications. Eyelid reconstruction requires professionalism, perspective, imagination, vision, surgical passion, the art of modeling as a good creator, perfection and an eye for detail. Under the impetus of these challenges, we approached every case addressed in our Clinic, with the desire to be perfect in the art of shaping this complex region with important clinical meanings and implications, always reminding us that with every blink comes meaning. We present below some of the clinical cases we have faced and the adjacent surgical challenges, which have allowed us, to reflect on what the Dutch painter Vincent van Gogh said: "there is nothing truly more artistic than loving the people".

Keywords: periorbital region, eyelid reconstructive surgery, surgical challenges, morpho-functional and mechanical implications.

MALIGNANT CUTANEOUS MELANOMA - " DISEASE OF MEPHISTO" (GOETHE-NIAN) - BACKSTAGE DATA FROM OUR CLINIC-

**DR. DANA-PETRONIA ULITA, DR. WAEL EL AMINE, DR. CRISTIAN
DUMITRASIUC, DR. GHEORGHE NODITI**

SPITALUL CLINIC JUDETEAN DE URGENTA " PIUS BRNZEU" CLINICA DE CHIRURGIE
PLASTICA CASA AUSTRIA, TIMISOARA, ROMANIA

In the last 10 years, the incidence of skin melanoma has been increasing, according to clinical data from various Medical Centers and according to World Health Organization statistics. The concern is that malignant melanoma is responsible for most skin cancer deaths. Malignant cutaneous melanoma is the malignancy of melanocytes in the skin. The study of the immune response, including tissue and circulating immune markers that may correlate with the evolutionary stages of melanoma, could lead to the development of new diagnostic, prognostic and therapeutic strategies to reduce melanoma morbidity and mortality. Questions such as: Does it influence the anato-pathological type of cutaneous melanoma, its evolution and treatment? or Why do some types of melanoma produce predominantly lymphatic invasion, and in other cases - hematogenous dissemination, predominantly brain metastases? Does insidious dissemination or recurrences depend on the patient's immune response and biological status? These are some of the questions we have faced with the story of "cell to scalpel" malignancy. In this presentation we have tried to answer these questions and cover some of the clinical cases we have faced, following the metamorphosis of melanoma: "a monster more insatiable than the guillotine" (Dr. Siddhartha Mukherjee)

Keywords: cutaneous melanoma, melanoma mortality, invasion, the recurrences, the therapeutic strategies

"SELF-IDENTITY" SURGERY. PSYCHOLOGICAL IMPLICATIONS IN FACIAL AESTHETICS

ICA SECOȘAN, ZORIN CRĂINICEANU

Department of Psychology, West University of Timisoara, 325100 Timisoara, Romania
Faculty of Medicine, "Victor Babes" University of Medicine and Pharmacy, 300041 Timisoara,
Romania

Introducere

Fețele umane reprezintă liantul care ne ține împreună și care ne dă identitatea. Fața pe care o privim în oglindă, este rezultatul a milioane de ani de evoluție și reflectă cele mai distincte trăsături pe care le folosim pentru a ne identifica și recunoaște.

Scopul lucrării

In cazul unei traume sau defect la nivelul feței, identitatea de sine are de suferit. Cunoașterea implicațiilor psihologice ale acestor situații este un deziderat.

Material si Metode

Studierea literaturii de specialitate în domeniu, indică faptul că parametrii psihologici esențiali, precum nivelul de anxietate, depresie, PTSD, tulburările de somn și de percepție asupra corporalității, pot fi diminuați prin intervențiile chirurgicale de specialitate.

Rezultate

Numeroase studii de specialitate indică o ameliorare semnificativă a nivelurilor de stres psihic, de la anxietate, până la reducerea ideății suicidare, în rândul pacienților care au suferit traume la nivelul feței și care au apelat la intervențiile de estetică facială și reconstructivă. O categorie aparte de pacienți, afectați de dismorfofobie, reprezintă o provocare atât pentru screeningul corect, cât și pentru alegerea celei mai potrivite și personalizate intervenții terapeutice.

Concluzii

Rolul chirurgiei estetice în ameliorarea dispoziției afective și influențarea calității vieții pacientului care apelează la intervențiile de estetică facială sau reconstructivă, este esențial. Prin aceste metode moderne, pacienții își pot remodela identitatea de sine, pot preveni complicații psihologice pe termen lung și spera în final la o viață normală atât din punct vedere personal, cât și social sau profesional.

Cuvinte cheie

Chirurgie facială, identitate de sine, dismorfofobie, chirurgie reconstructivă, anxietate, depresie, calitatea vieții

Introduction

Faces are the glue that holds us together and that gives us our identity. The faces we are looking at in the mirror are the result of millions of years of evolution and reflect the most distinctive features that we use to identify and recognize each other.

Objectives

In the case of facial trauma, our self-identity suffers. Understanding the psychological implications of these situations is desirable.

Material and Methods

The studies in this area pointed out that the levels of anxiety, depression, PTSD, sleep and body perception disorders can be reduced through specialized surgical interventions.

Results

As past studies have already shown, there are significant improvements in the levels of mental distress, from anxiety, to the reduction of suicidal ideation, among patients who have suffered facial trauma and who resorted to facial aesthetics and reconstructive interventions. A special category of patients affected by dysmorphophobia represents a challenge both for screening purposes, as well as for choosing the most appropriate and personalized therapeutic intervention.

Conclusions

The role of facial aesthetics in improving the self-reported psychological well-being and patient's quality of life, is essential. Through these modern methods, patients can reshape their self-identity, prevent long-term psychological problems and finally hope for a normal life, from a personal point of view as well as socially and professionally.

Keywords

Facial aesthetics, self-identity, dysmorphophobia, reconstructive surgery, anxiety, depression, quality of life

LIFTING THE BROW, HOW TO KEEP IT SIMPLE AND EFFICIENT

BY DR.RAUL CHIOIBAS

Gradually, over the past years, from my critical point of view, the results of many former techniques done at that moment were sometimes less than natural and short lasting in terms of natural and full rejuvenation of the eyebrow .

I realized that the differences between a good and a poor result were not in the surgical technique itself, but more often in the choice made to aesthetically improve certain areas of the face. A poor recommendation even if the technique is performed perfectly can lead to dissatisfied patients

This paper was meant to explain different aesthetic units of the face that can be pointed on and can enhance the beauty of the face when treating a patient in the eye region. Beauty is, no doubt, a whole but this whole is made of single units that must be harmonic and balanced with each other.

Before programming any rejuvenation strategy be it surgical or nonsurgical we must consider the symmetry of certain areas.

Upper Blepharoplasty is one of the aesthetic surgeries that can improve tremendously the facial aspect but if in the past it was considered as a single standing procedure itself, the evolution of aesthetic surgery nowadays recommends a more complex treatment of the eye region where blepharoplastie should be a part of the treatment plan. The excess skin is almost allways a bicomponent problem: pseudo excess skin due to laxity and brow ptosis.

The upper blepharoplastie is to be done together with a brow lift that can be performed either surgically or simply by using Botox injections. Also the brow egg should be enhanced by injecting ADRCs improved fat.

This presentation will give a brief overview on the techniques that we have on hand for brow lifting emphasizing the key elements in terms of surgical planning and assessment.

TIPS AND TRICKS TO STAY AWAY FROM TROUBLE IN INFERIOR EYELID SURGERY

BY DR RAUL CHIOIBAS

In the lower eyelid region the simply excess skin removal is no longer a choice of treatment for this region. The best results can be obtained when considering to treat the cause and not only the effect . The herniated fat can be treated in the same time with the lower blepharoplasty and has to be treated conservatively. The less we remove and the more we redistribute, the better the result. The fat has to be transformed in flaps and redraped over the tear trough area or the V shaped area can be fat grafted.

When treating the lower lid the cheek area is also to be considered. There are various techniques to enhance this area one of the most reliable techniques being the Midface Lift or, if a less invasive procedure is to be chosen, the Silhouette Lift Technique. This way I am able to resuspend the whole cheek area improving also this way the lower eye region.

There is no lower eyelid procedure that I perform without ensuring the stability of the lid with a orbicularis oculii Rady Adamson flap. This is how we can reduce the risk of sclera show or ectropion formation especially in patient where we have positive snap test.

In conclusion I would say that eyelid surgery should no longer be performed as a standing alone procedure and should be considered as a part in a whole to get the best results we can provide to our patients.

ROLUL SEPTOPLASTIEI IN CADRUL RINOPLASTIEI

DR. N. C. BALICA, DR. I. C. MOT, DR. D. I. HORHAT

Clinica ORL Timisoara, Universitatea de Medicina si Farmacie “Victor Babes” din Timisoara

Septoplastia nazală este una dintre cele mai frecvent efectuate proceduri în cadrul otorinolaringologiei (ORL) și chirurgiei plastice. Indicația principală pentru această intervenție chirurgicală funcțională (spre deosebire de cea pur estetică) este, de obicei, deviația septală care determina obstrucția semnificativă și simptomatică a căilor respiratorii nazale. Au fost descrise multe tehnici și abordări chirurgicale; acestea includ proceduri endonasale, endoscopice și tehnici deschise. Septoplastia poate fi, de asemenea, efectuată alături sau în plus față de rinoplastie, turbinoplastie sau ca parte a chirurgiei funcționale endoscopice a sinusurilor pentru a îmbunătăți expunerea chirurgicală și accesul. Recuperarea este de obicei de câteva săptămâni, iar complicațiile grave sunt rare. Selecția adecvată a pacienților este crucială pentru maximizarea rezultatelor pacienților.

THE ROLE OF SEPTOPLASTY WITHIN RHINOPLASTY

DR. N. C. BALICA, DR. I. C. MOT, DR. D. I. HORHAT

ENT Department Timisoara, “Victor Babes” University of Medicine and Pharmacy Timisoara

Nasal septoplasty is one of the most commonly performed procedures within otorhinolaryngology (ENT) and plastic surgery. The primary indication for this functional (as opposed to purely aesthetic) surgery is usually septal deviation resulting in significant and symptomatic nasal airway obstruction. Many surgical techniques and approaches have been described; these include endonasal, endoscopic and open procedures. Septoplasty can also be performed alongside or in addition to rhinoplasty, turbino-plasty, or as part of functional endoscopic sinus surgery to improve surgical exposure and access. Operative recovery is usually a few weeks, and serious complications are rare. Appropriate patient selection is crucial to maximizing patient outcomes.

THE KEY ROLE OF FUNCTIONAL ENDOSCOPIC SINUS SURGERY (FESS) IN THE MANAGEMENT OF RHINOSINUSITIS

ION CRISTIAN MOT, DELIA HORHAT, MĂRIOARA POENARU, EUGEN RADU BOIA, KRISTINE GURAN, ALINA TISCHER, RĂZVAN ZIMBRU, NICOLAE CONSTANTIN BALICA

Functional endoscopic sinus surgery (FESS) is a minimally invasive technique in which sinus air cells and sinus ostia are opened under direct visualization. The goal of this procedure is to restore sinus ventilation and to return the mucociliary drainage of the sinuses to normal function.

Functional endoscopic sinus surgery is most commonly performed for inflammatory and infectious sinus disease. The most common indications for endoscopic sinus surgery are as follows: chronic sinusitis refractory to medical treatment; recurrent sinusitis; nasal polyposis; sinus mucoceles; excision of selected tumors.

Typically, FESS is reserved for patients with documented rhinosinusitis, based on a thorough history and a complete physical examination, including CT scans if appropriate, and in whom appropriate medical treatment has failed.

The result is a highly selected group of patients who can expect an improvement of up to 90 percent in their symptoms. Patients in whom the predominant symptoms are facial pain and nasal blockage usually respond very well. The sense of smell often improves after this type of surgery.

The blend between clinical diagnostics, imagery techniques and surgical treatment helped in evaluation of the multitude of cases that we had, from which we selected some clinical relevant ones where the patients undergone functional endoscopic sinus surgery in order to cure their sinusitis.

Key words: Functional endoscopic sinus surgery; rhinosinusitis; clinical aspects; sinusitis imaging.

UNRAVELING THE FUNCTIONAL ENDOSCOPIC SINUS SURGERY'S SIGNIFICANCE IN SINONASAL TUMORS

DELIA HORHAT, ION CRISTIAN MOT, MĂRIOARA POENARU, EUGEN RADU BOIA, KRISTINE GURAN, ALINA TISCHER, RĂZVAN ZIMBRU, NICOLAE CONSTANTIN BALICA

Although the sinonasal cavities occupy a relatively small anatomical space, they are the site of origin of one of the most histologically diverse group of tumours observed in the human body. The sinonasal region is a complex anatomical area, close to structures that include the eyes and the brain, which is of special relevance to surgery and postoperative treatment, as mutilation and aesthetic deformities are difficult to avoid.

Even though the epithelial tumours (mainly squamous cell carcinomas) are the predominant form of malignancy affecting the sinonasal cavities, representing >80% of all sinonasal tumours, there are a variety of types in nasal cavity and paranasal sinus cancers such as adenocarcinomas, adenoid cystic carcinomas, mucoepidermoid cancers, undifferentiated carcinoma, melanoma, esthesioneuroblastoma, lymphomas and sarcomas. On the other hand, there are the benign tumors that require endoscopic surgical treatment such as nasal polyposis, papillomas and inverted papilloma.

Indeed, the aetiology, epidemiology, clinical features, and genetic profile of sinonasal tumours are distinct from those of the main head and neck cancer localizations, such as larynx, pharynx, and oral cavity cancers.

Therefore, the functional endoscopic sinus surgery plays a key role in managing tumors located in the nasal cavity and paranasal sinuses. There are also some other indications for endoscopic sinus surgery that can also lead to uncovering intraoperative these tumors are: chronic and recurrent sinusitis refractory to medical treatment; nasal polyposis; sinus mucoceles.

Our perspectives on this subject rely on our vast clinical experience with numerous benign and malign nasal and sinus tumor cases that have been evaluated in the ENT Clinic of Timisoara. In this matter of fact, there are some clinical cases revealed in this paper and their morphological and paraclinical particularities.

As a conclusion, we can highlight the fact that the clinical management of sinonasal tumors has improved greatly owing to developments in functional endoscopic sinus surgery and precision radiotherapy.

Key words: Functional endoscopic sinus surgery; nasosinusal tumors; intraoperative aspects.

DOG EARS? NO PROBLEM

PATRICIA CRISTODOR(1), IASMINA-MARIA HÂNCU (2), VALENTIN TUDOR POPA (1), LAURENȚIU ILINCA (3), IUSTIN HÂNCU (4)

- (1) Universitatea de Medicină și Farmacie „Victor Babeș” Timișoara
- (2) Spitalul Clinic Județean Timișoara
- (3) Spitalul Clinic Municipal Timișoara
- (4) Spitalul Clinic de Urgență București

Urechile de câine, triunghiuri Burrow, răcușor, sutura aplatizantă

Introducere: „Urechile de câine” sunt eminente mamilonate care se formează în extremitățile exciziilor fusiforme în care raportul lungime/lățime e sub 2,5:1 sau în zona de origine a lambourilor de rotație. De regulă, acest defect estetic se remediază printr-o mică excizie triunghiulară suplimentară angulată față de linia de incizie inițială – așa numitele “triunghiuri Burow”.

Scopul lucrării: Punerea la punct a unei metode mai estetice de reparare a urechilor de câine

Material și metode: Vor fi prezentate două tehnici personale. Prima tehnică propusă vizează folosirea unui răcușor pentru a poziționa excizia triunghiului Burow în axul inciziei inițiale, cu beneficiul obținerii unei cicatrice mai estetice (liniară în loc de angulată). A doua tehnică vizează aplatizarea urechilor de câine printr-o metodă personală de sutură, care va fi demonstrată în detaliu pe documentația fotografică.

Rezultate: Cu prima metodă, am obținut o cicatrice operatorie liniară, fără angulări, comparativ cu cea a triunghiurilor Burow; a doua tehnică se soldează tot cu o cicatrice liniară, dar mai scurtă decât a exciziilor obișnuite (nerespectând raportul lungime/lățime)

Concluzii: Cele două metode prezentate pot intra în arsenalul metodologic și pot îmbunătăți practica chirurgicală.

INCREDIBIL, DAR ADEVARAT - UN TRATAMENT DERMATOLOGIC PENTRU PATOLOGIA LOMBARA

PATRICIA CRISTODOR (1), IASMINA HANCU (2), LAURENȚIU ILINCA (3), IUSTIN HANCU (4)

- (1) UMF Timișoara
- (2) Spitalul Clinic Județean Timișoara
- (3) Spitalul Clinic Municipal Timișoara
- (4) Spitalul Clinic de Urgență București

Introducere: Grăsimea cutanată a devenit un subiect major de interes și cercetare de când s-a dovedit potențialul său de sursă de celule stem.

Scopul lucrării: Ne-am propus să cercetăm dacă injectarea de grăsime îmbogățită în celule stem are vreun efect asupra patologiei dureroase din discopatia lombară și care ar fi acesta.

Material și metode: La 3 pacienți (AC M, 79 ani, AF, F, 75 ani și HI, M, 59 ani) suferind de o discopatie lombară dureroasă, generatoare de impotență funcțională, am recoltat grăsime din zona abdominală inferioară, pe care am supus-o procedurilor standard de îmbogățire în celule stem, apoi am injectat 10 ml din aceasta în zona paravertebrală dureroasă, după procedura știută a infiltrațiilor paravertebrale.

Rezultate: Toți pacienții au avut o îmbunătățire aproape instantanee a durerii, care a ajuns la un maxim la 6-7 zile, acompaniată de o surprinzătoare redobândire a mobilității.

Concluzii: Deși eșantionul nu este statistic semnificativ, răspunsul unanim favorabil al pacienților ar trebui să constituie un argument pentru aprofundarea cercetărilor în această direcție.

ESTHETIC ASPECTS IN INTERDISCIPLINARY ORTHODONTICS

PROF. DR. CAMELIA SZUHANEK

Orthodontics Discipline, 2nd Department, Faculty of Dental Medicine, “Victor Babes” University of Medicine and Pharmacy

Orthodontic Research Center, OrthoCenter, “Victor Babes” University of Medicine and Pharmacy

The interdisciplinary approach is the key element in establishing a successful clinical treatment plan in craniofacial anomalies. One of the main reasons in recommending orthodontic/orthognatic treatment is the symmetry and esthetics of the face and smile. Recent developments in digital techniques has allowed the clinical team to digitally establish the treatment plan and to simulate the clinical results. The contribution of digital methods allows the interdisciplinary team to precisely anticipate the treatment outcome, while providing our patients a stable and esthetic occlusion. The purpose of this presentation is to describe the digital methods used in interdisciplinary orthodontic treatment, that are mostly indicated in adult orthodontic cases, while emphasizing that 3D imaging, diagnosis and virtual planning allow an effective prediction of the orthodontic – orthognatic treatment result.

THE COMBINED APPROACH OF NON-SURGICAL AND SURGICAL TECHNIQUES IN FACIAL AESTHETICS : WHEN, WHERE AND HOW

DR LJUBISA GRUJIC, DR DACIANA GRUJIC

Dr Grujic Aesthetics, Vrsac, Serbia

Universitatea de Medicina si Farmacie „Victor Babes „Timisoara

In recent years, cosmetic anti-aging procedures have gained mainstream acceptance. And while many women start with less invasive treatments, like injections and dermal fillers, at a certain point, some women consider facial rejuvenation surgery, or a face-lift, for longer-lasting and more dramatic results.

We cannot talk about a single technique for obtaining a beautiful face. The question is when non-surgical procedures are indicated, if there is an age for surgical lifting, which areas are most affected

and difficult to treat due to facial dynamics, the timing and how to combine surgical and non-surgical techniques to obtain a more natural and beautiful appearance of the face.

The work presents our last 5 years of experience and the personal approach to facial rejuvenation using non-invasive techniques associated with invasive techniques.